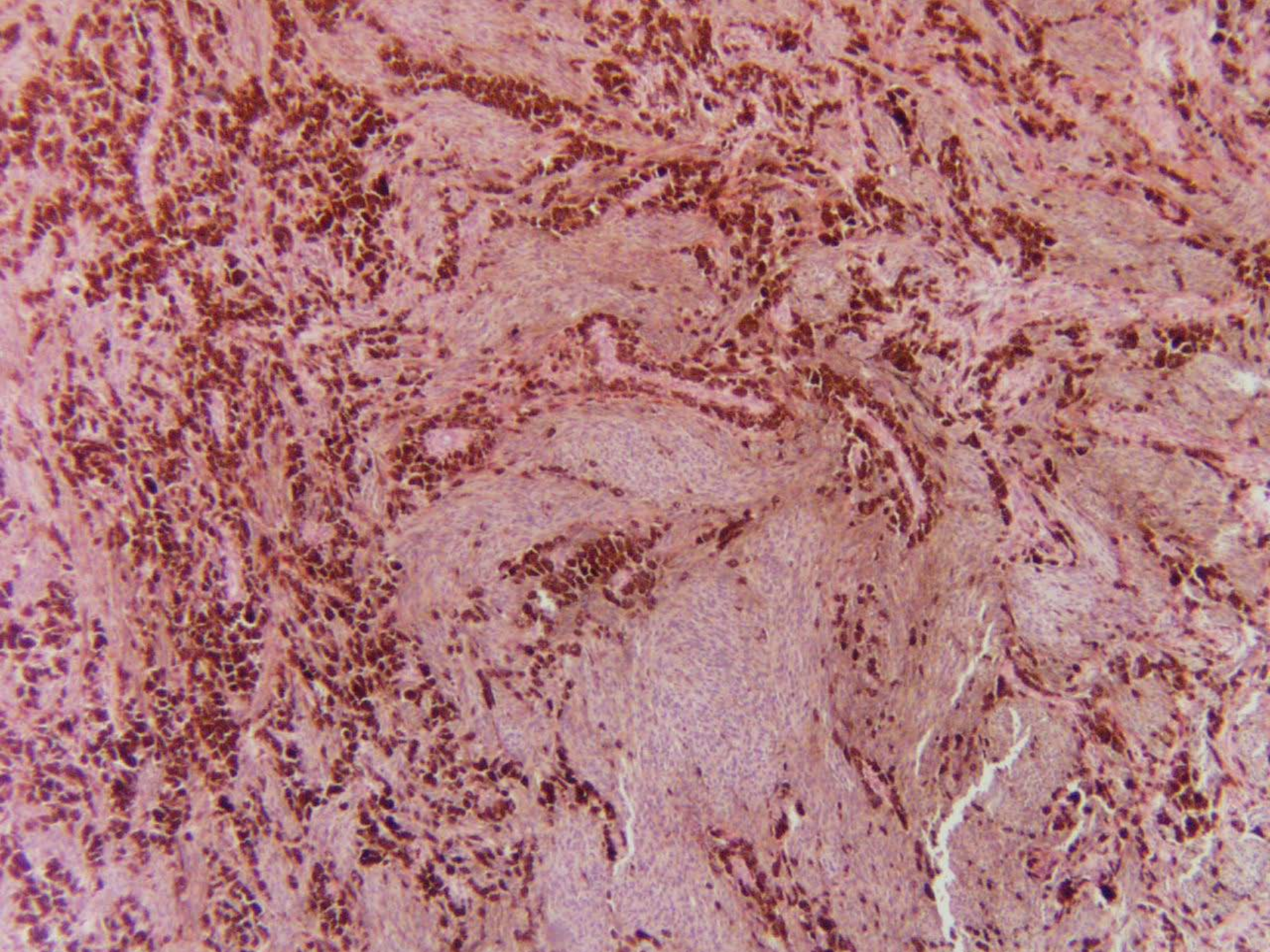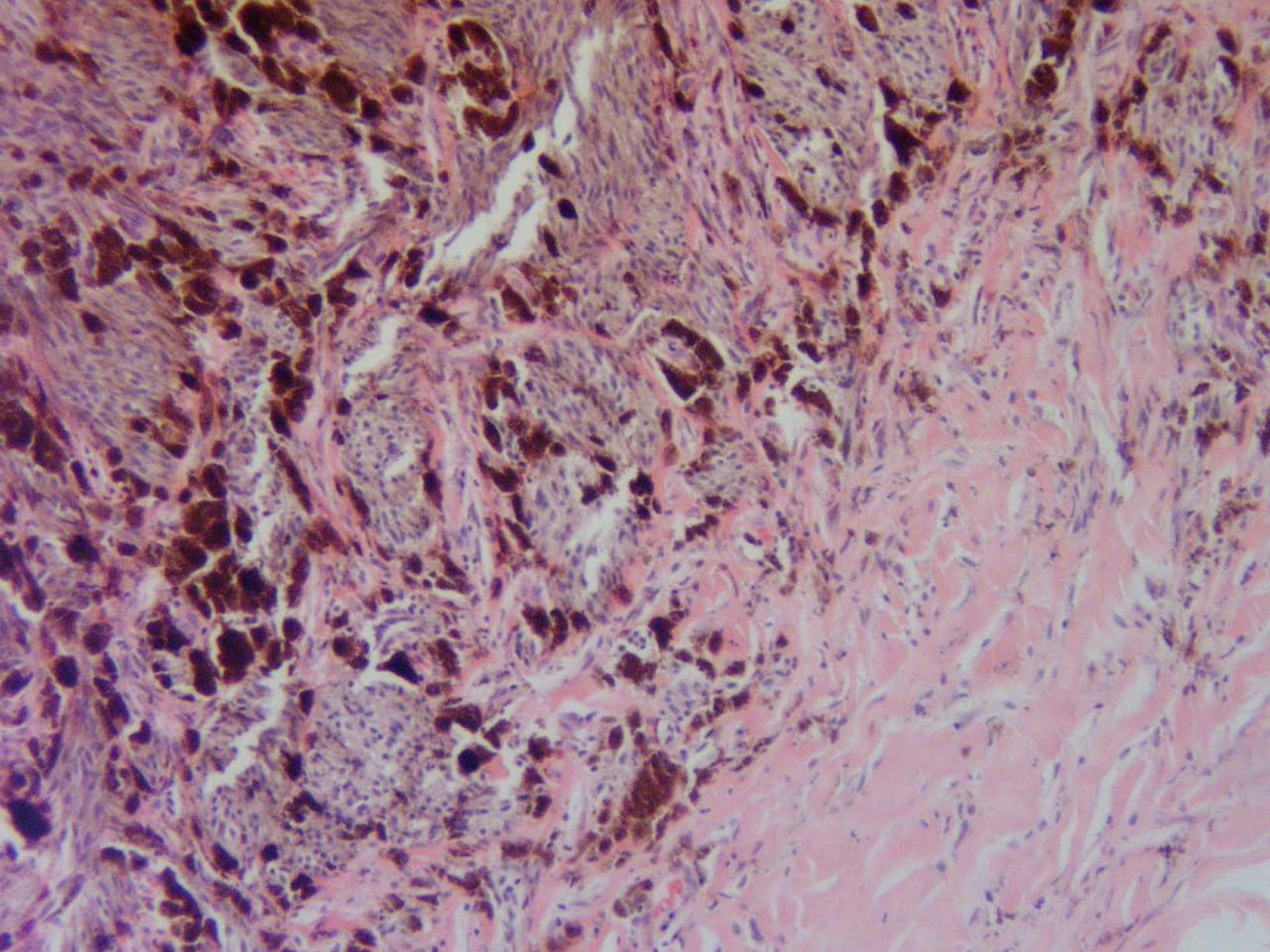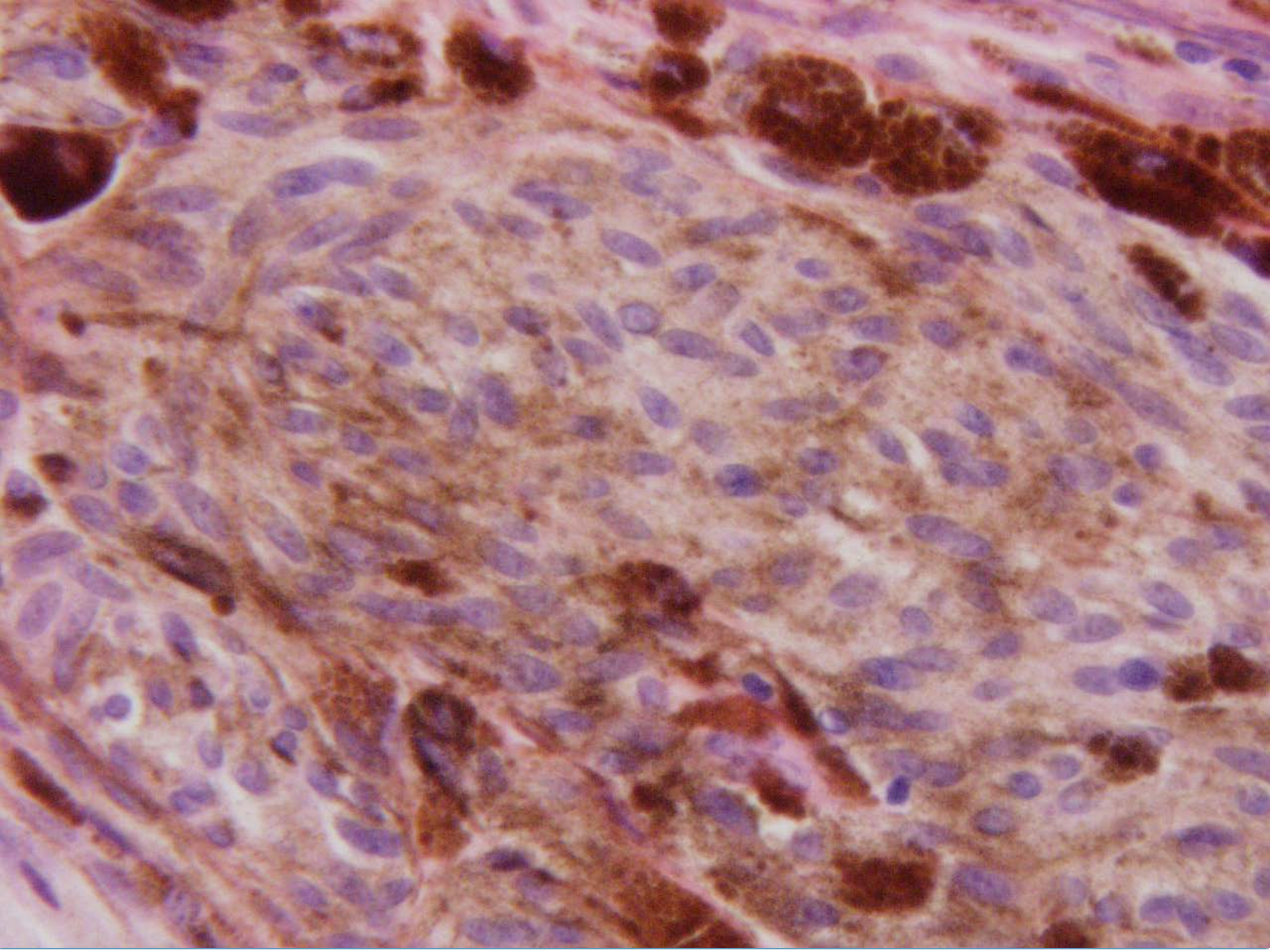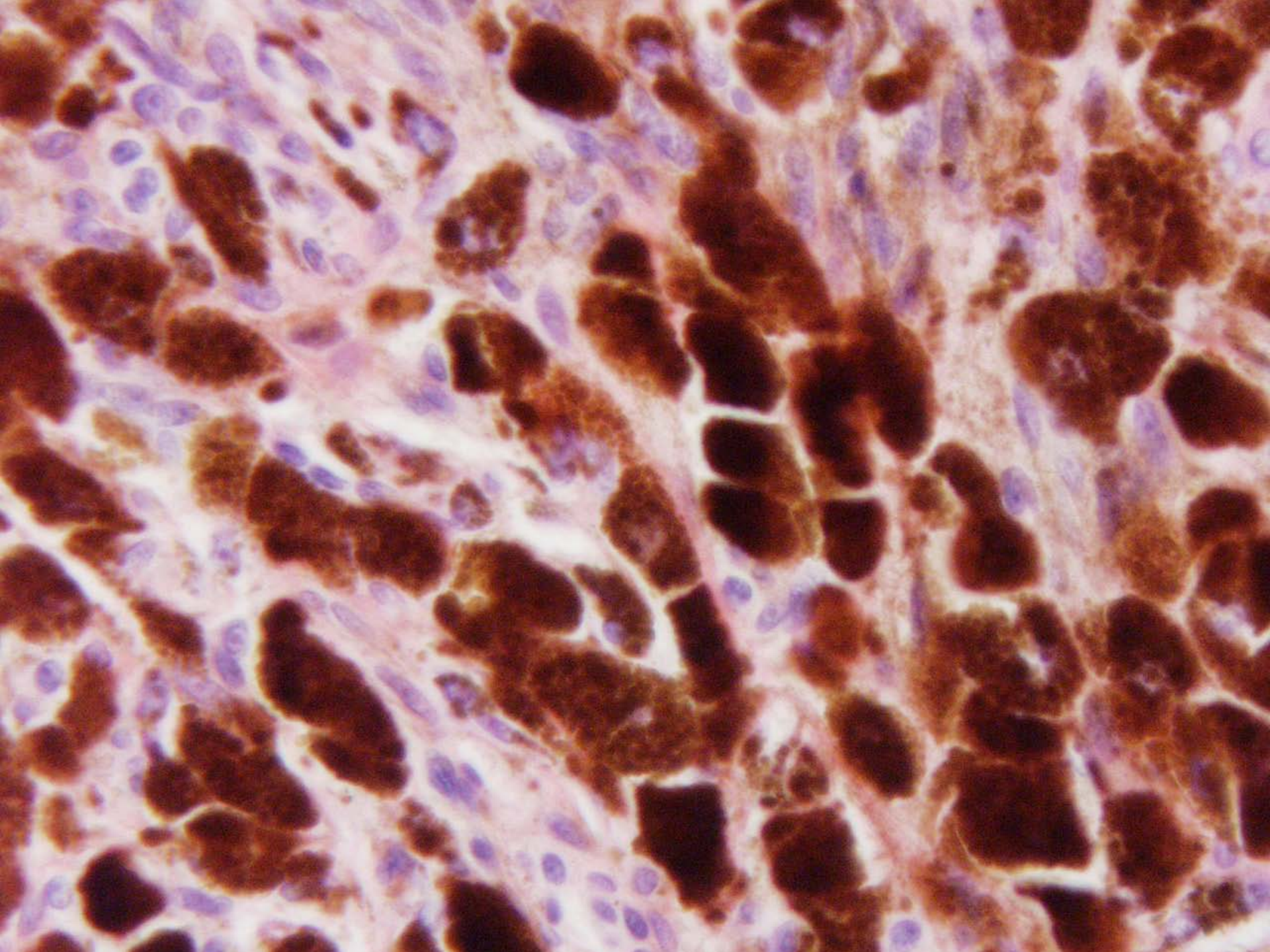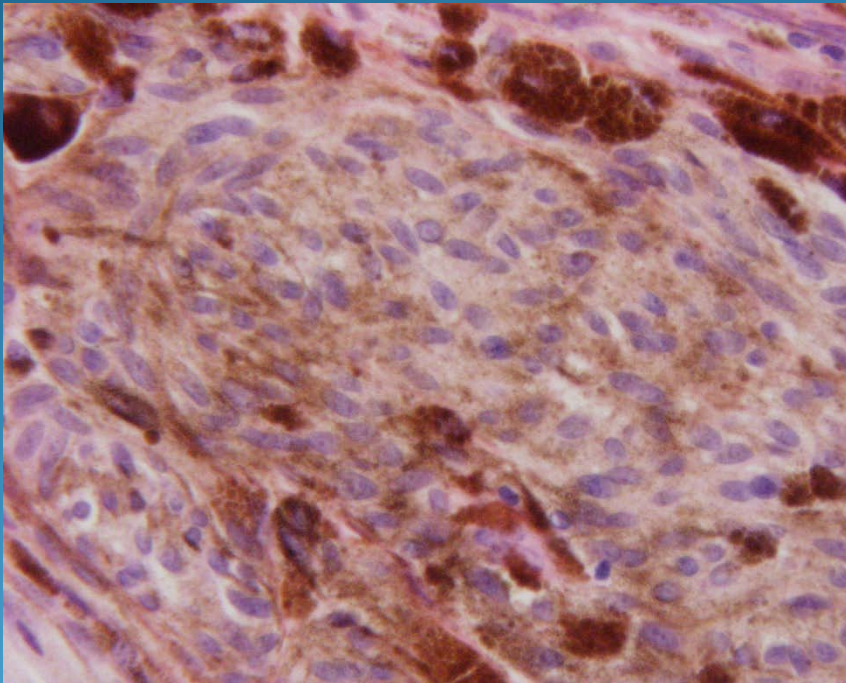


Cellular Blue Nevus

Pearls



- Darkly pigmented and cellular tumor
- Look for fascicles of melanocytes
- Pigmented spindle cells on periphery
- Should not see mitotic figures