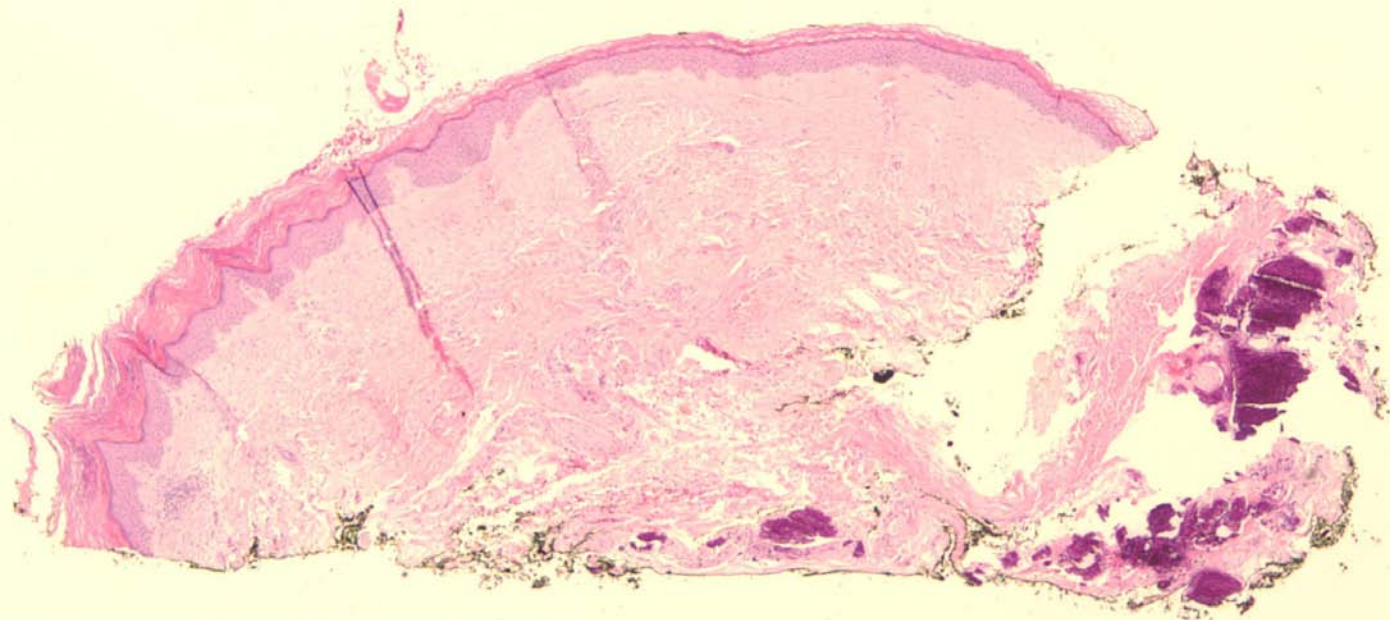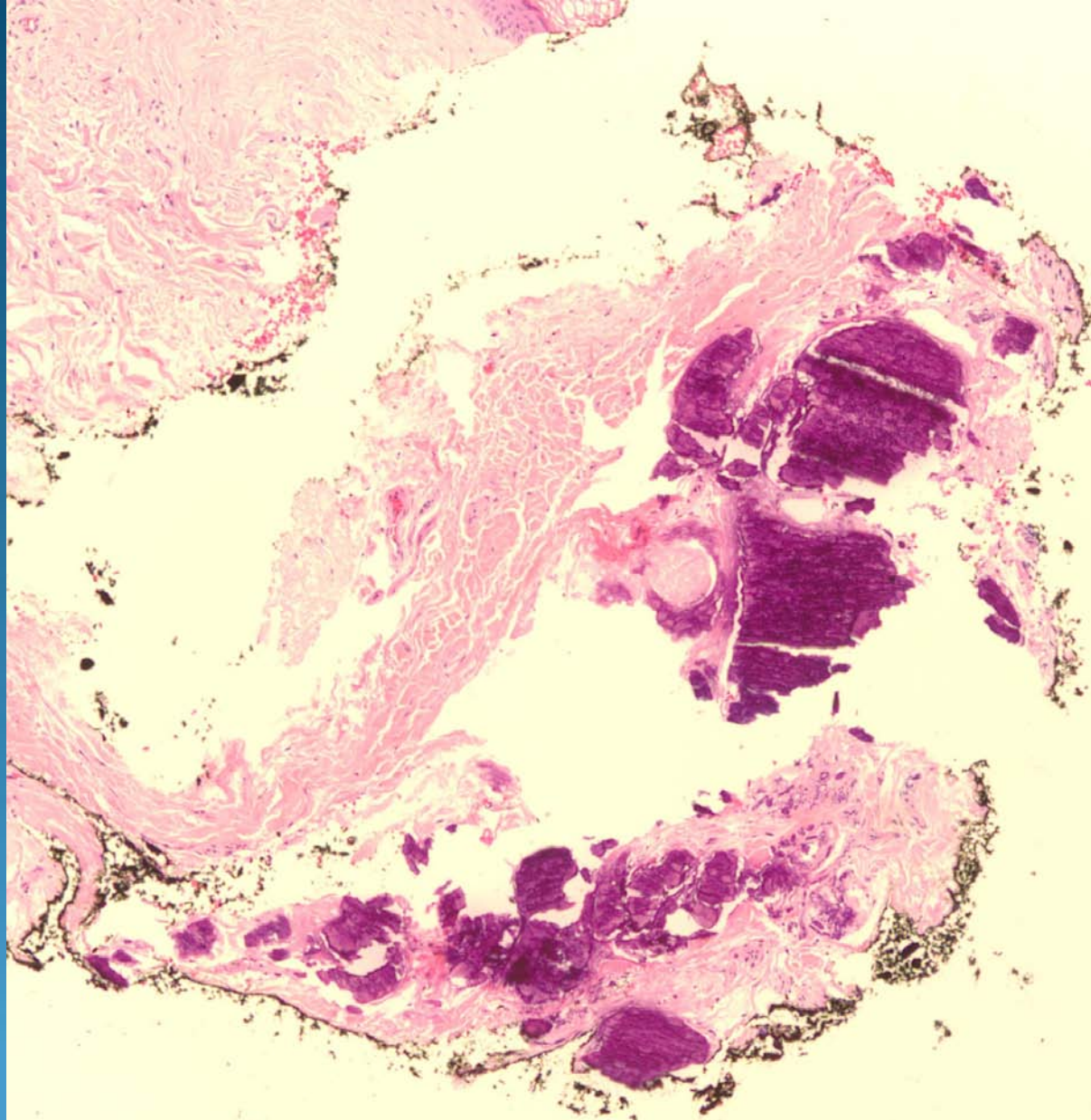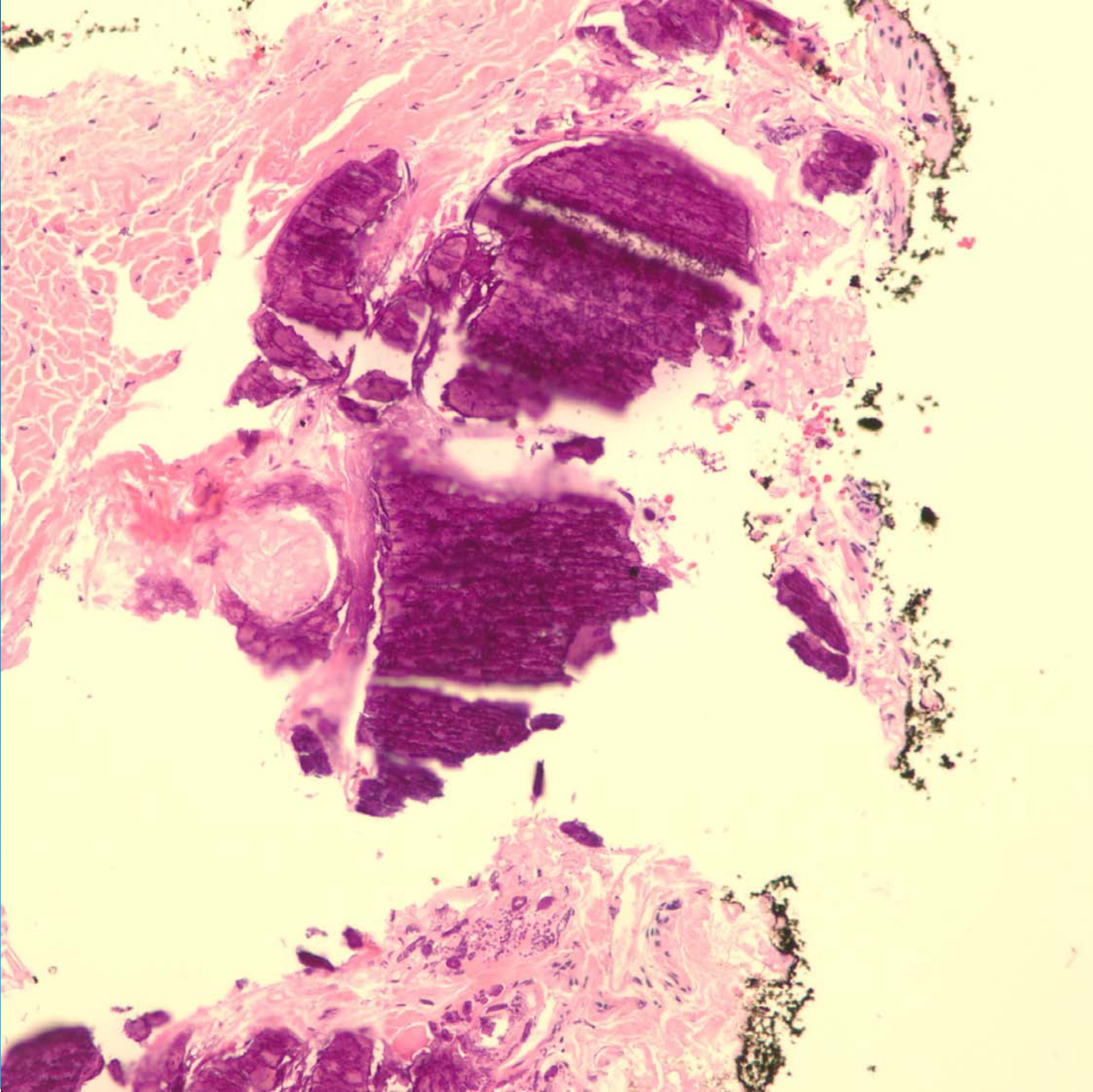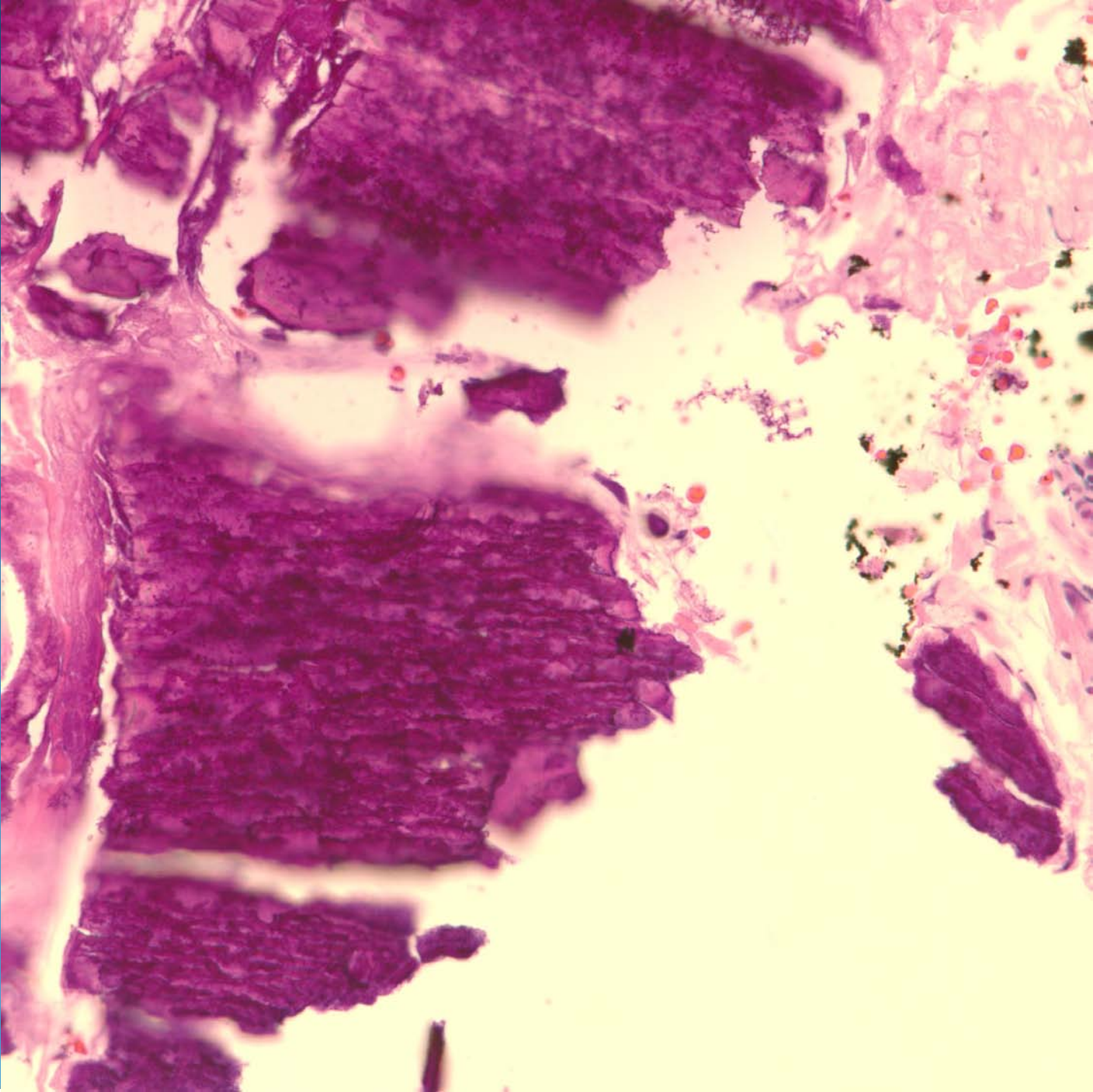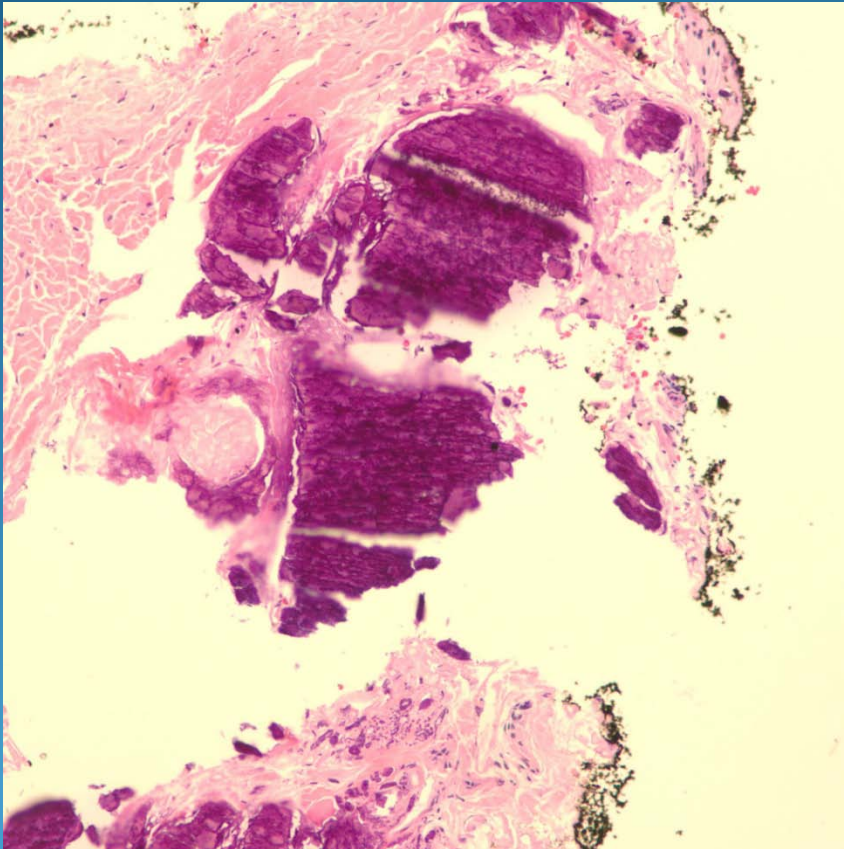


Calcinosis Cutis

Pearls



- Amorphous blue collections of calcium in dermis
- May cause “knife chatter” and shatter with tissue sections