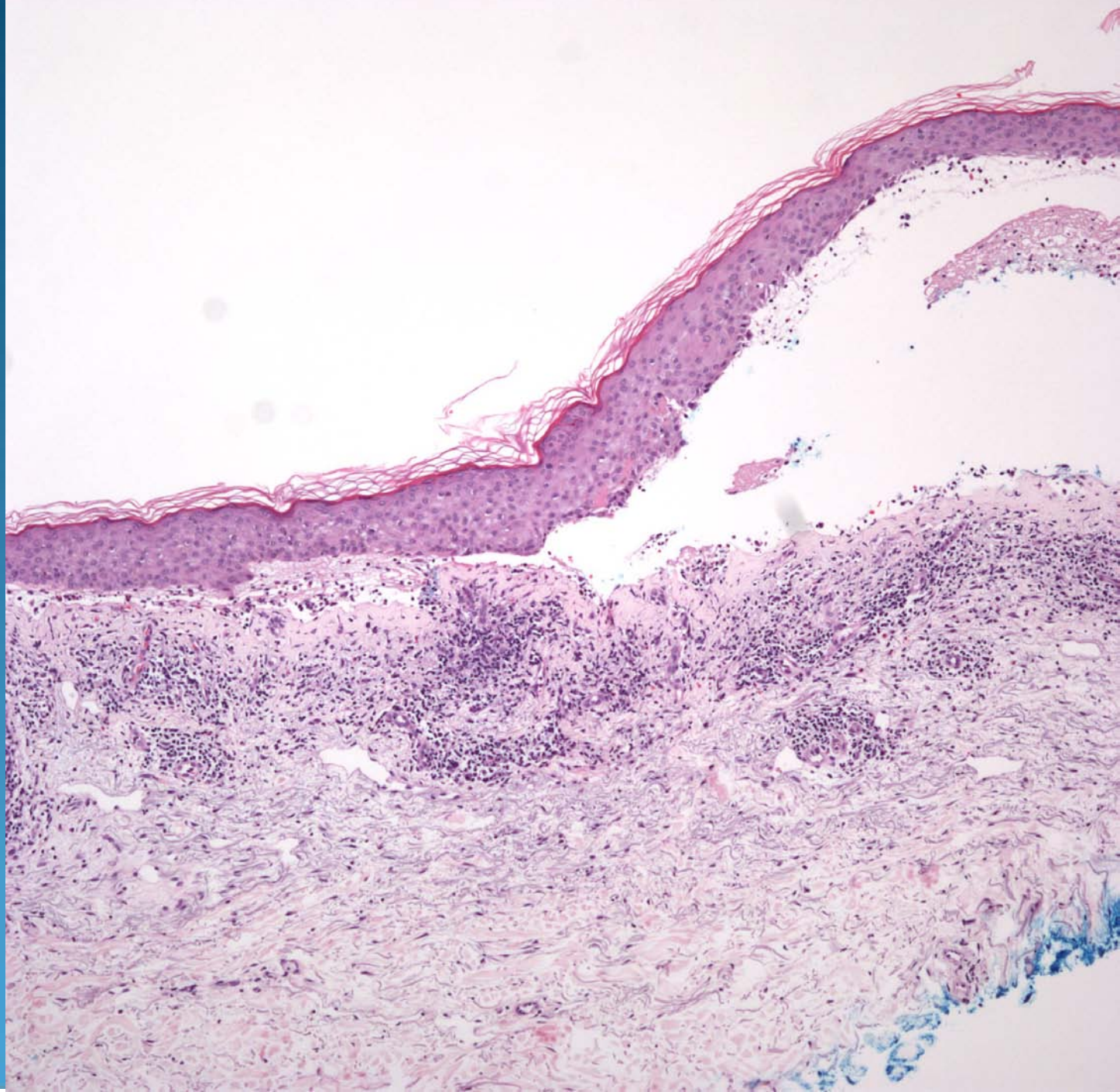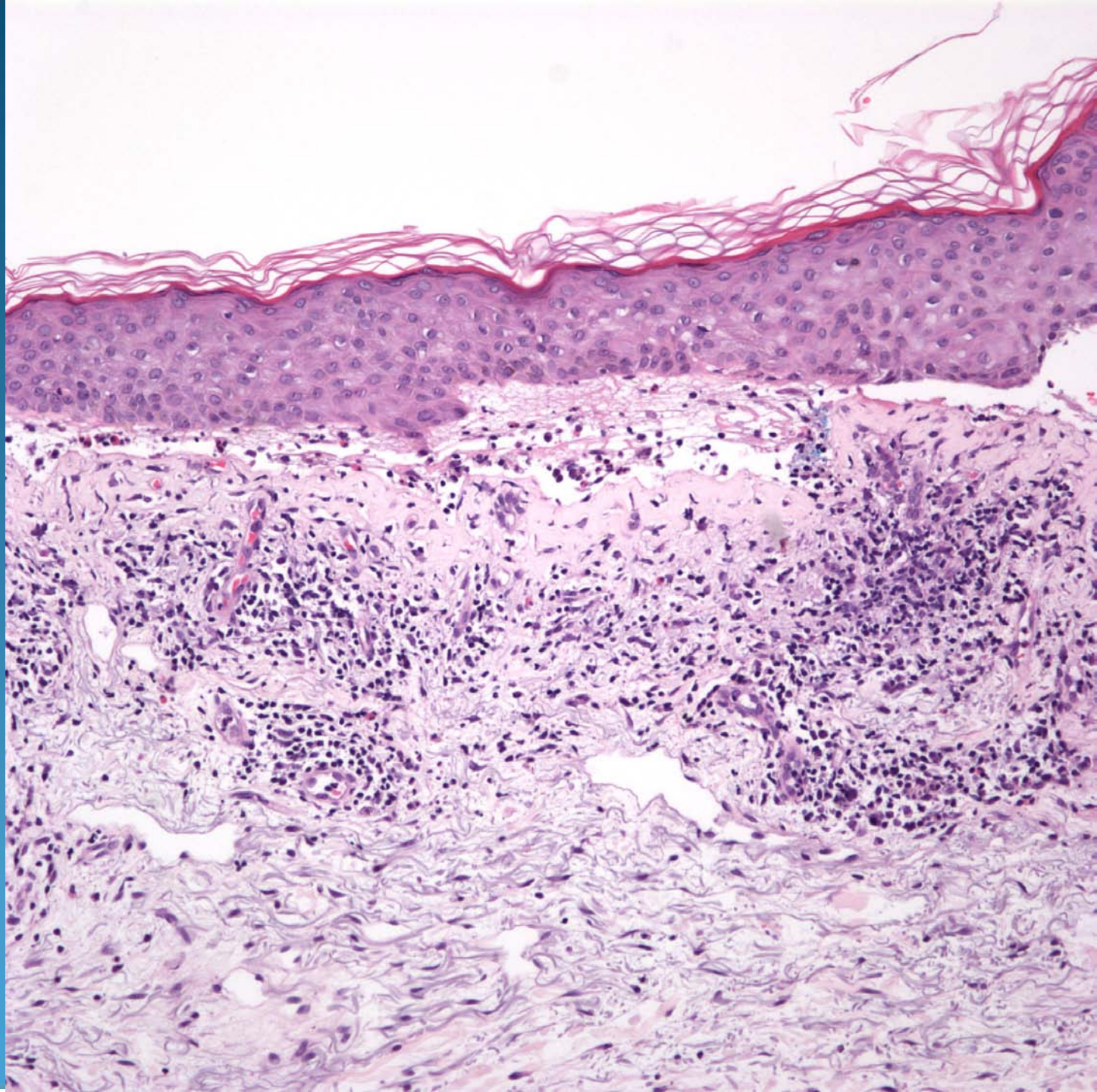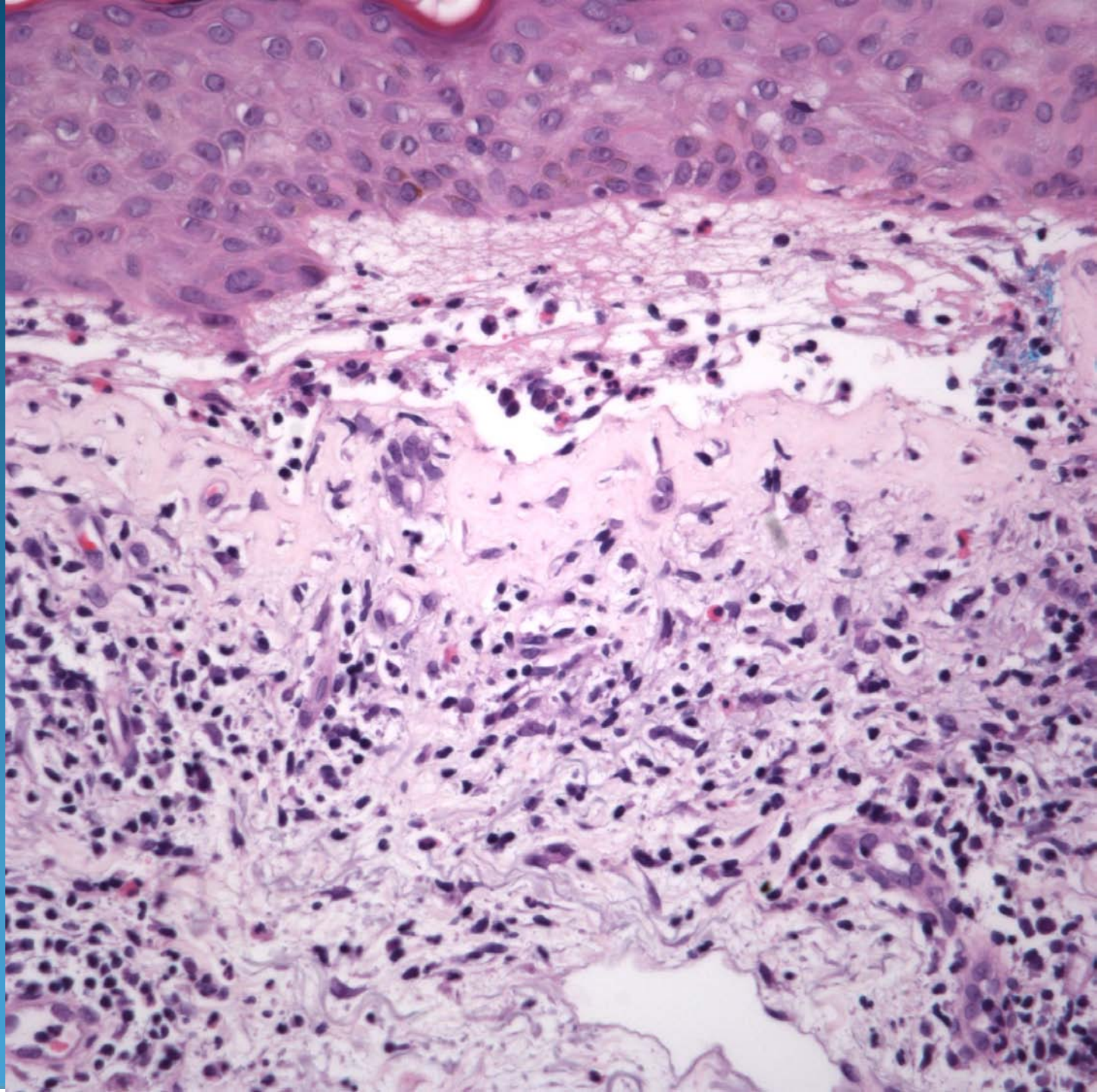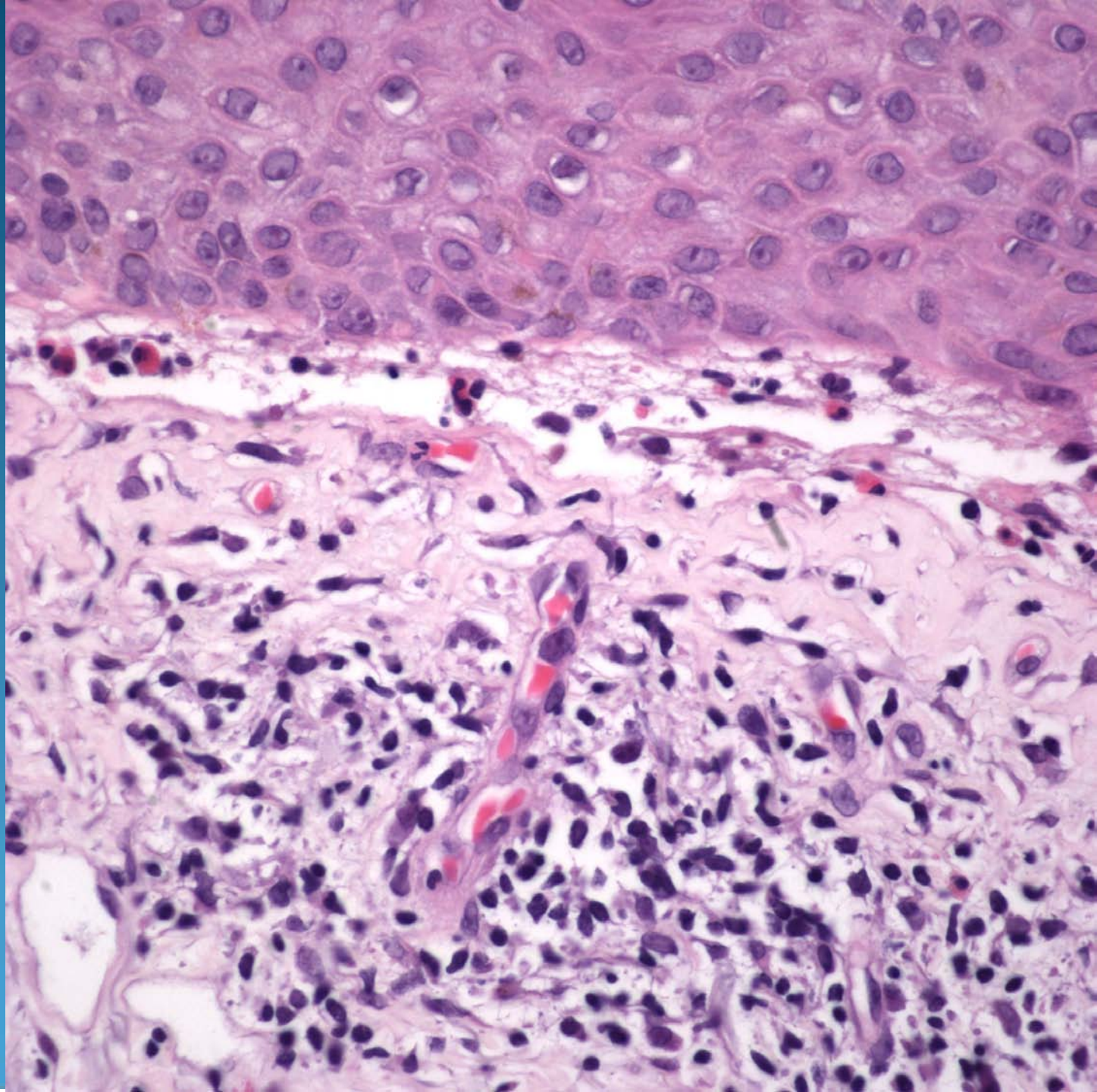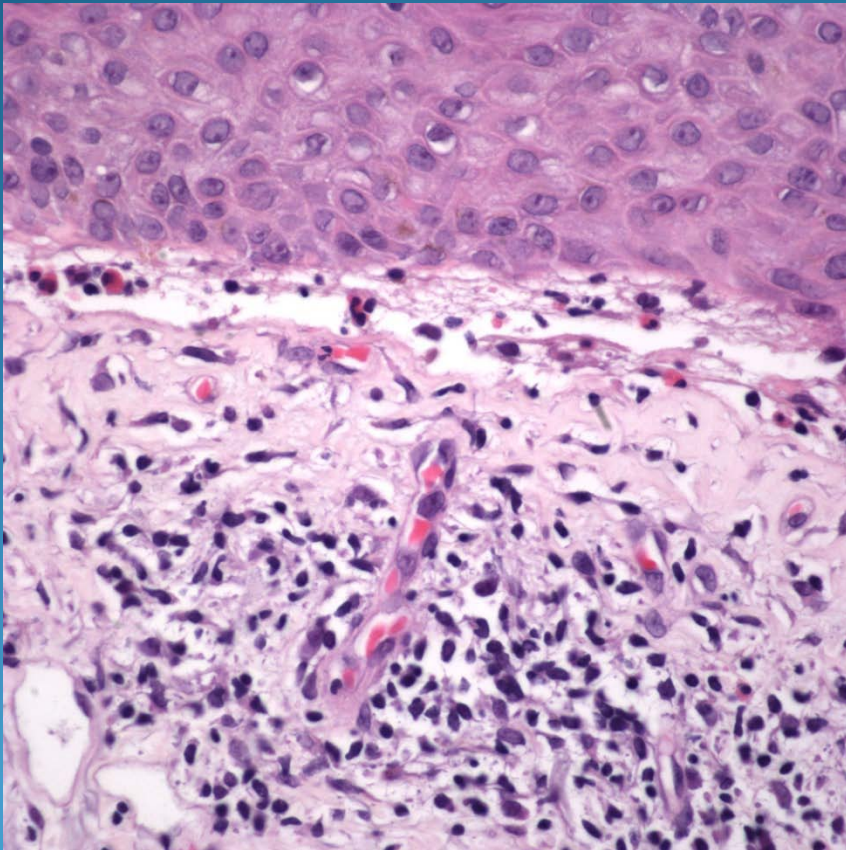


Bullous Pemphigoid

Pearls



- Cell rich or cell poor subepidermal bullae
- Eosinophils predominate over neutrophils
- May have festooning