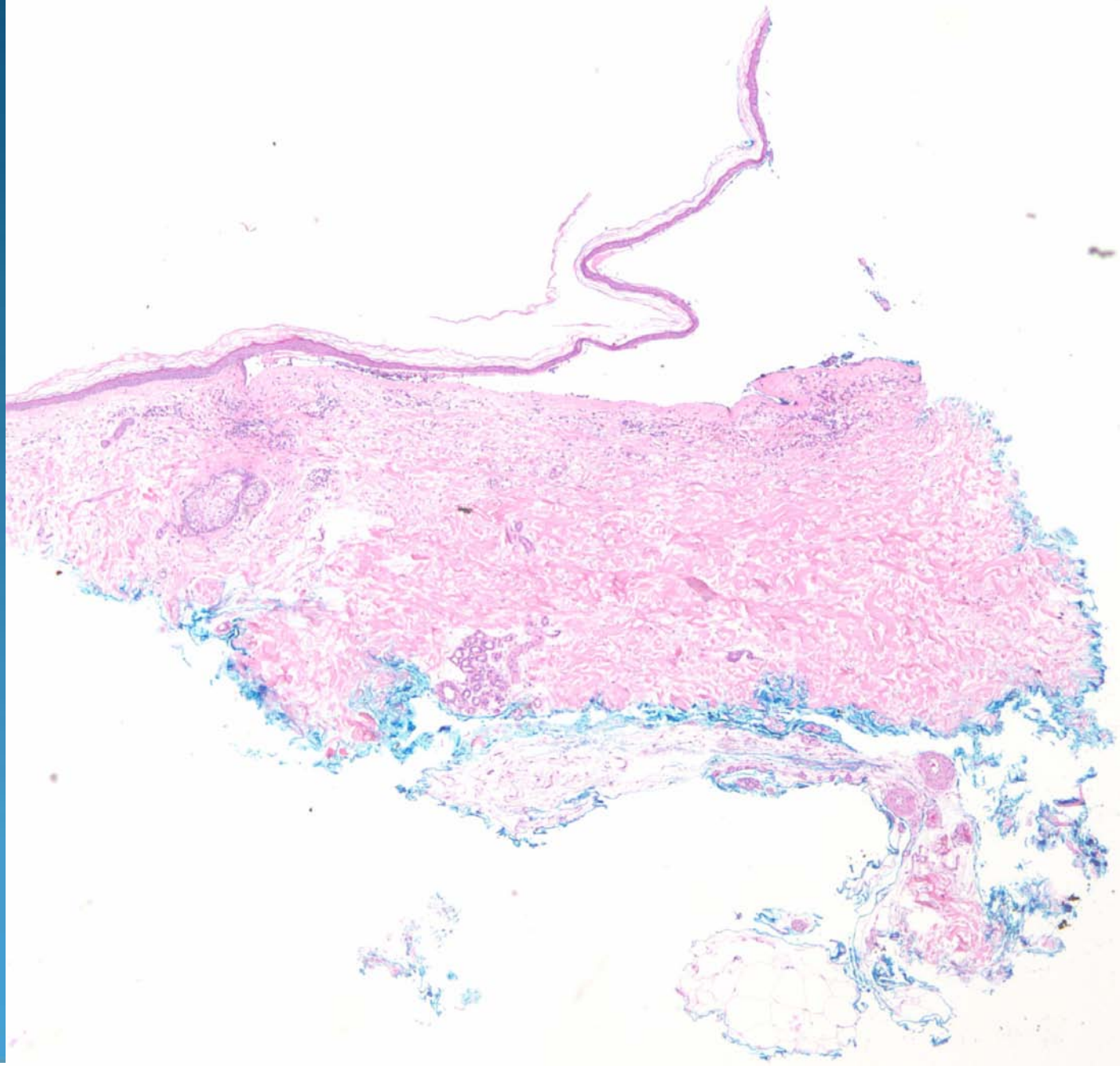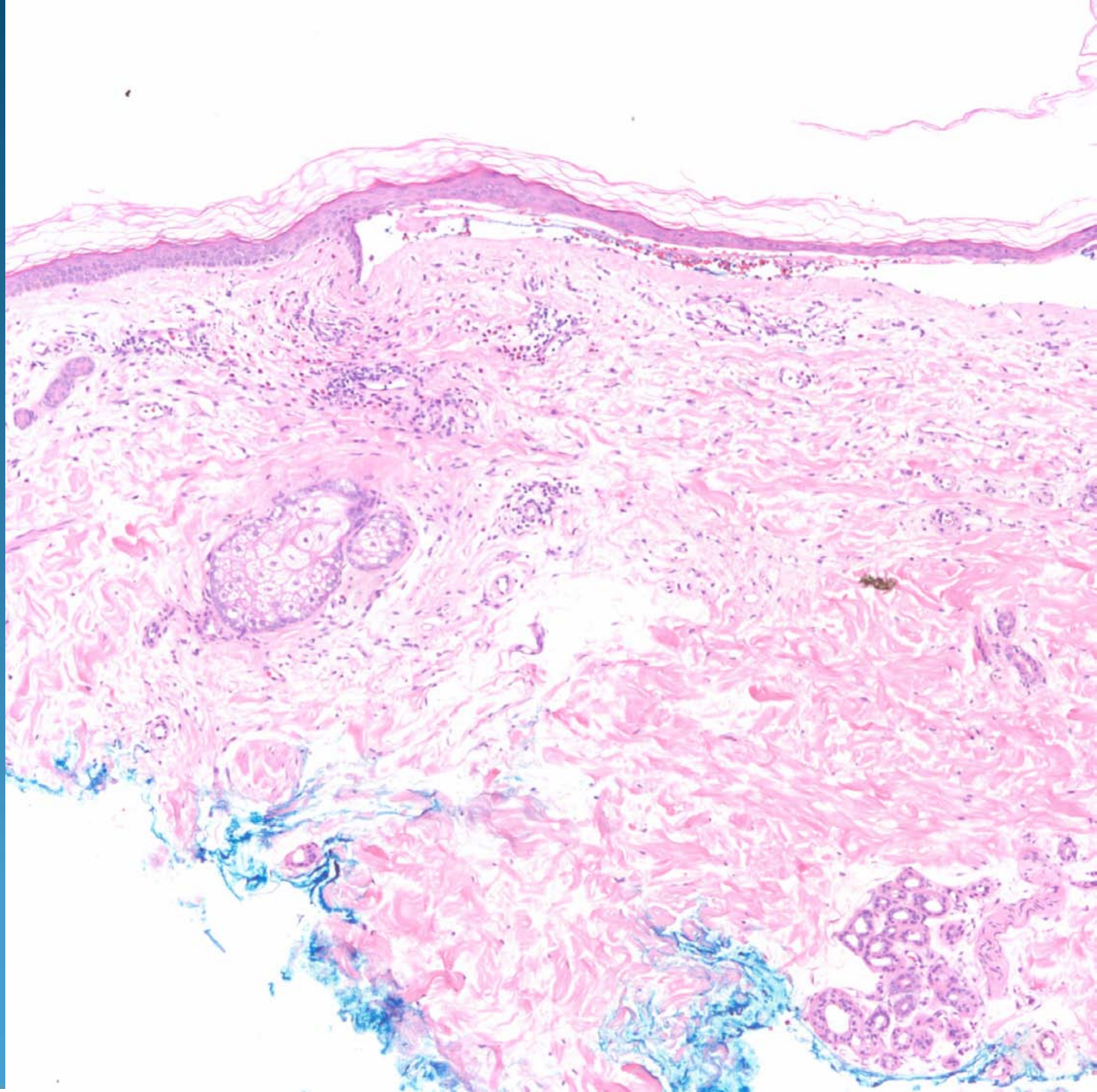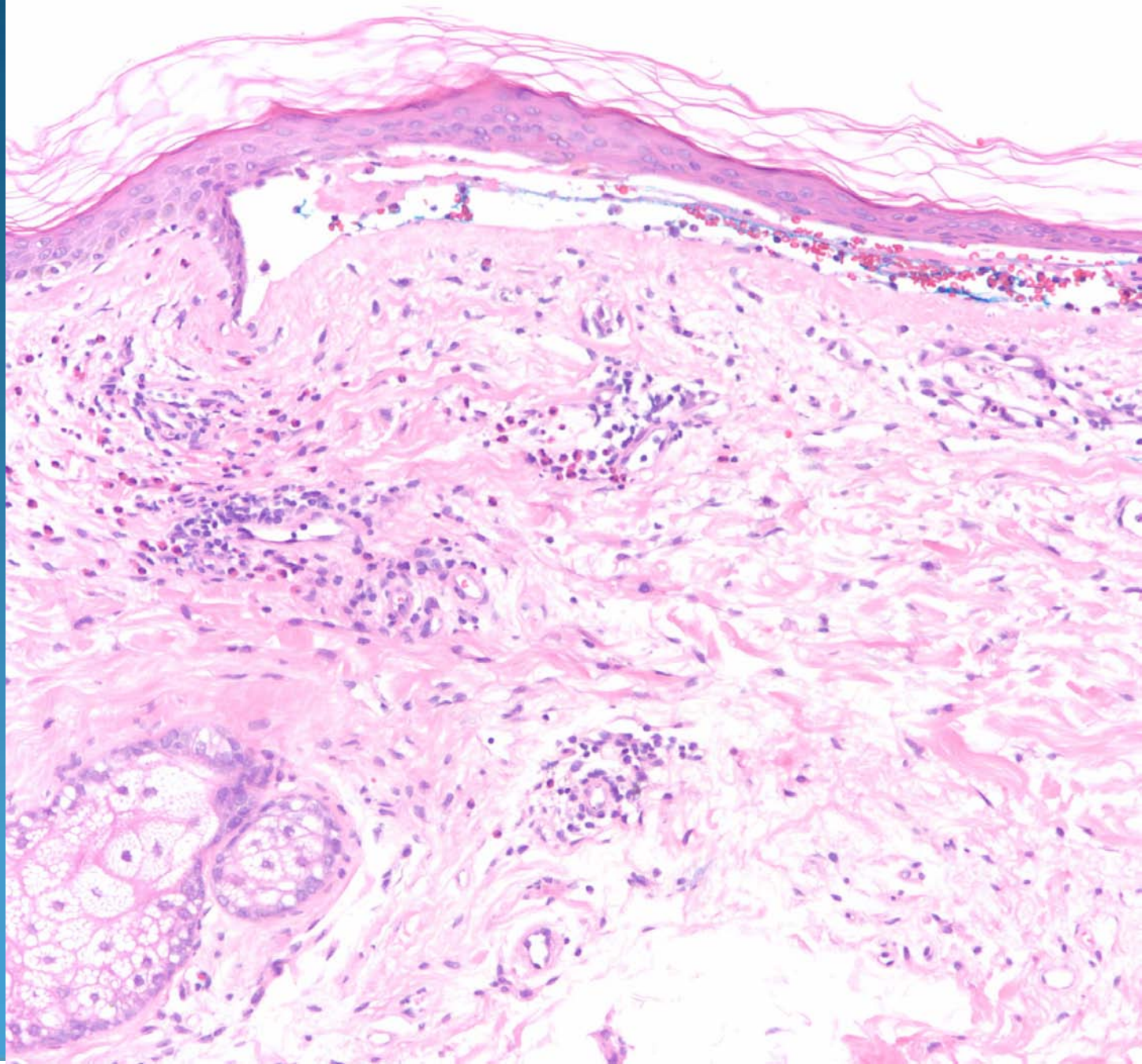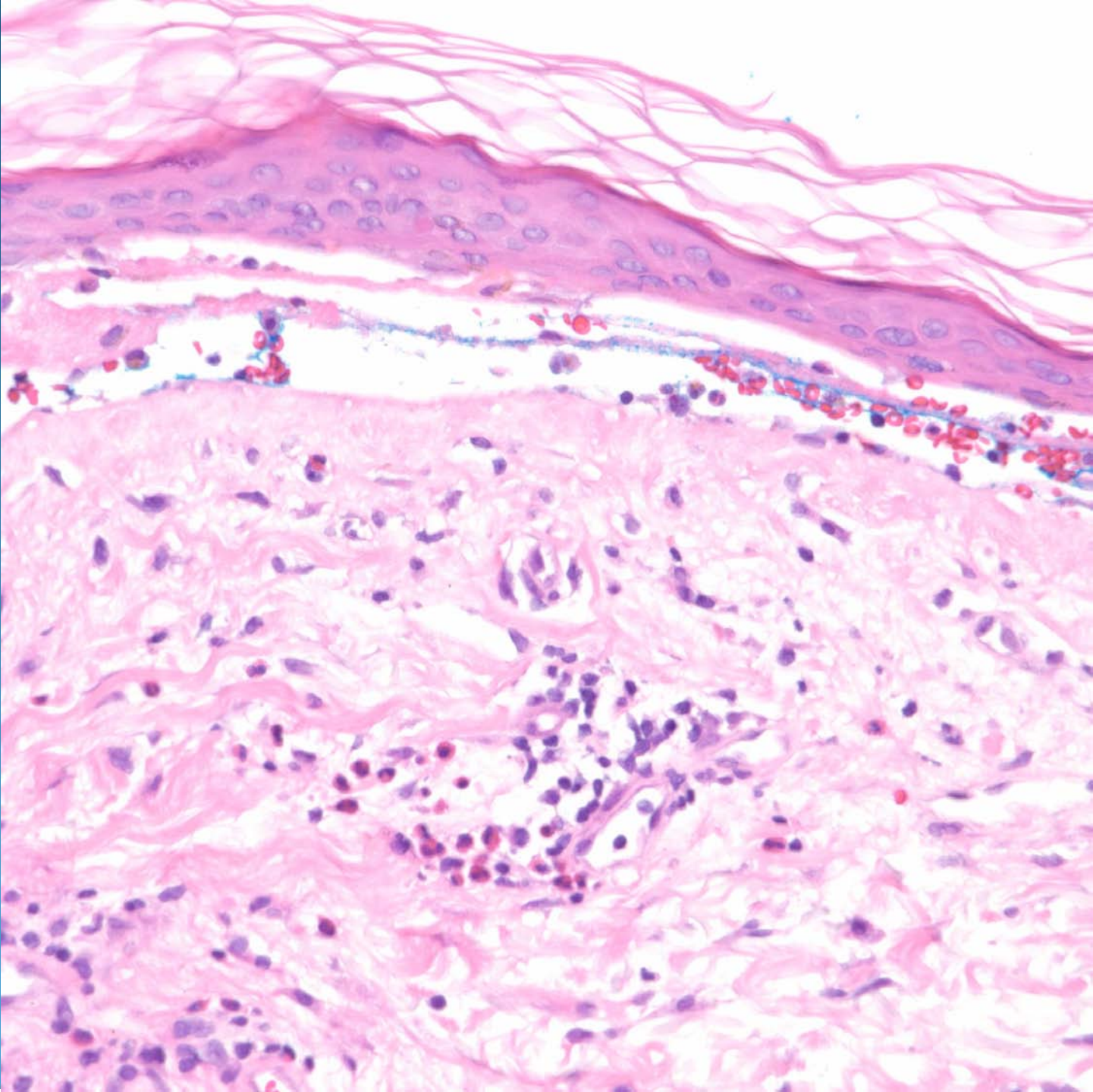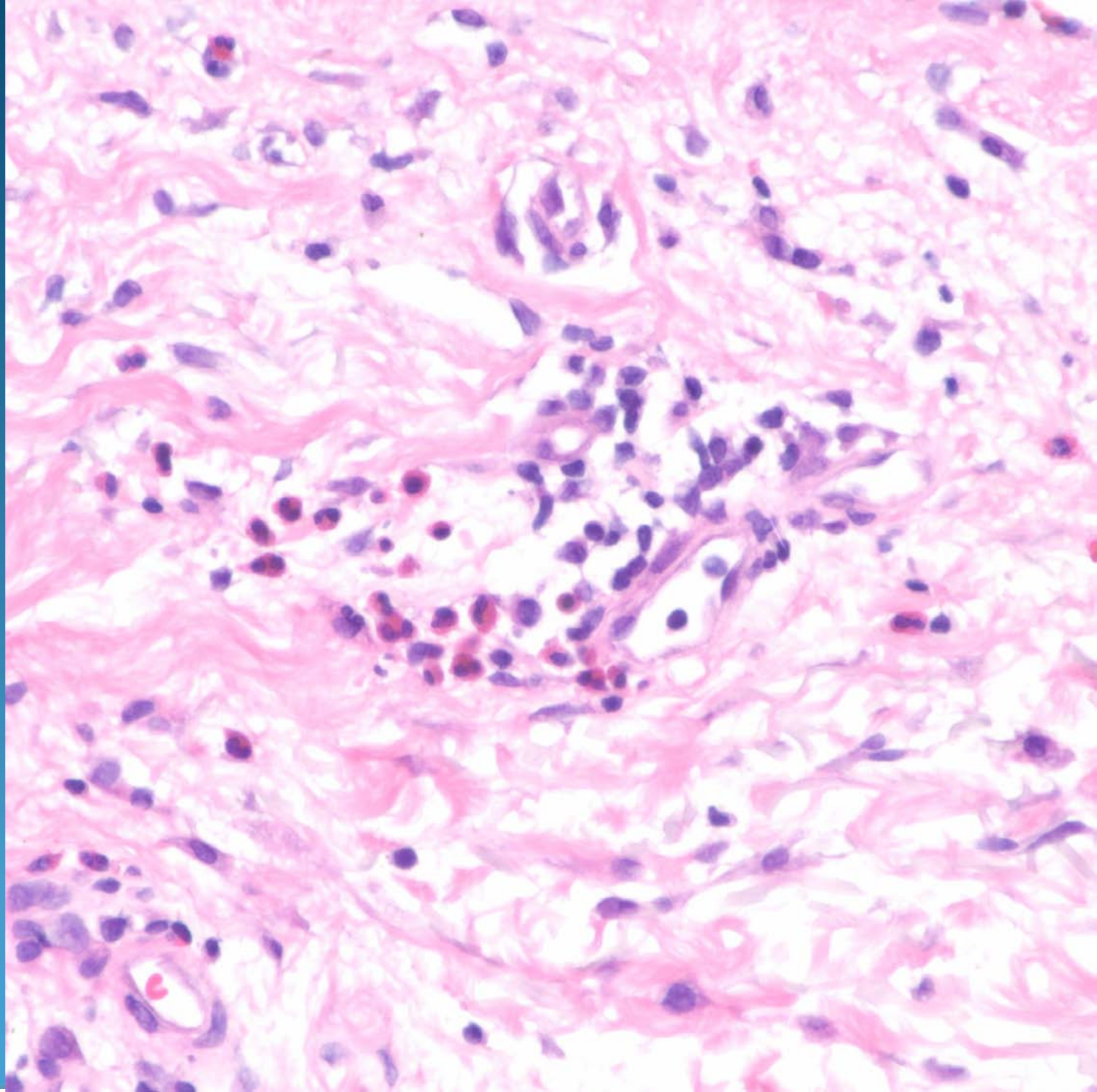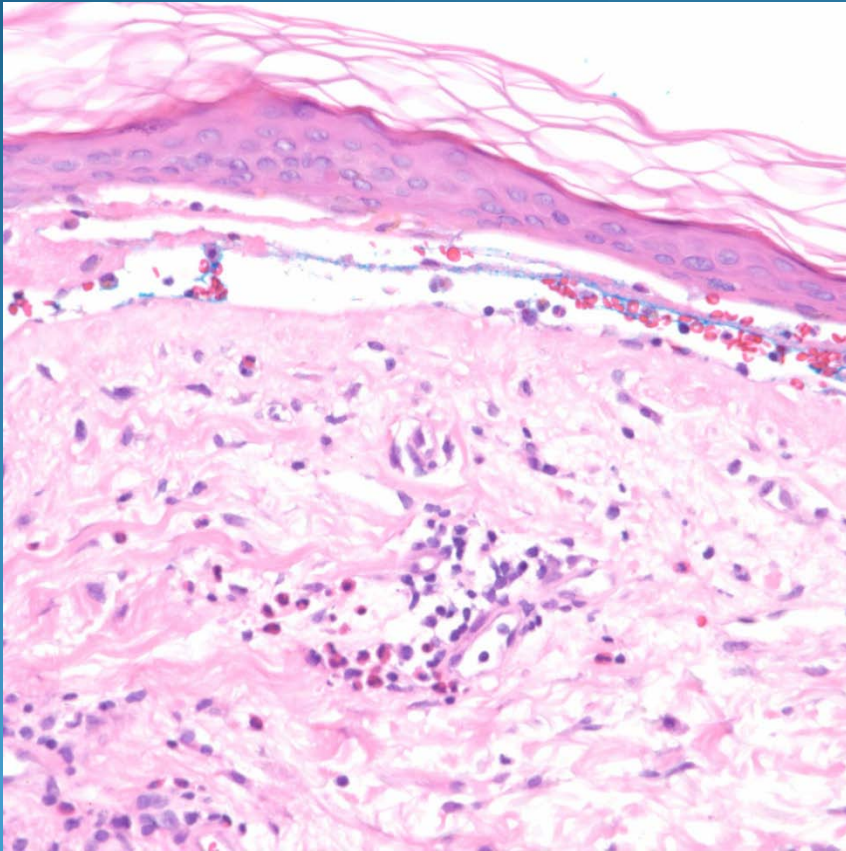




# Bullous Pemphigoid

# Pearls



- Subepidermal bullae without acantholysis
- Variable eosinophilic infiltrate > neutrophils
- May have
- re-epithelialization of dermis mimicking an intraepidermal bullae
- May need to confirm with DIF
- DDX: Bullous hypersensitivity rxn