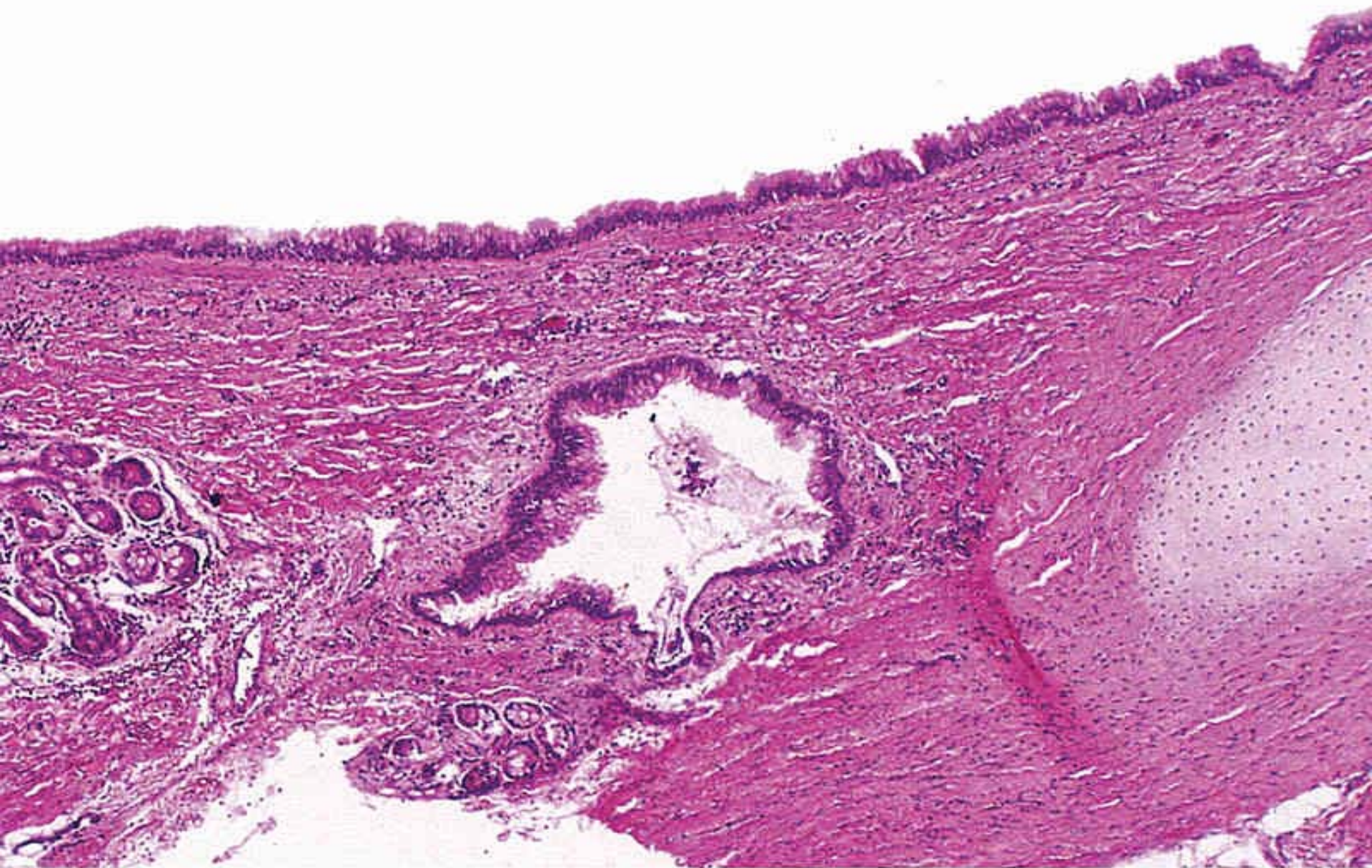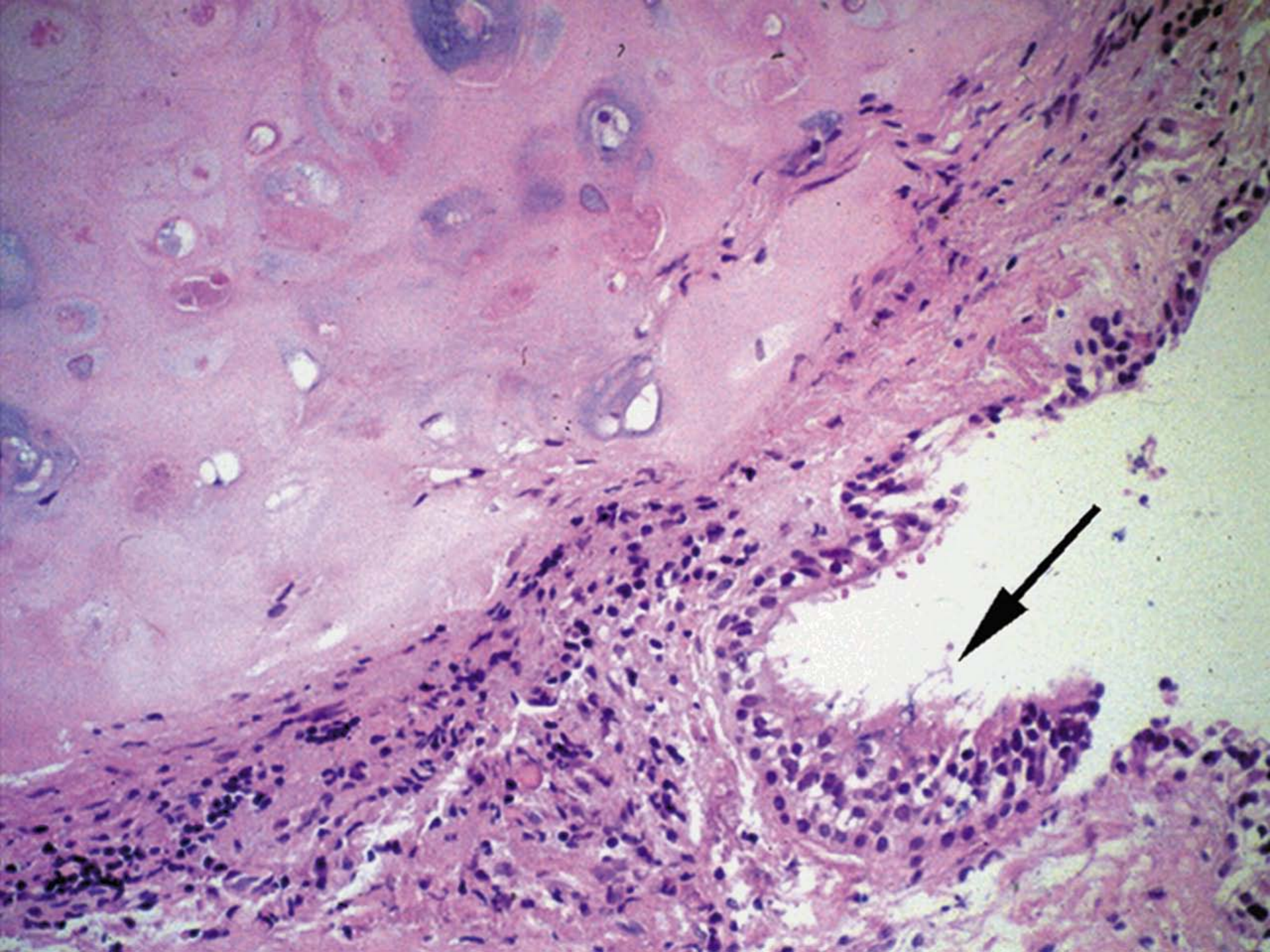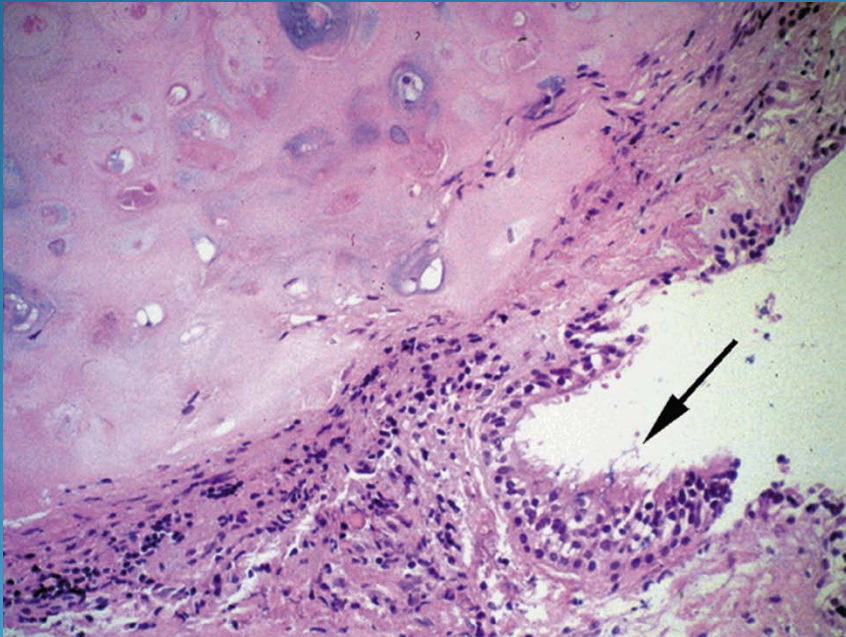


Bronchogenic Cyst

Pearls



- Cyst lined by respiratory type epithelium and cartilage
- Cyst lining may be eroded
- Clinical-pathological correlation