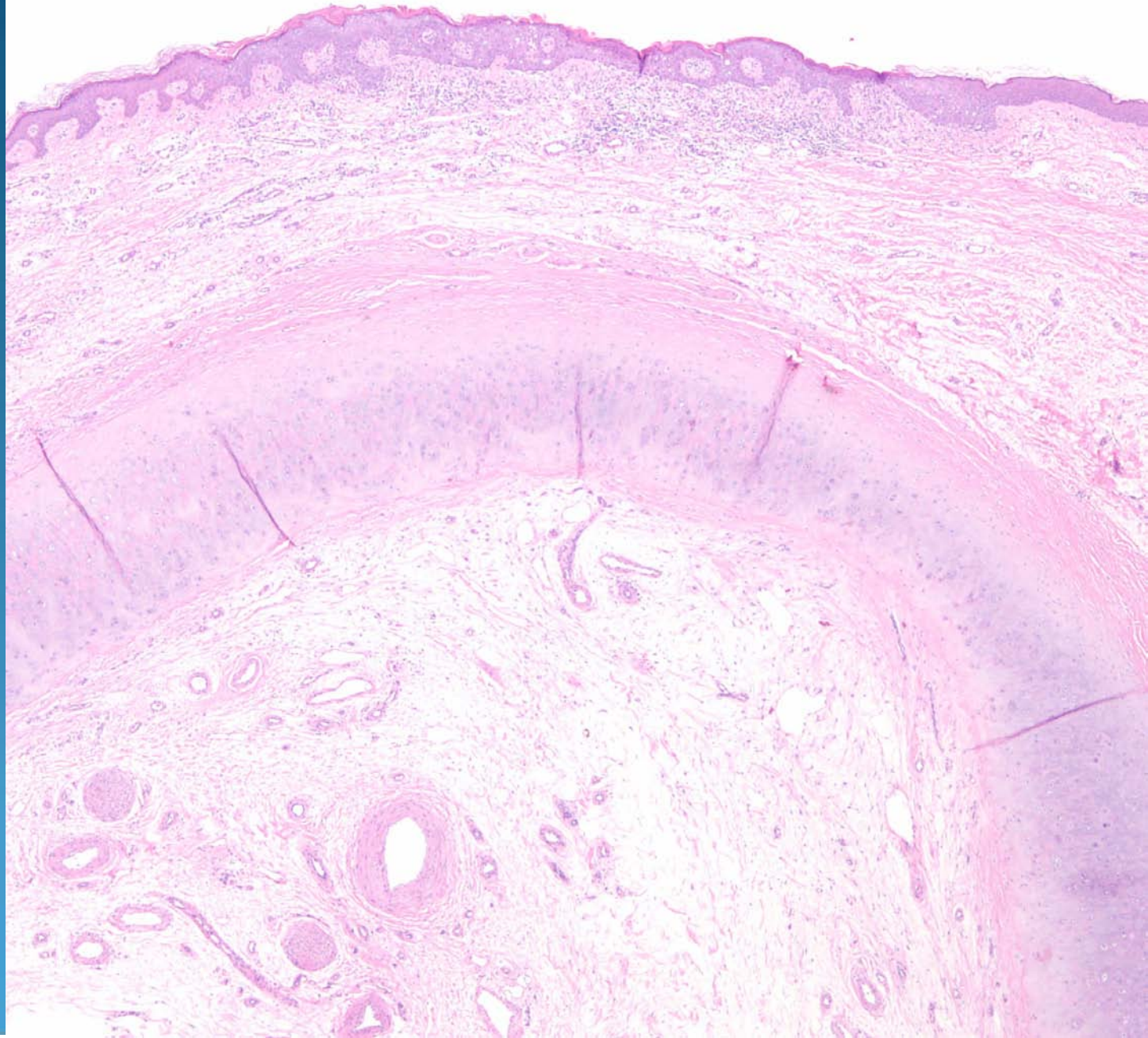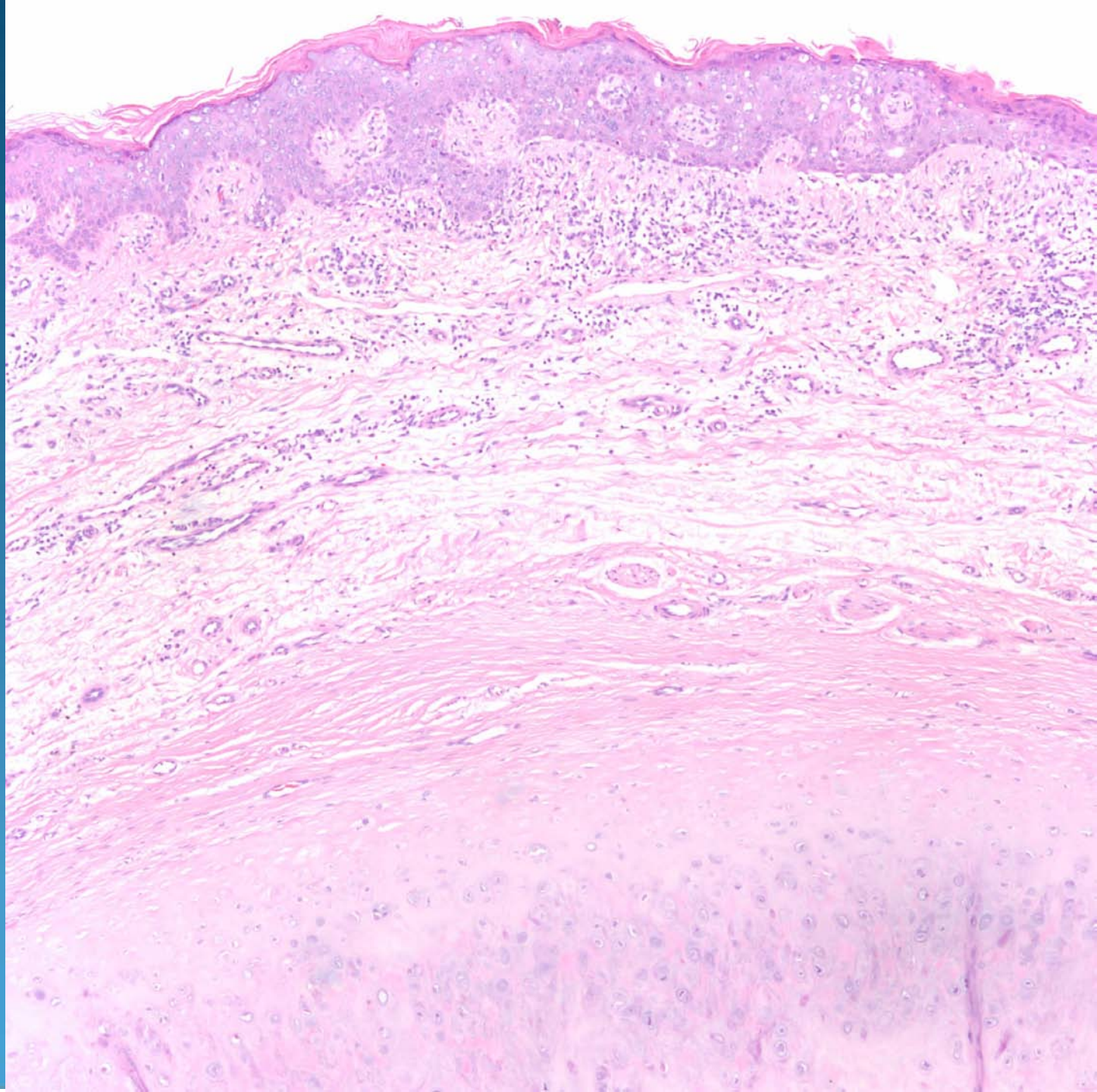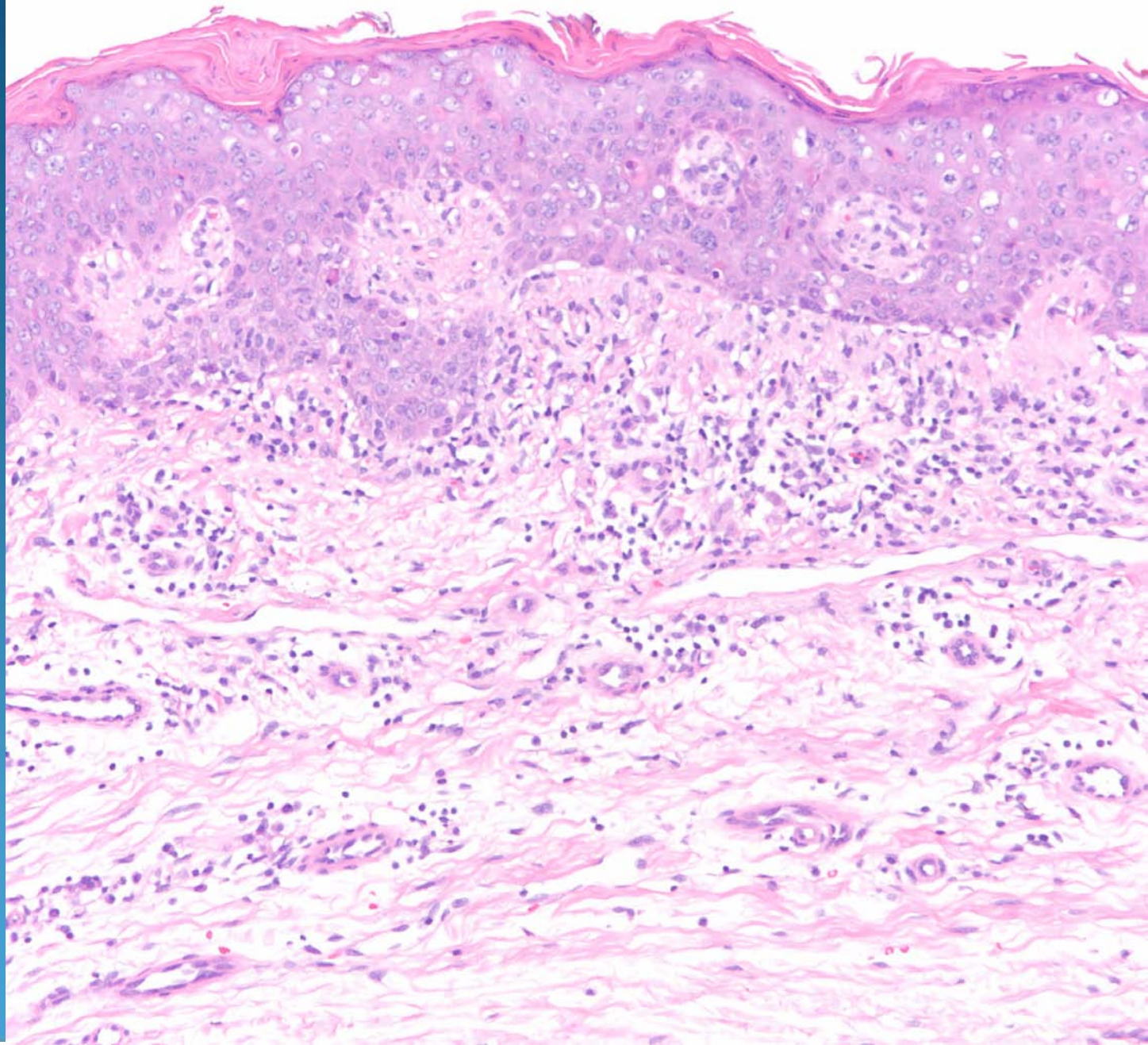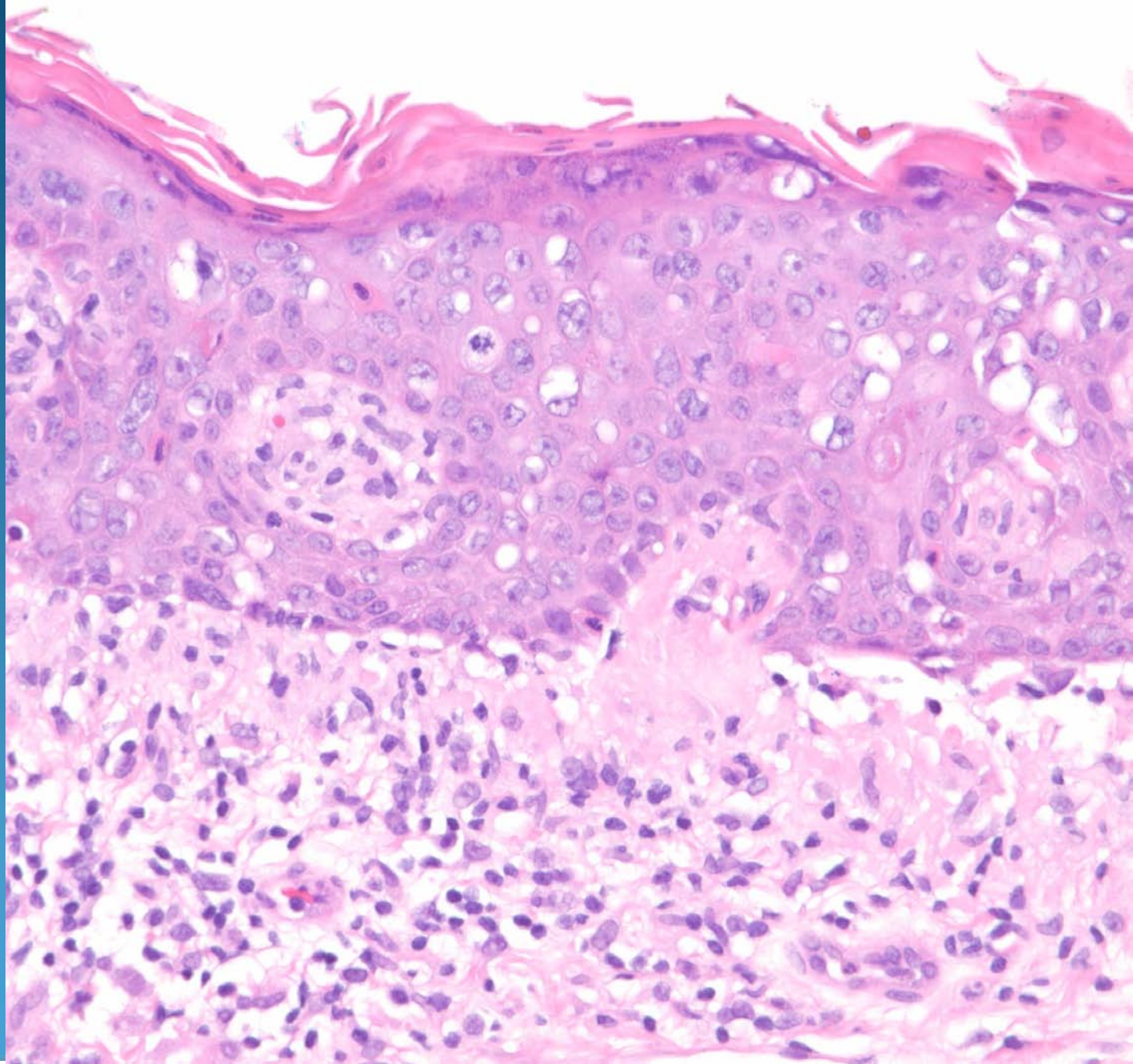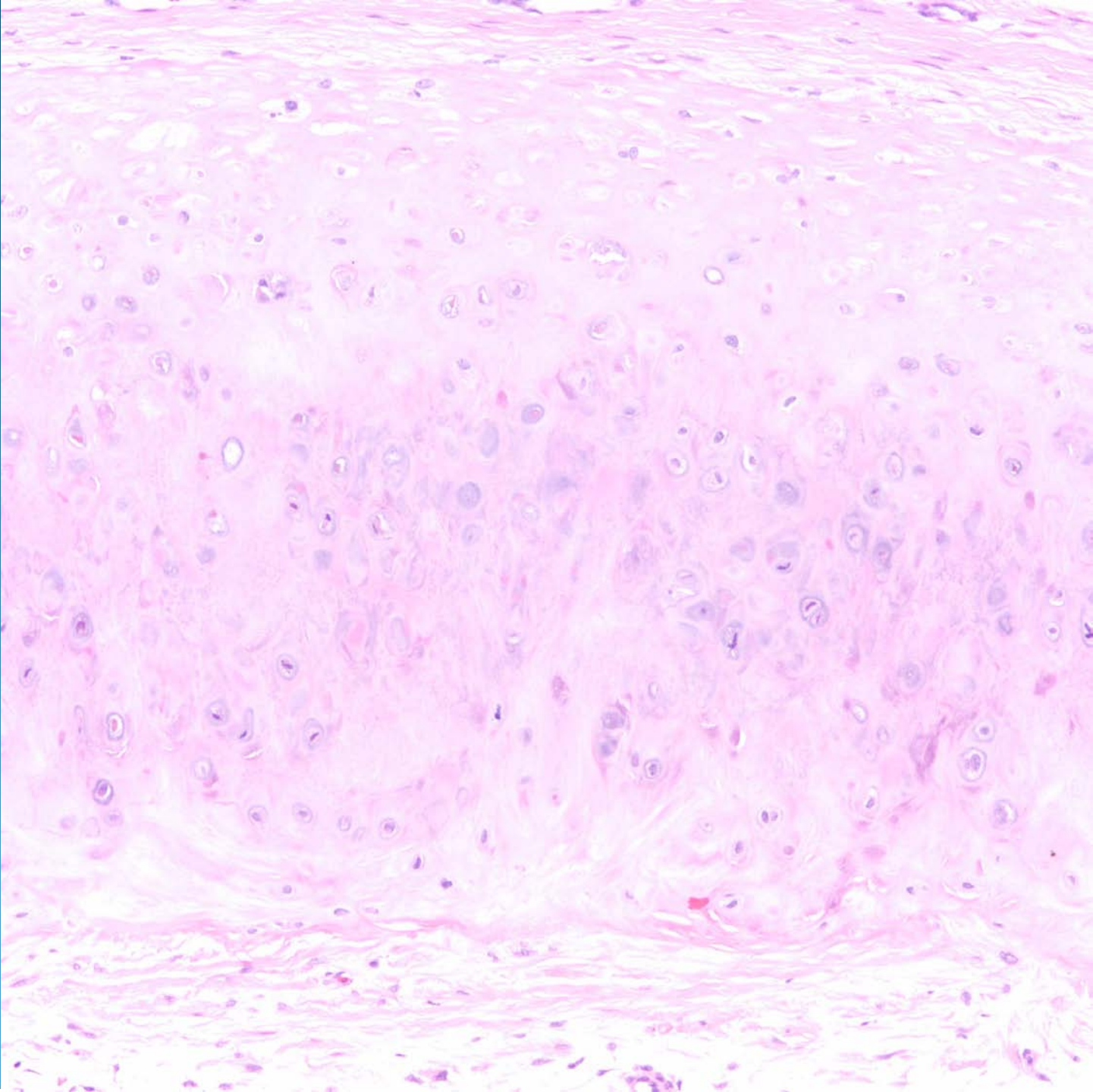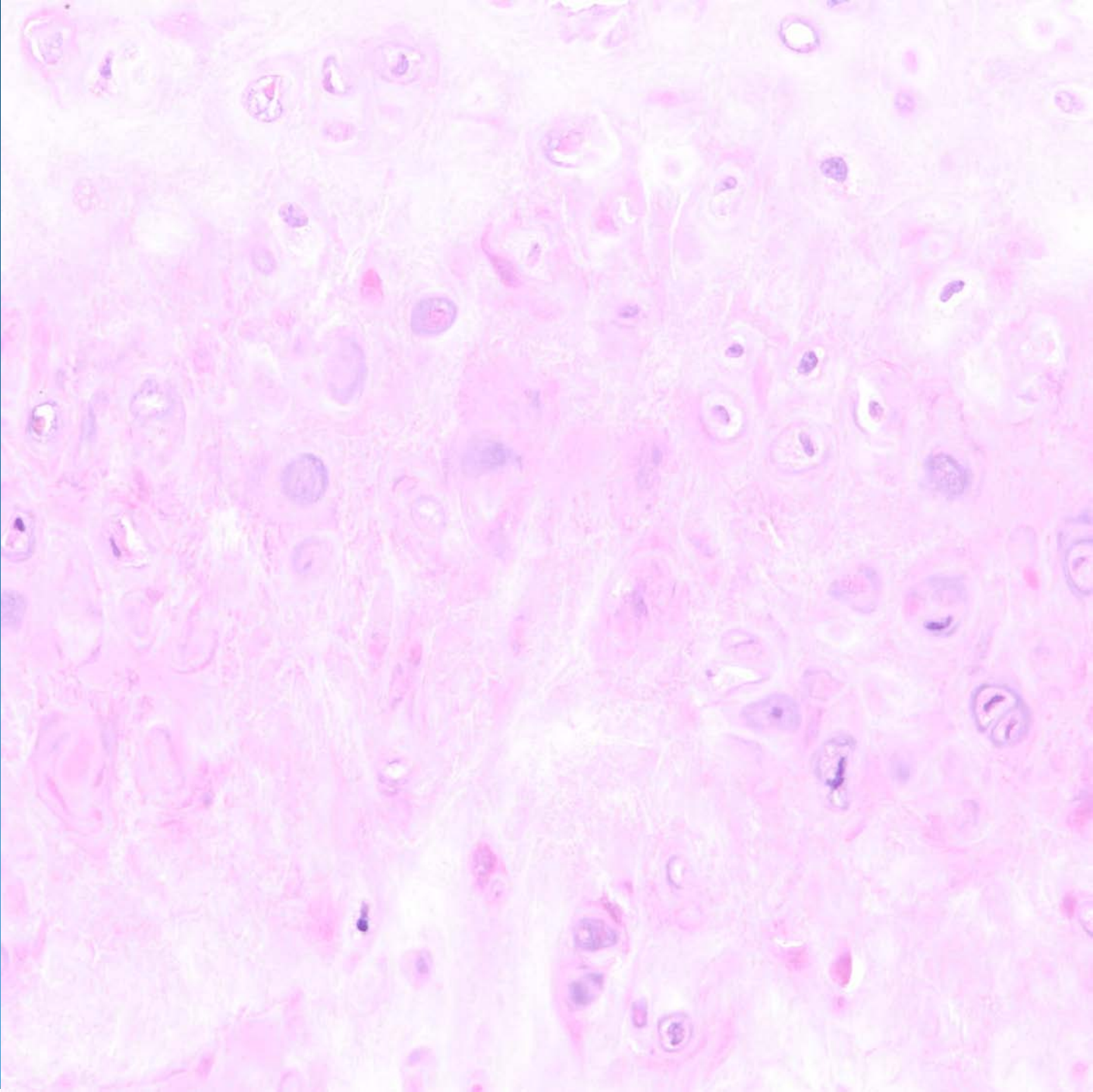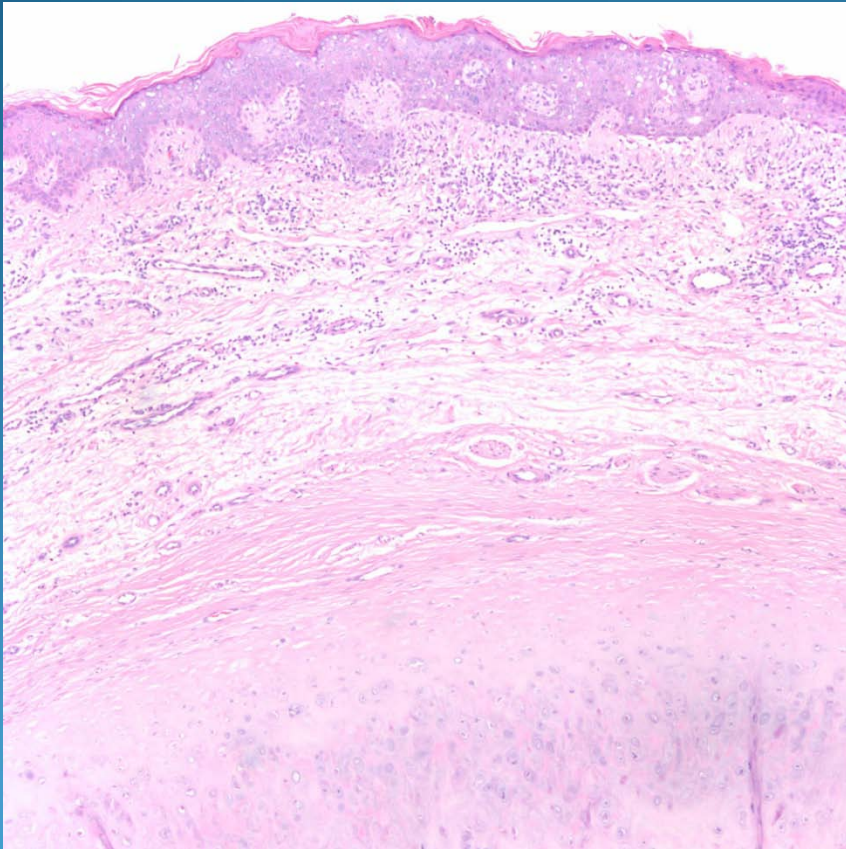


Squamous Cell Carcinoma in Situ, Excised from the Helix of the Ear

Pearls



- Conventional SCCIS but arising on ear
- Important to recognize cartilage to determine the site of the biopsy
- Learn normal cartilage differentiate from neoplastic cartilage