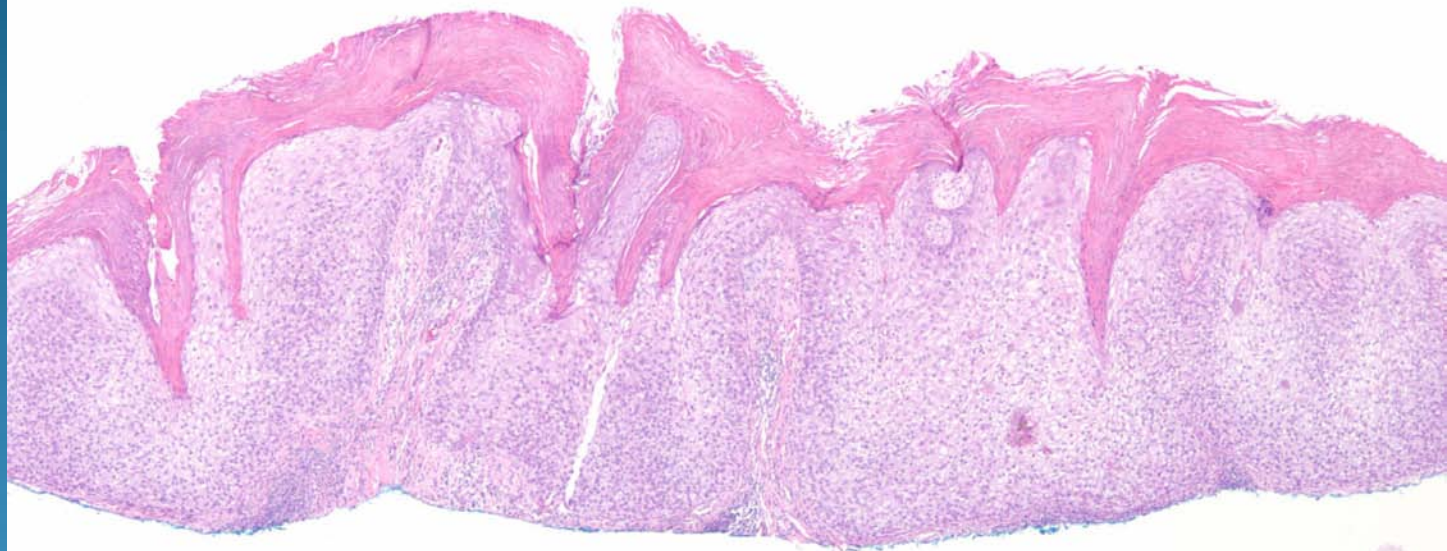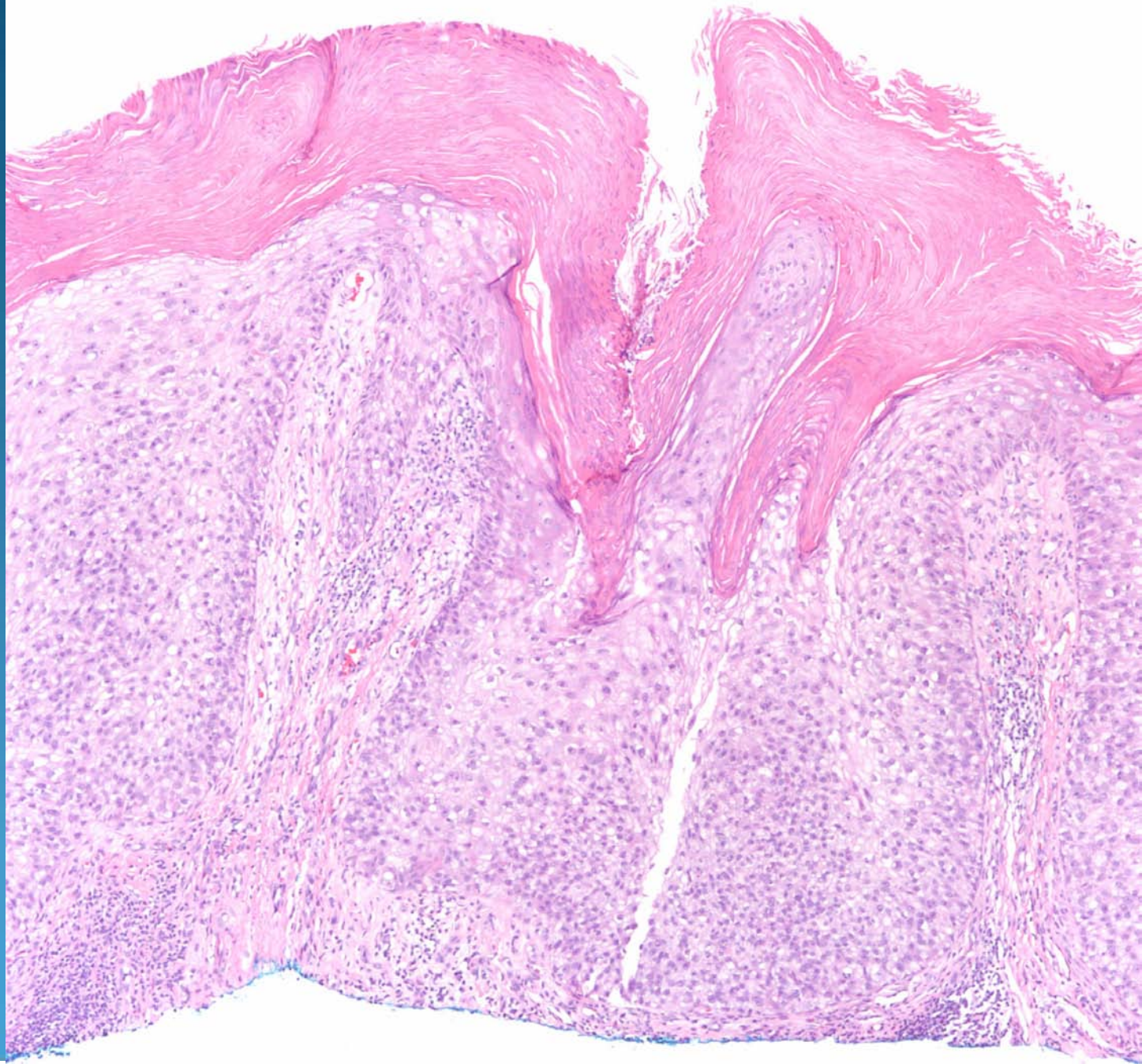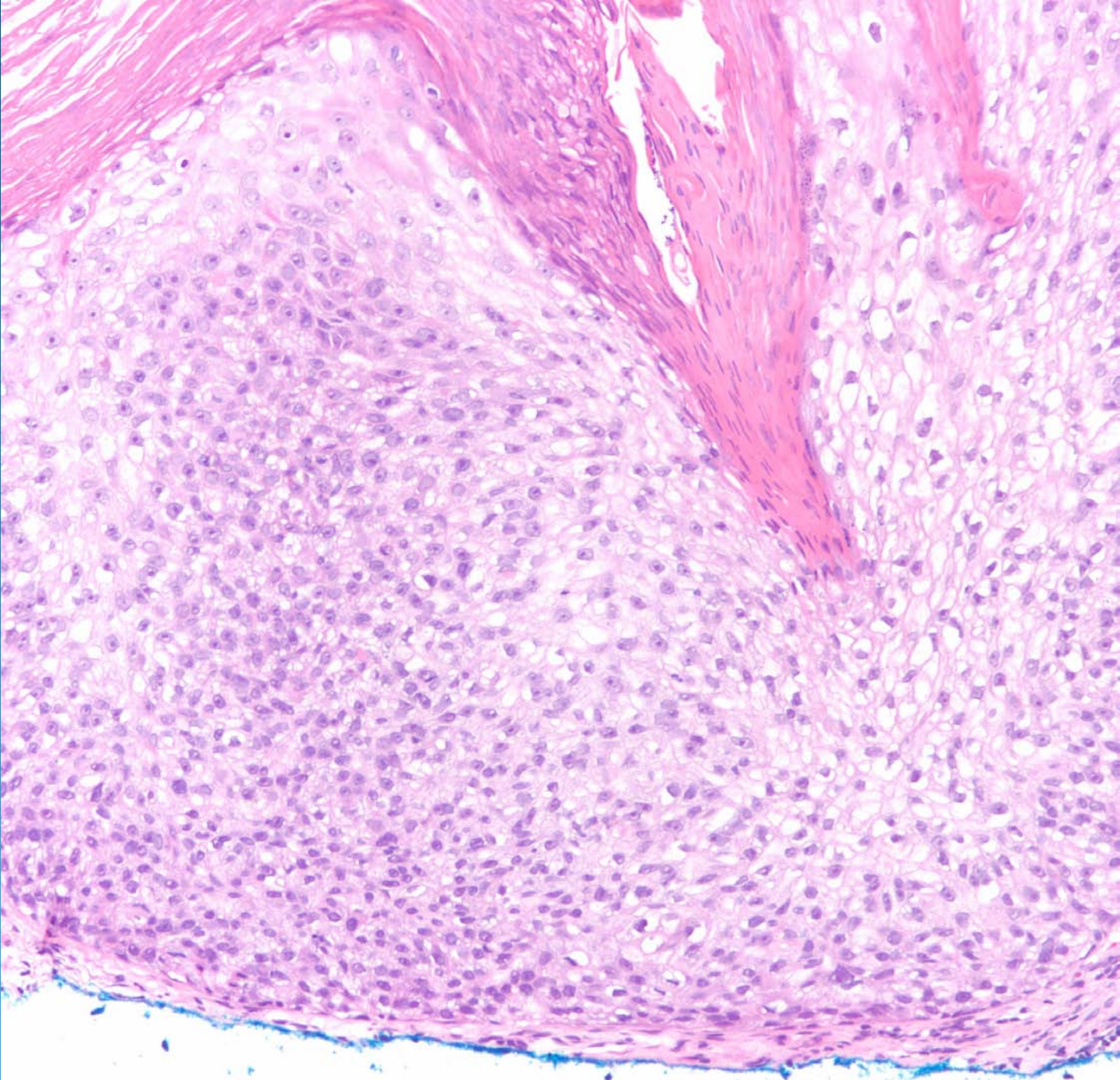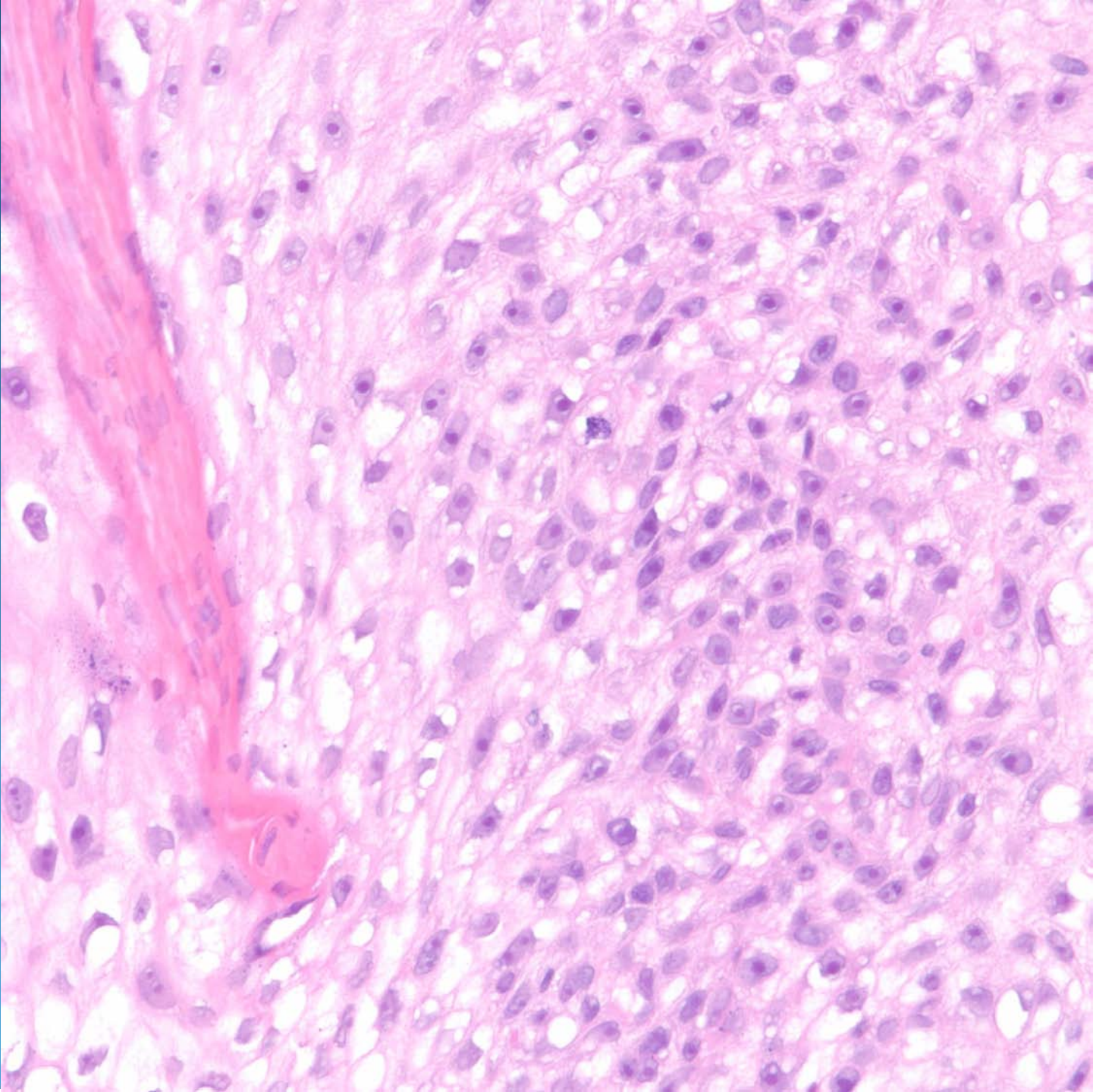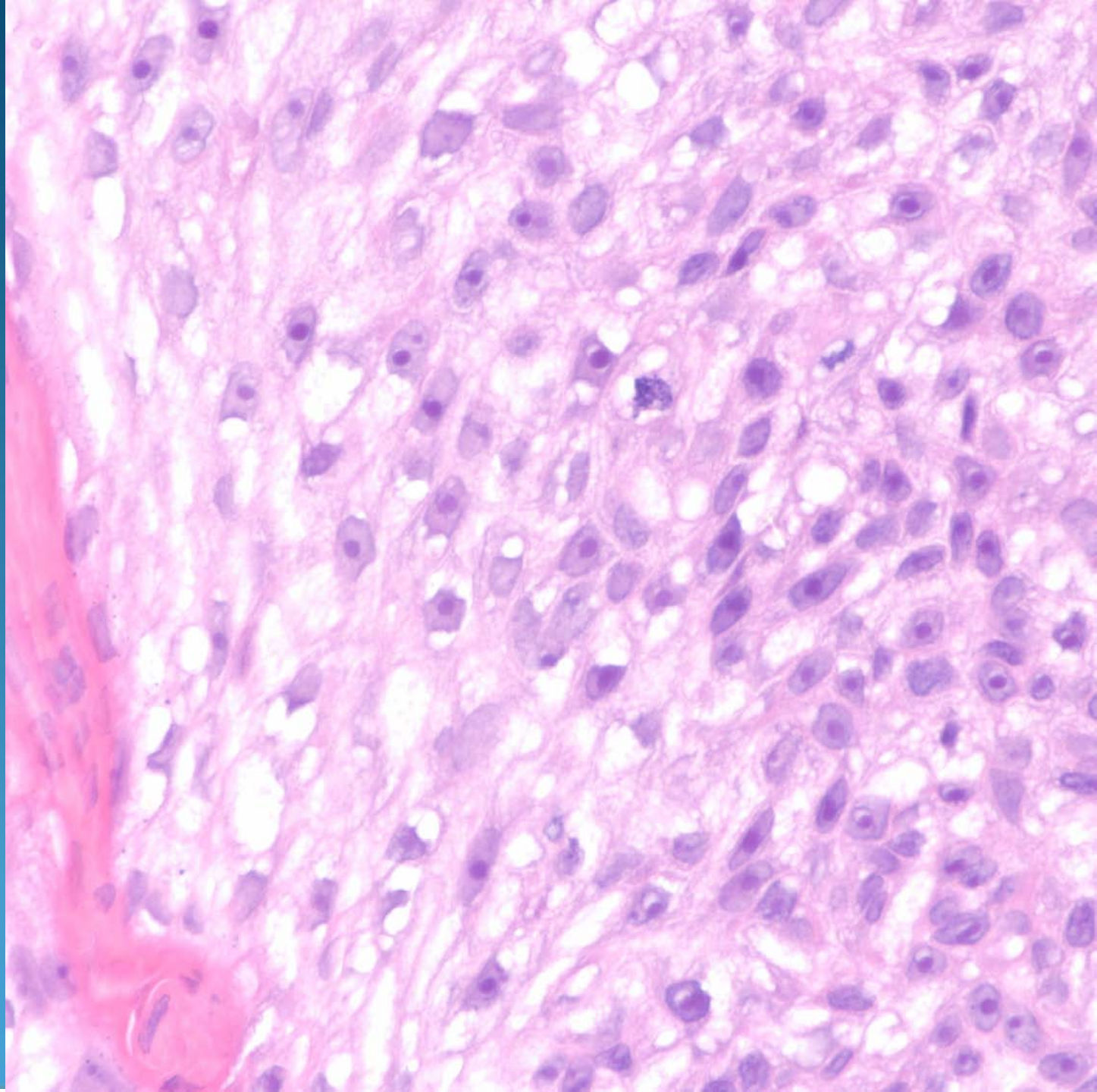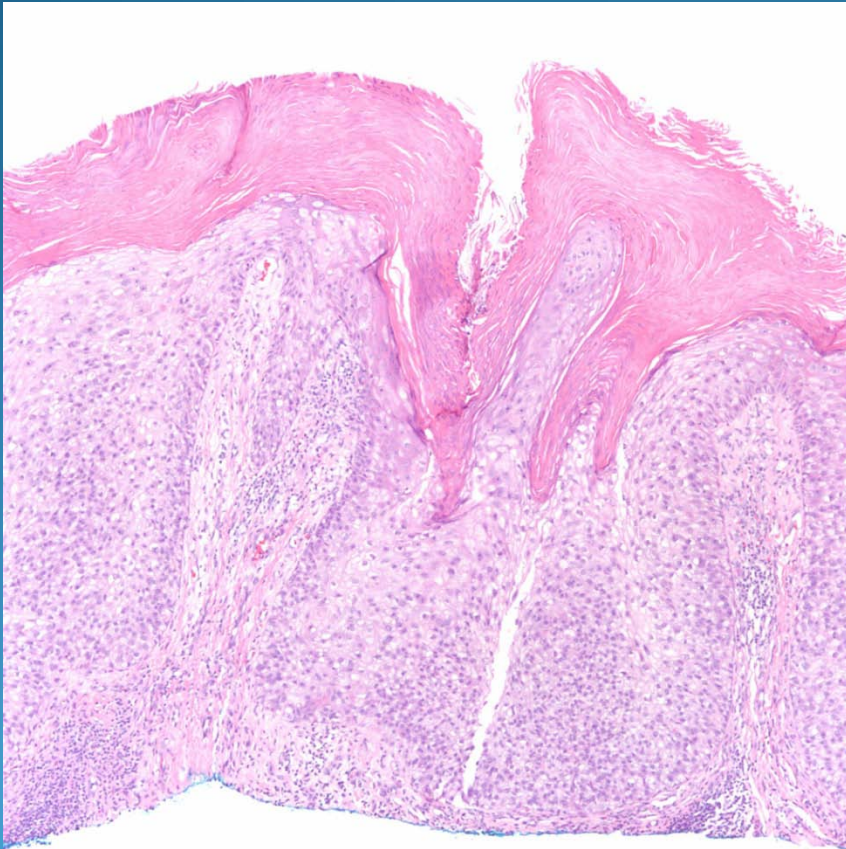


Bowen's Disease-Clear Cell Type

Pearls



- Full thickness atypical keratinocytes replace epidermis
- Clear cytoplasmic changes
- Scattered atypical mitotic figures and loss of polarity
- DDX: Clear cell acanthoma, lacks cytologic atypia