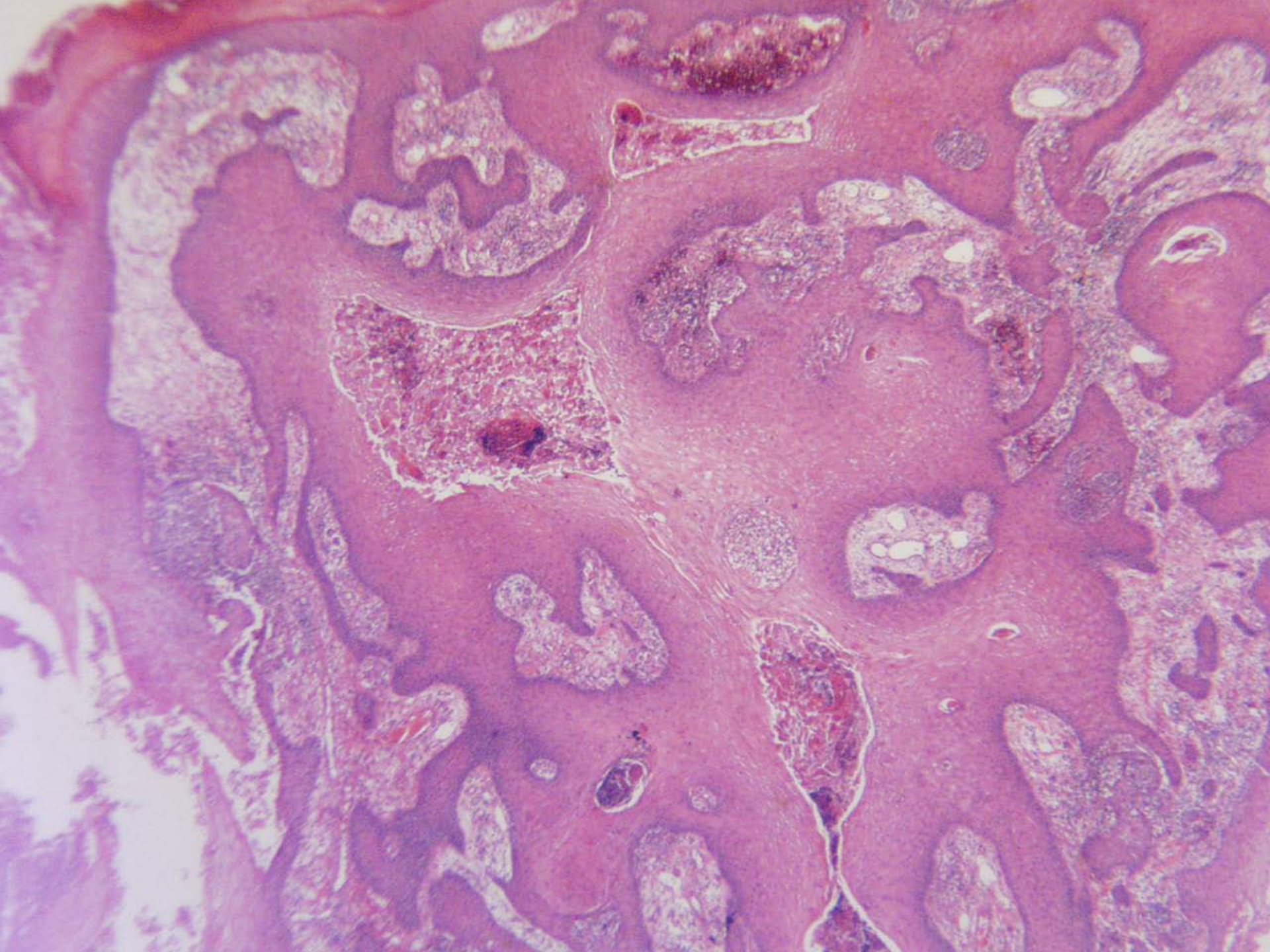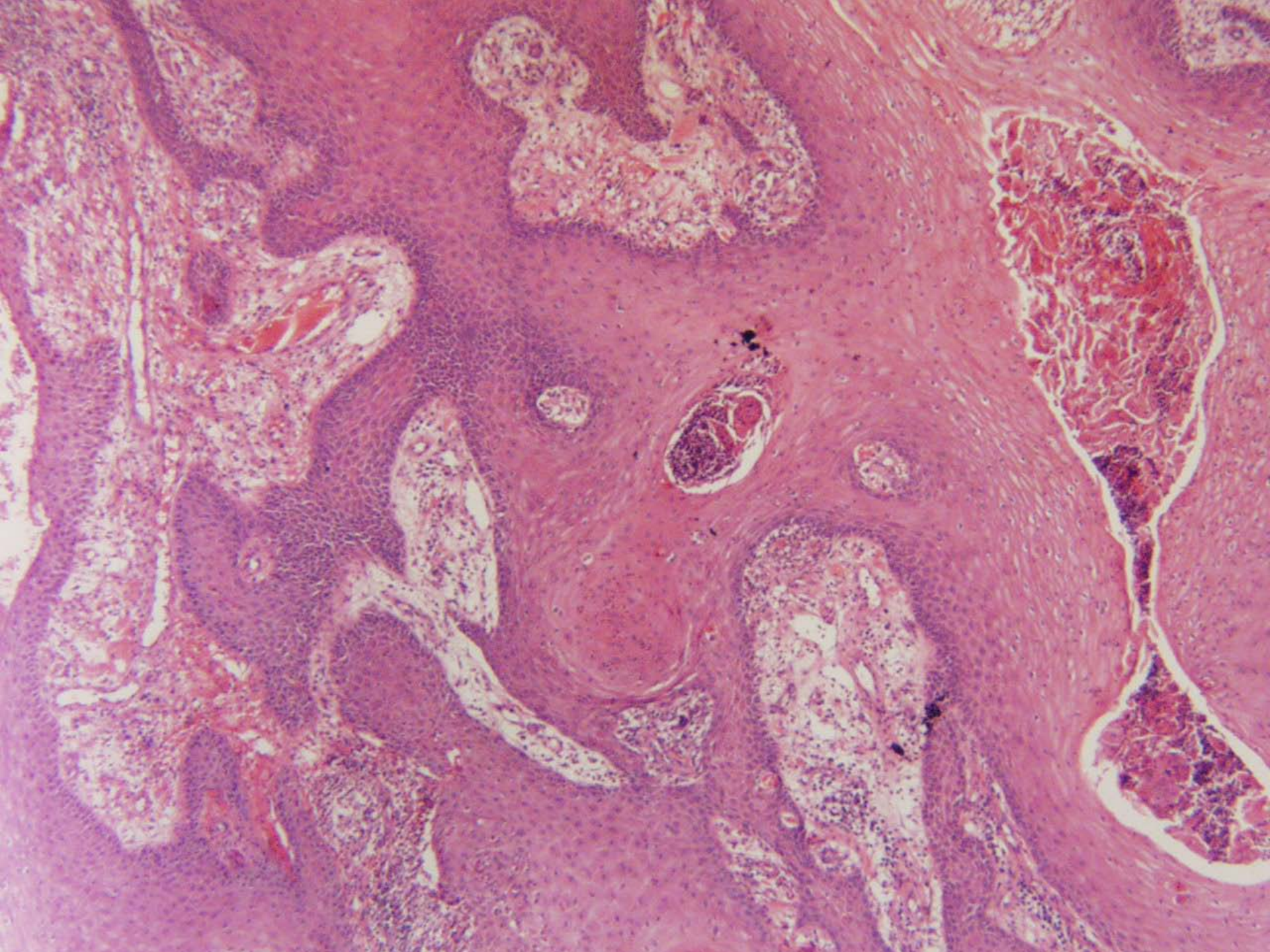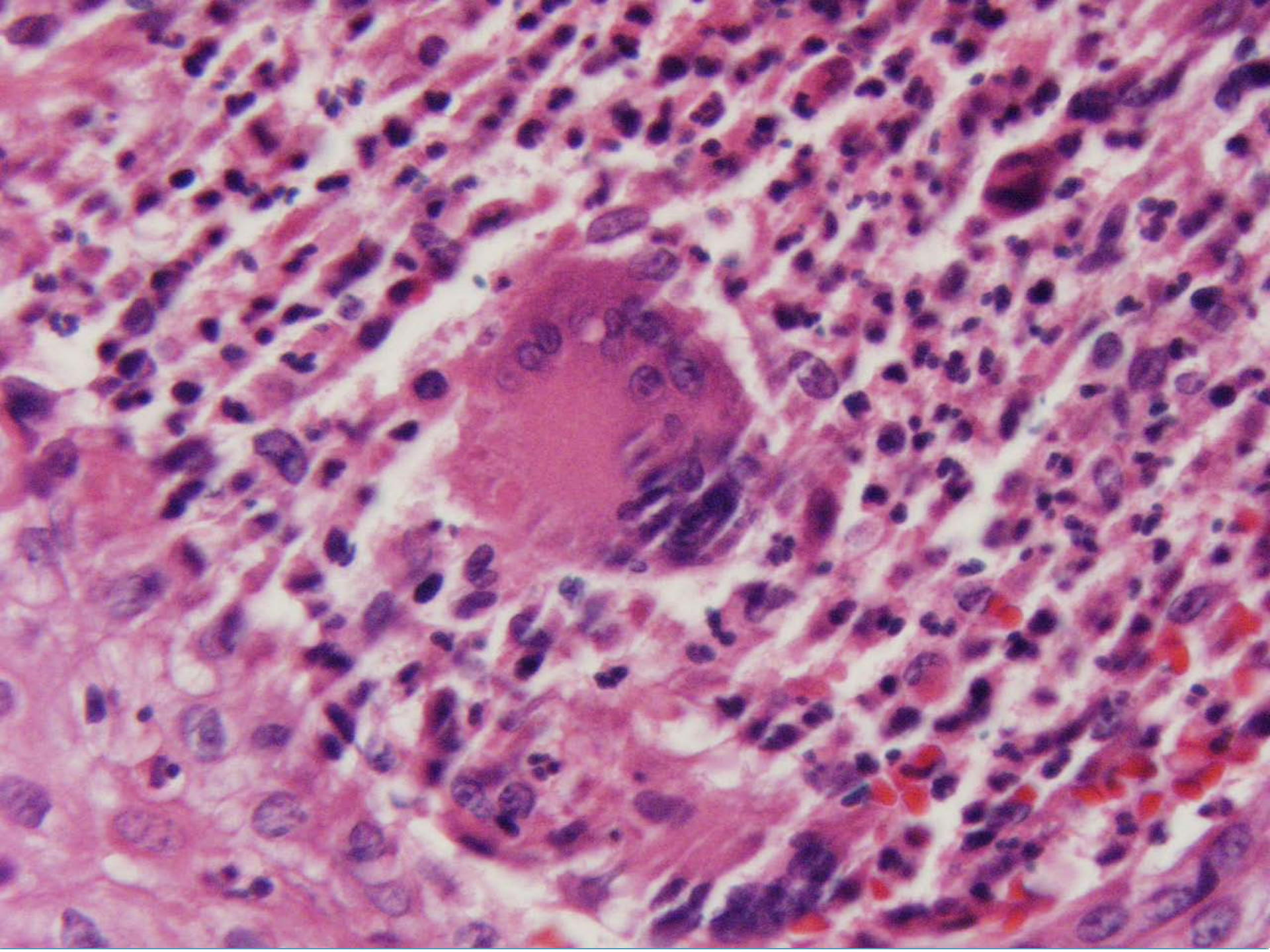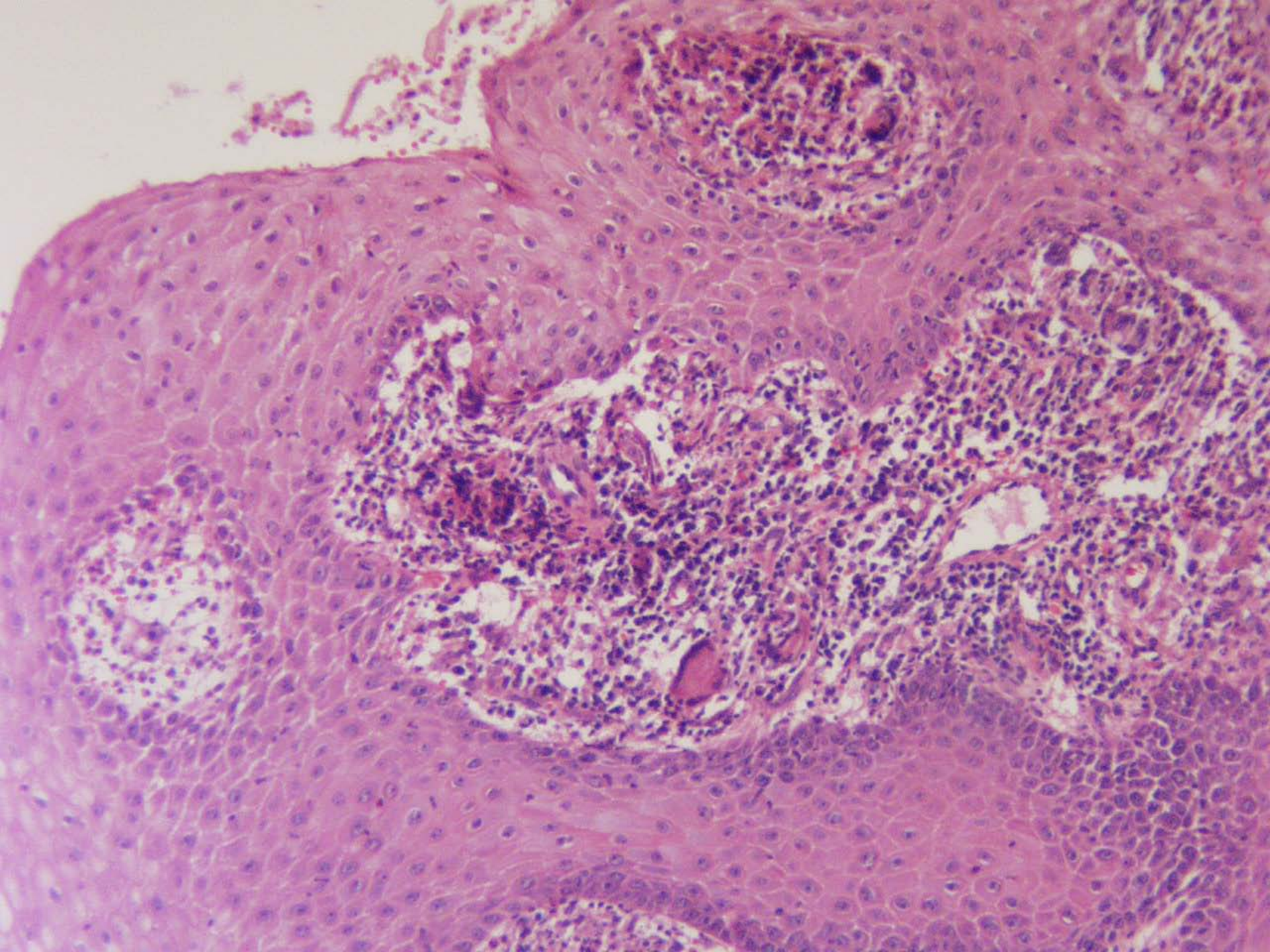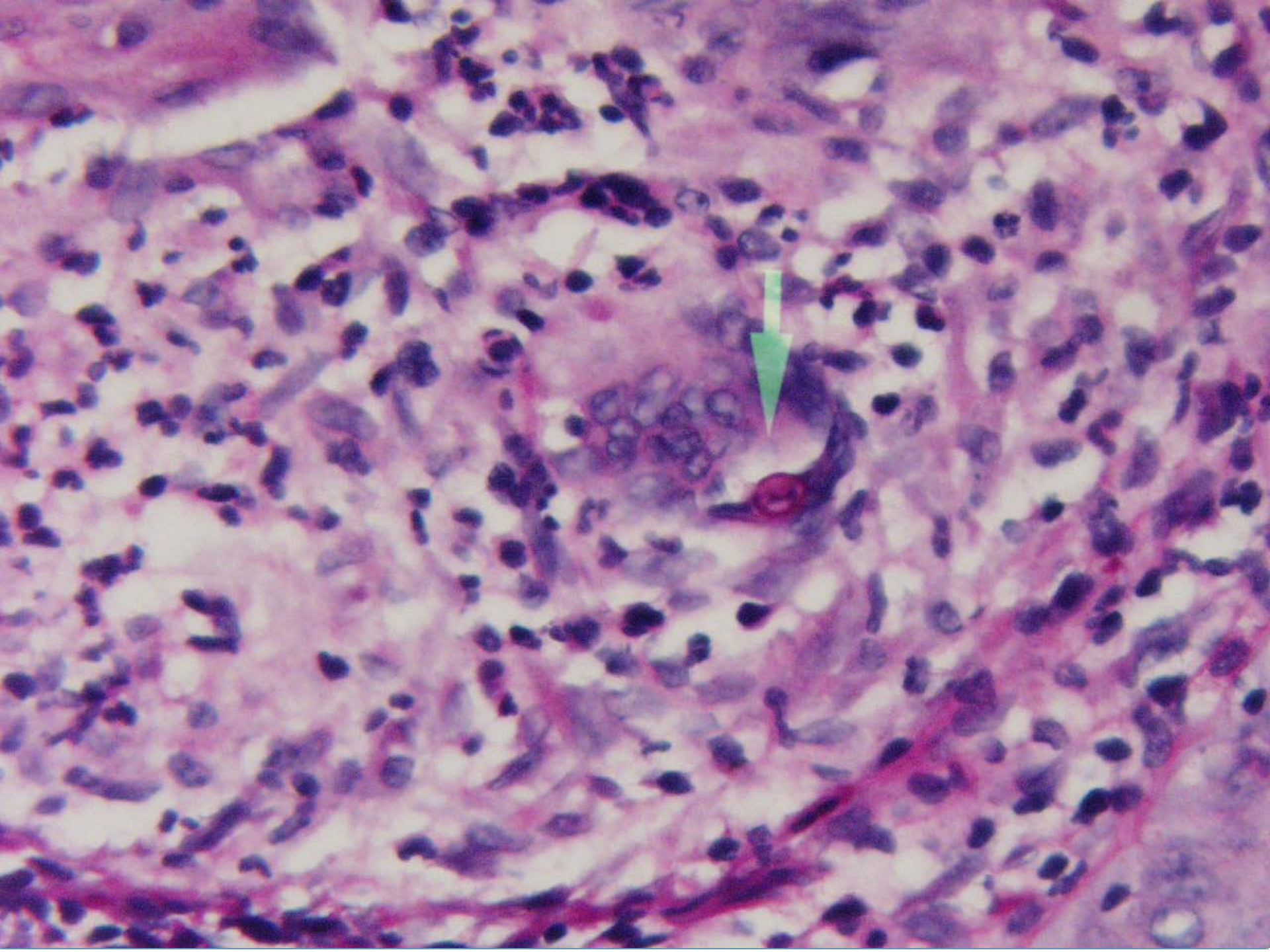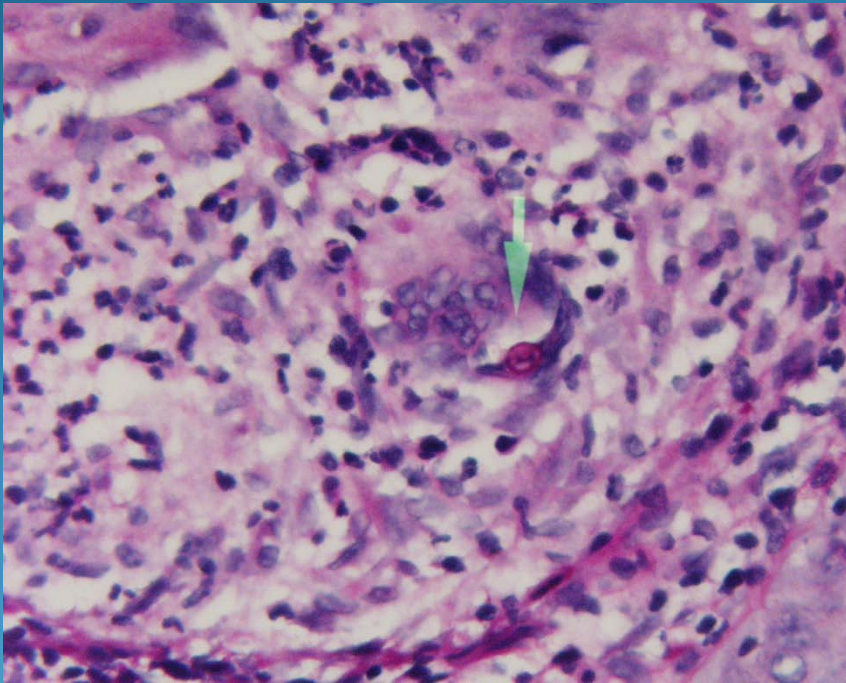


Blastomycosis

Pearls



- Verruciform epidermal hyperplasia resembling squamous cell carcinoma
- Suppurative granulomas within the epidermis and dermis
- Giant cells containing fungal organisms