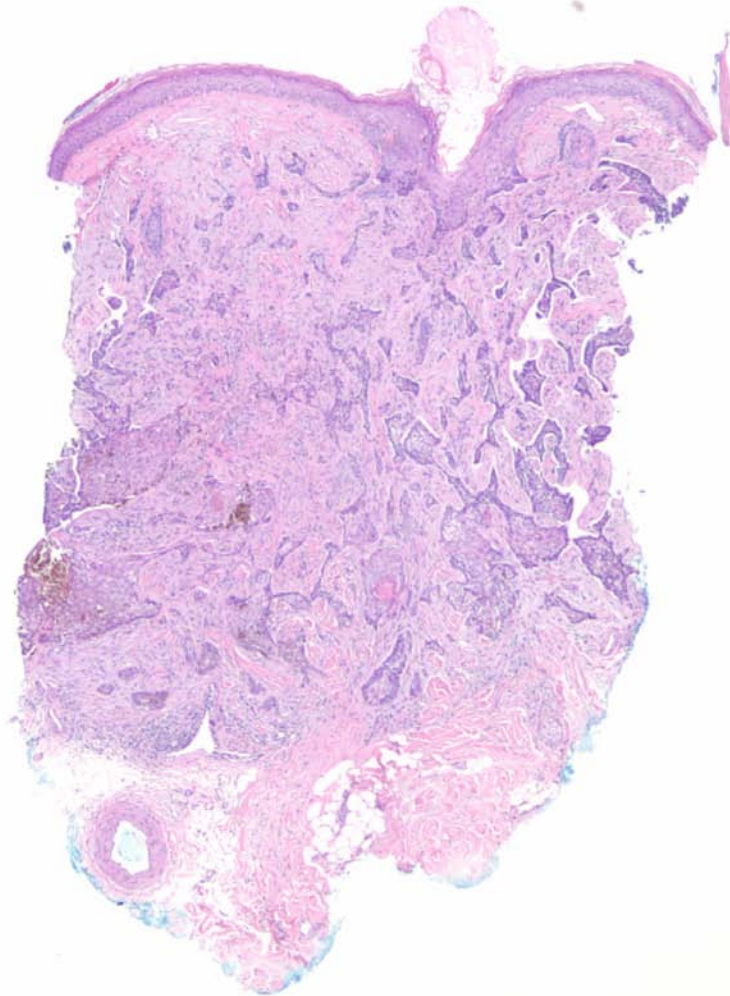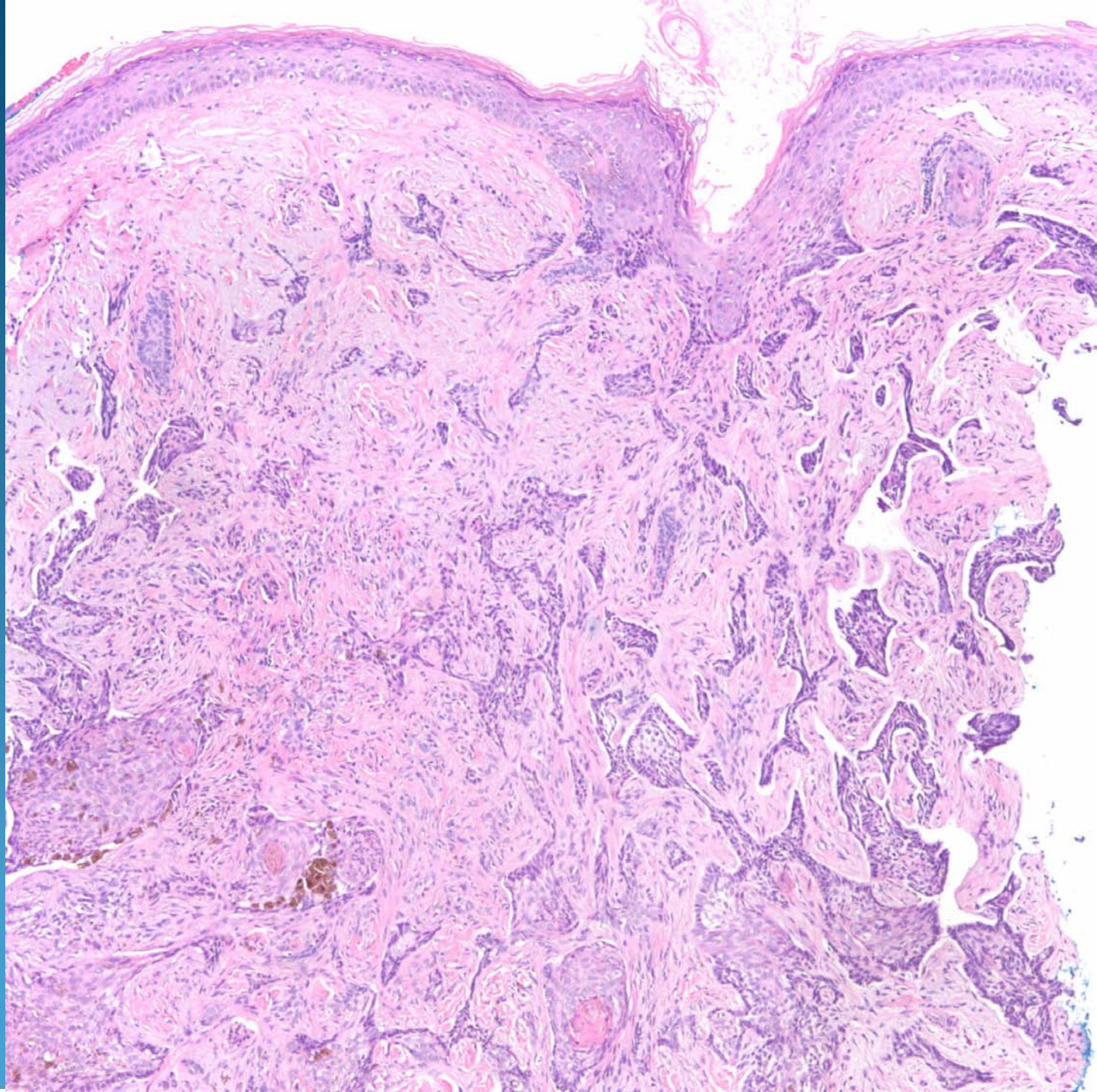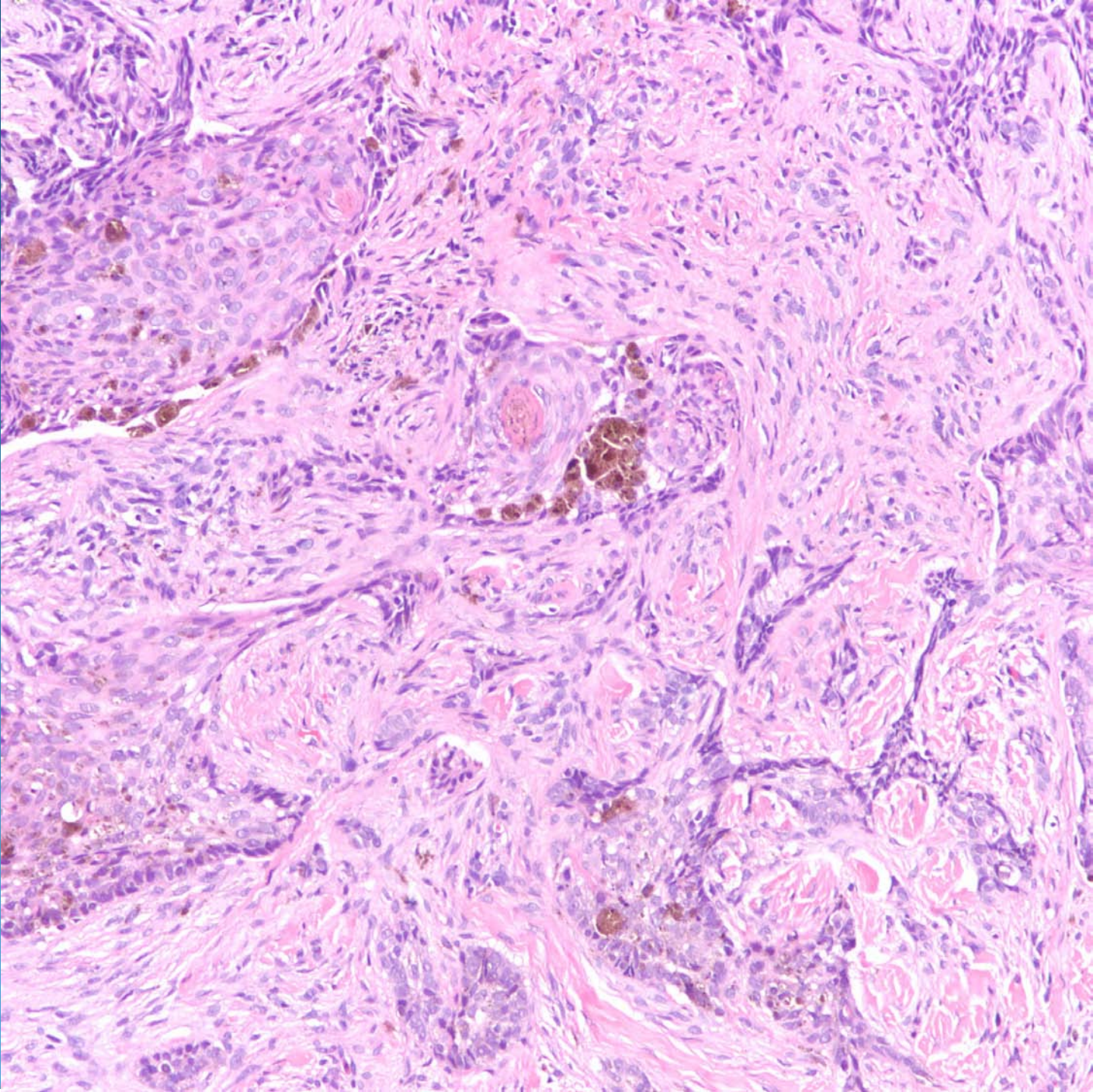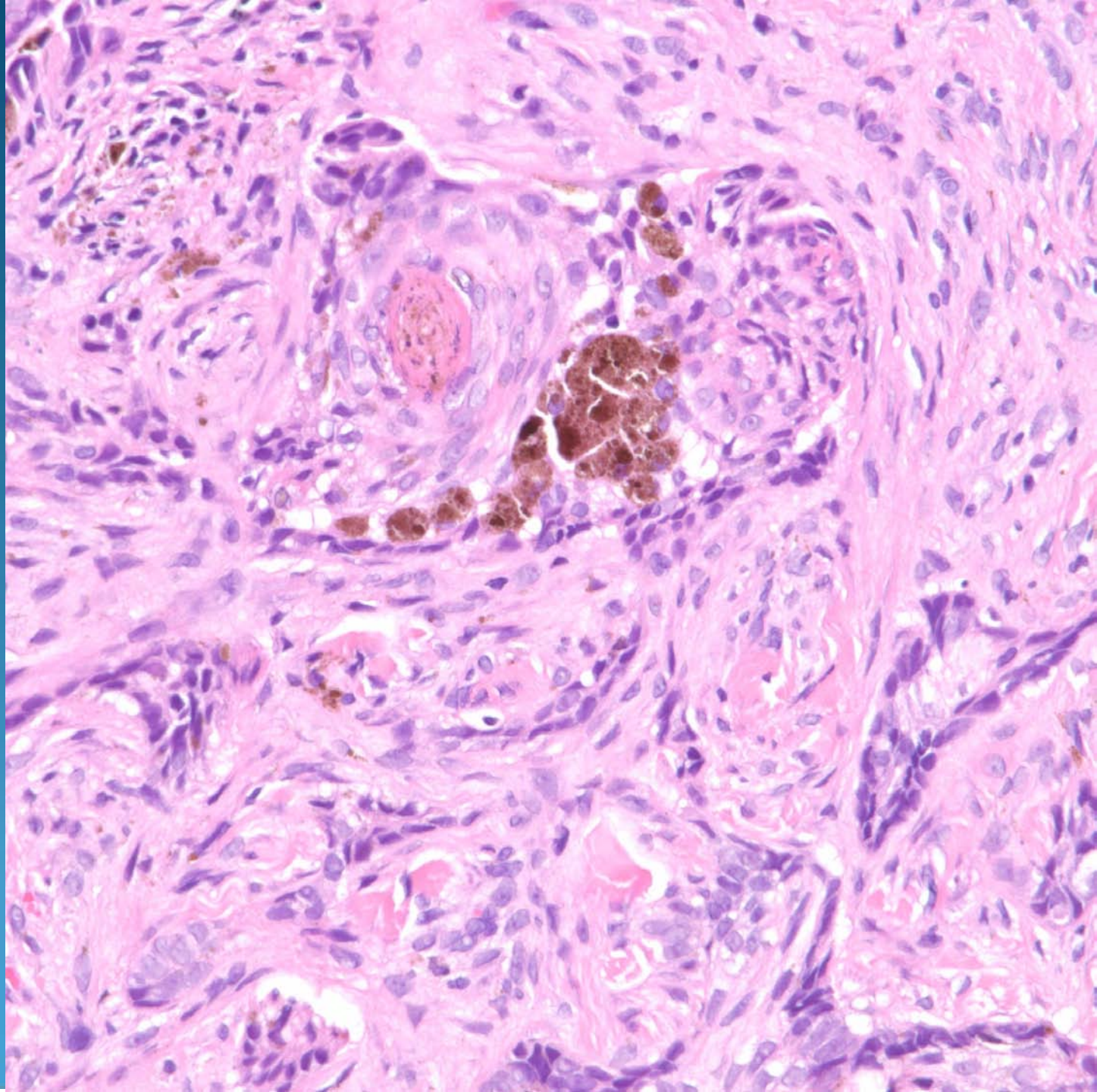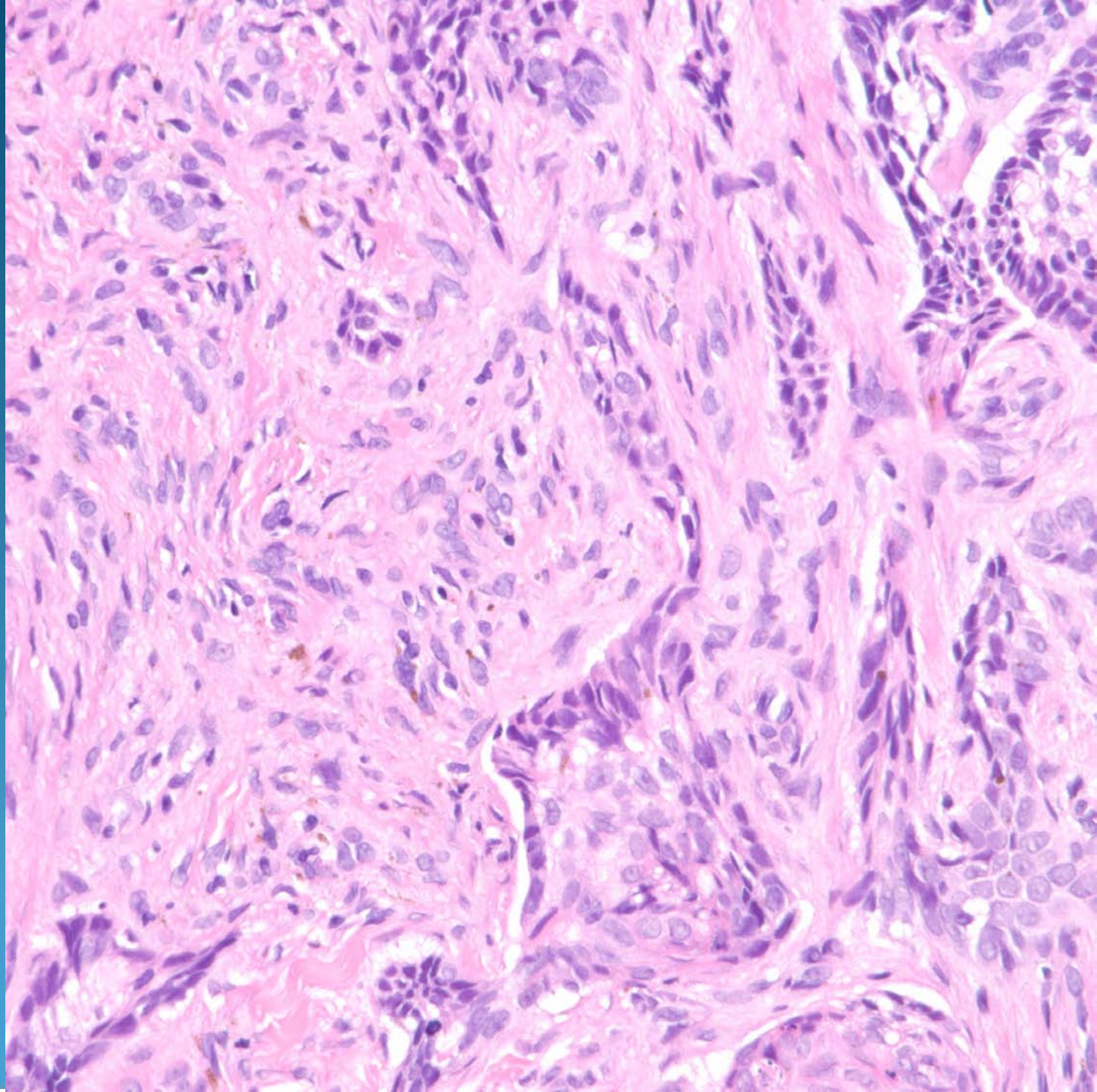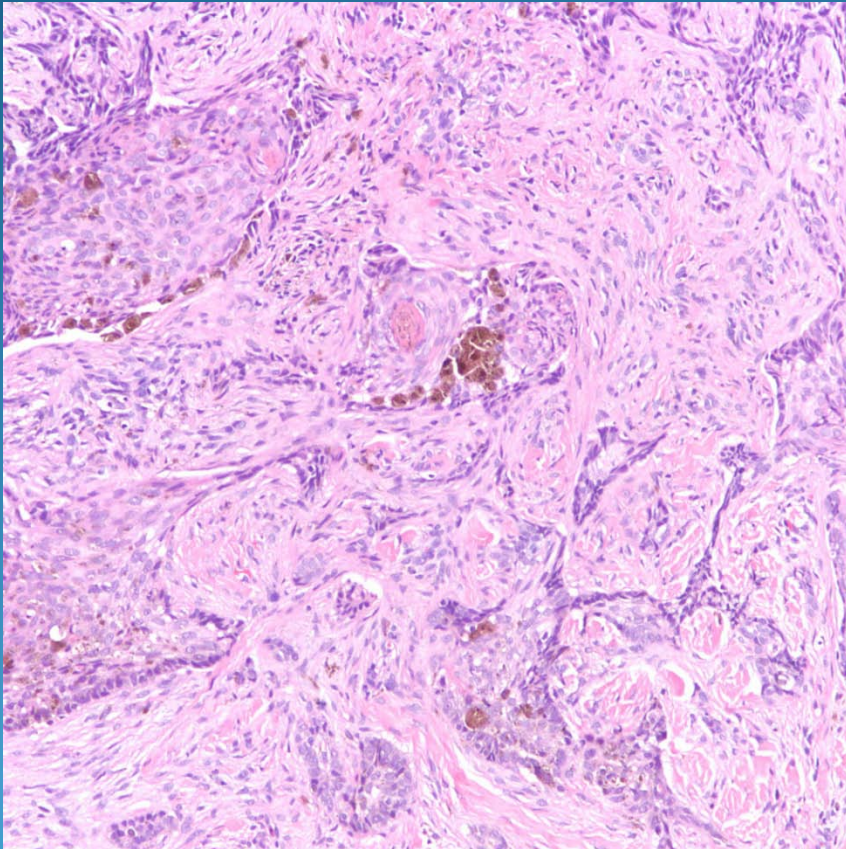


Sclerosing Basal Cell Carcinoma, Pigmented Type

Pearls



- Angular spiky nests of basaloid cells with desmoplastic stroma
- Look for melanin pigment within and adjacent to epithelial nests
- Relatively uncommon variant of basal cell carcinoma to be pigmented, most common is nodular BCC.