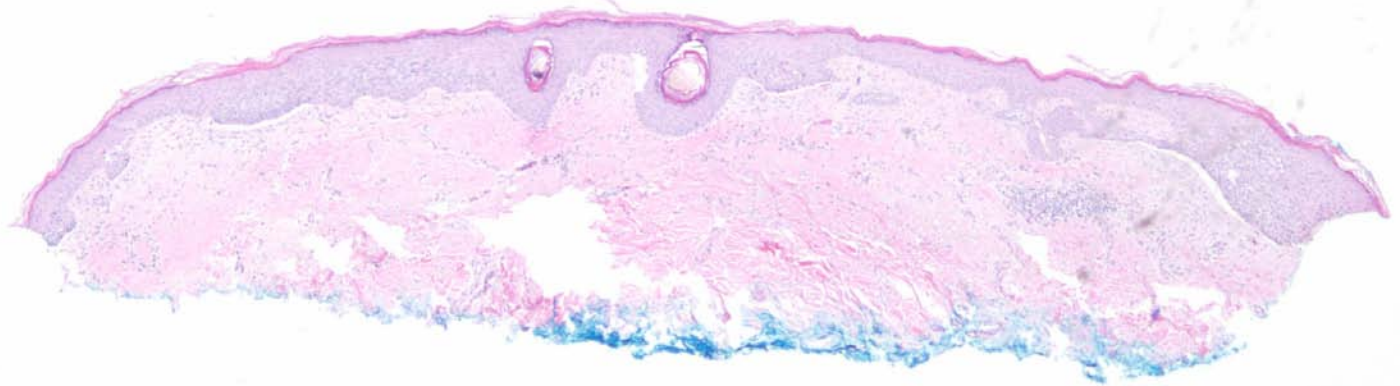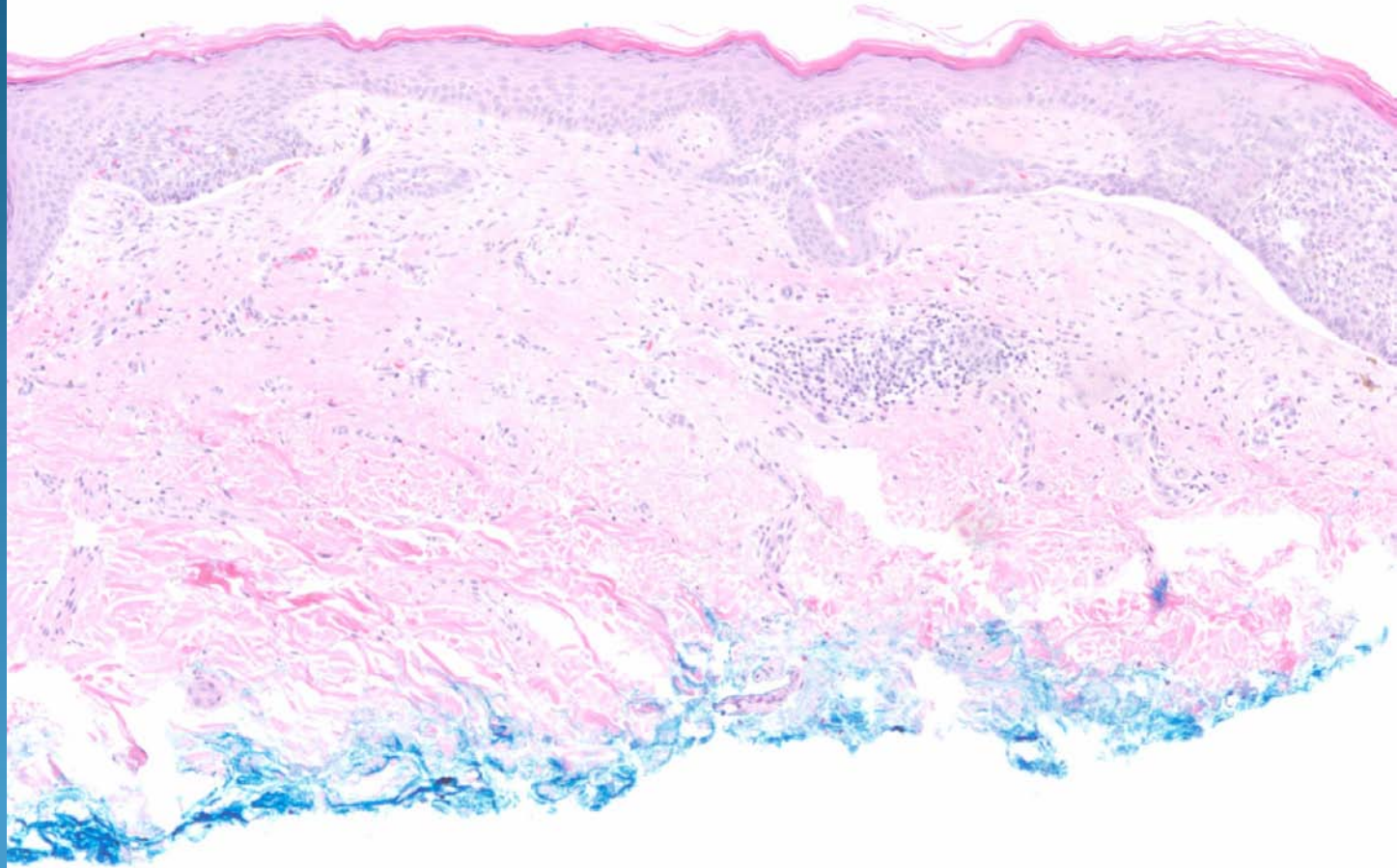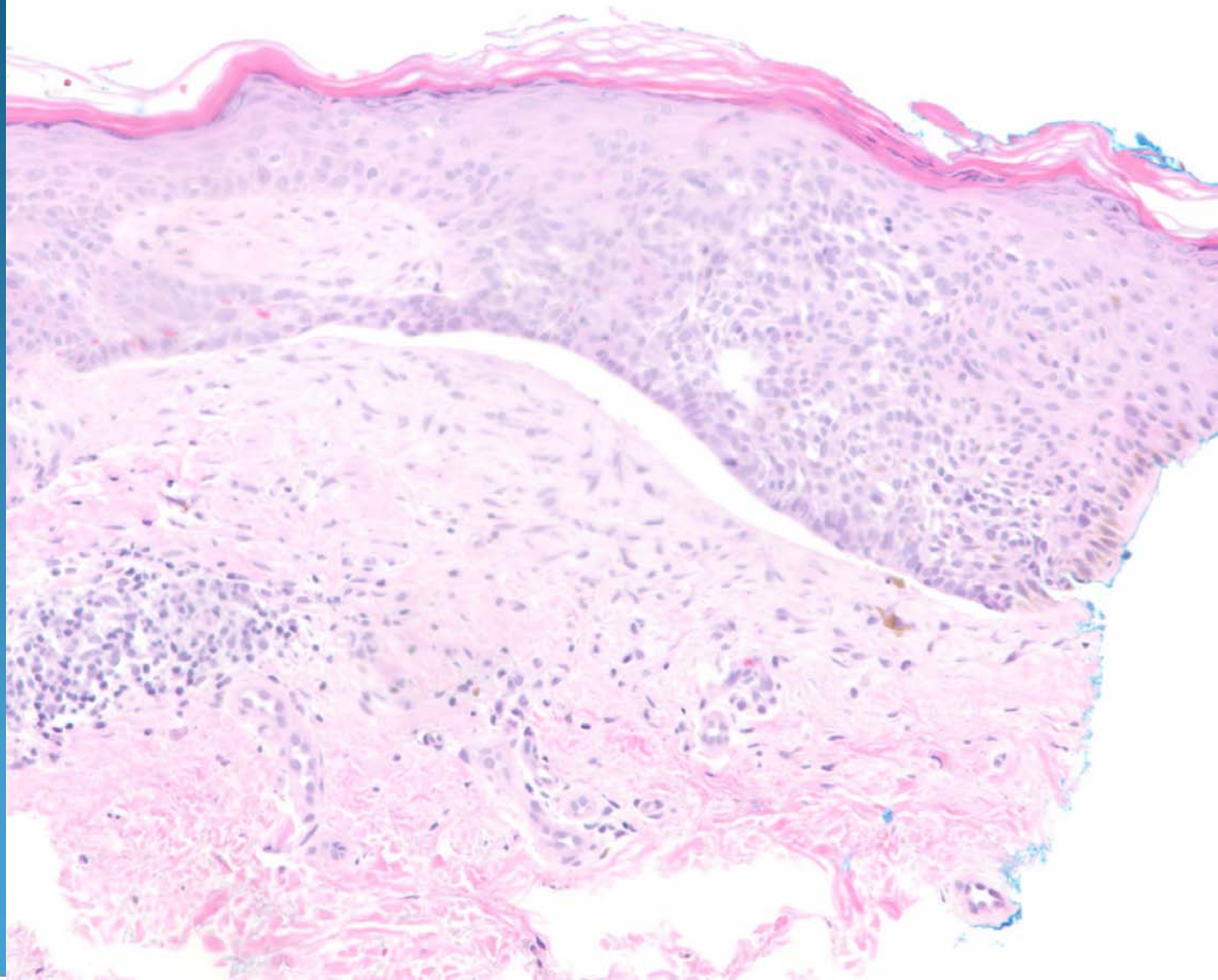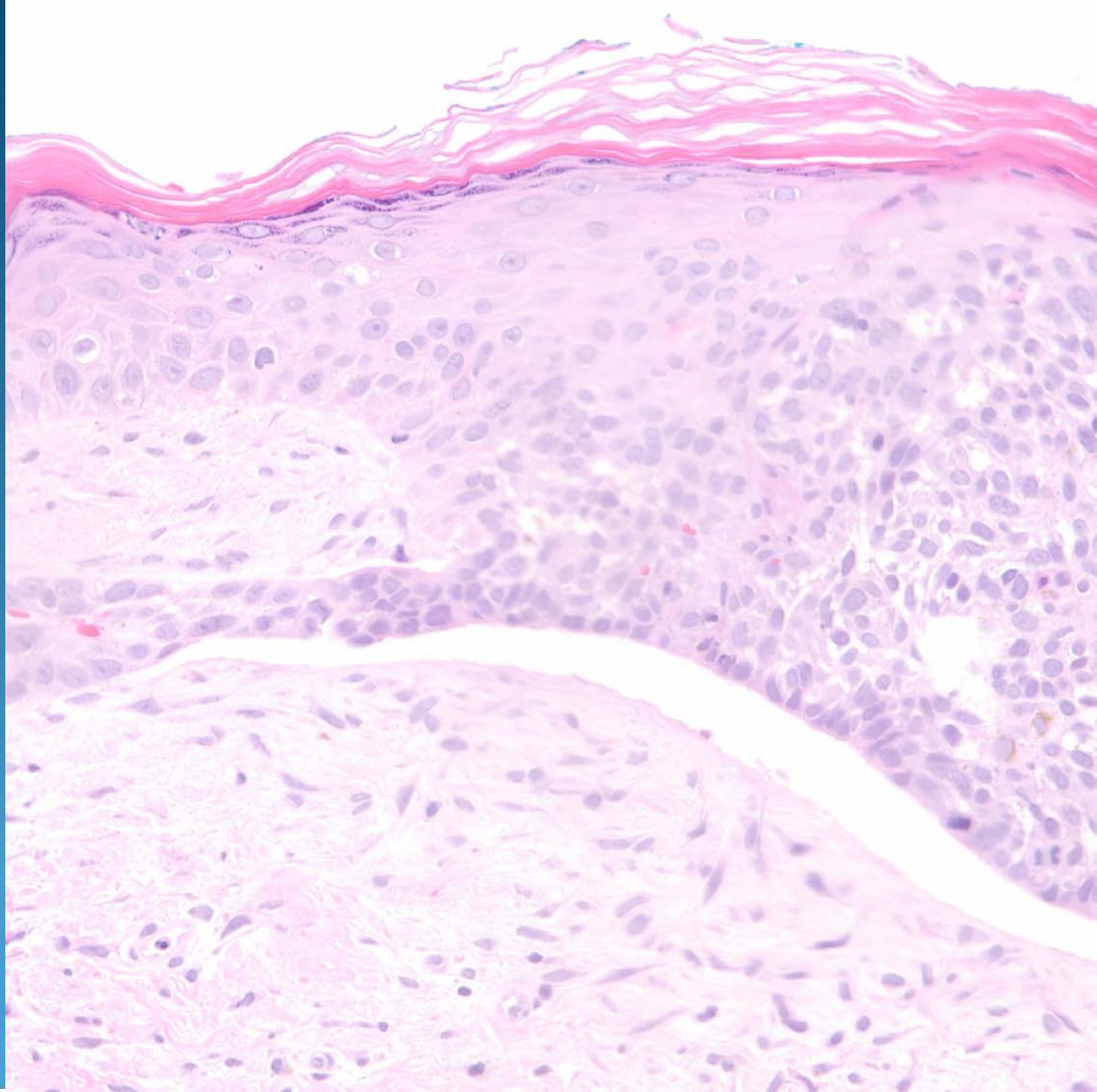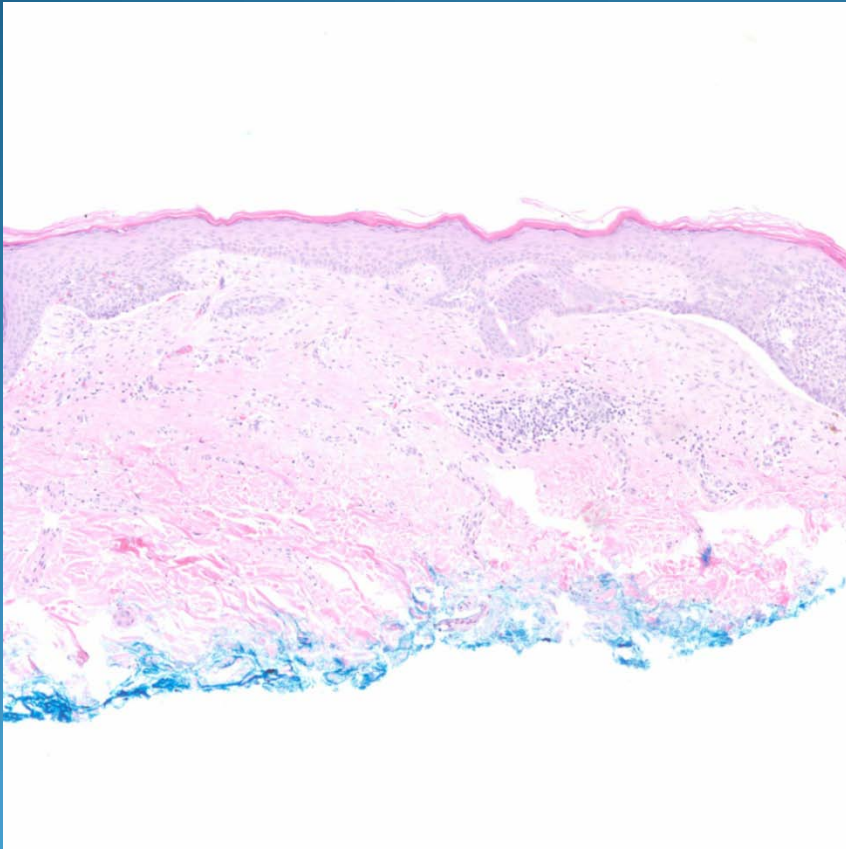


# Basal Cell Carcinoma, Superficial Multifocal Type

# Pearls



- Basaloid nests attached to undersurface of epidermis
- Look for peripheral palisading
- Look for stroma-tumor clefting