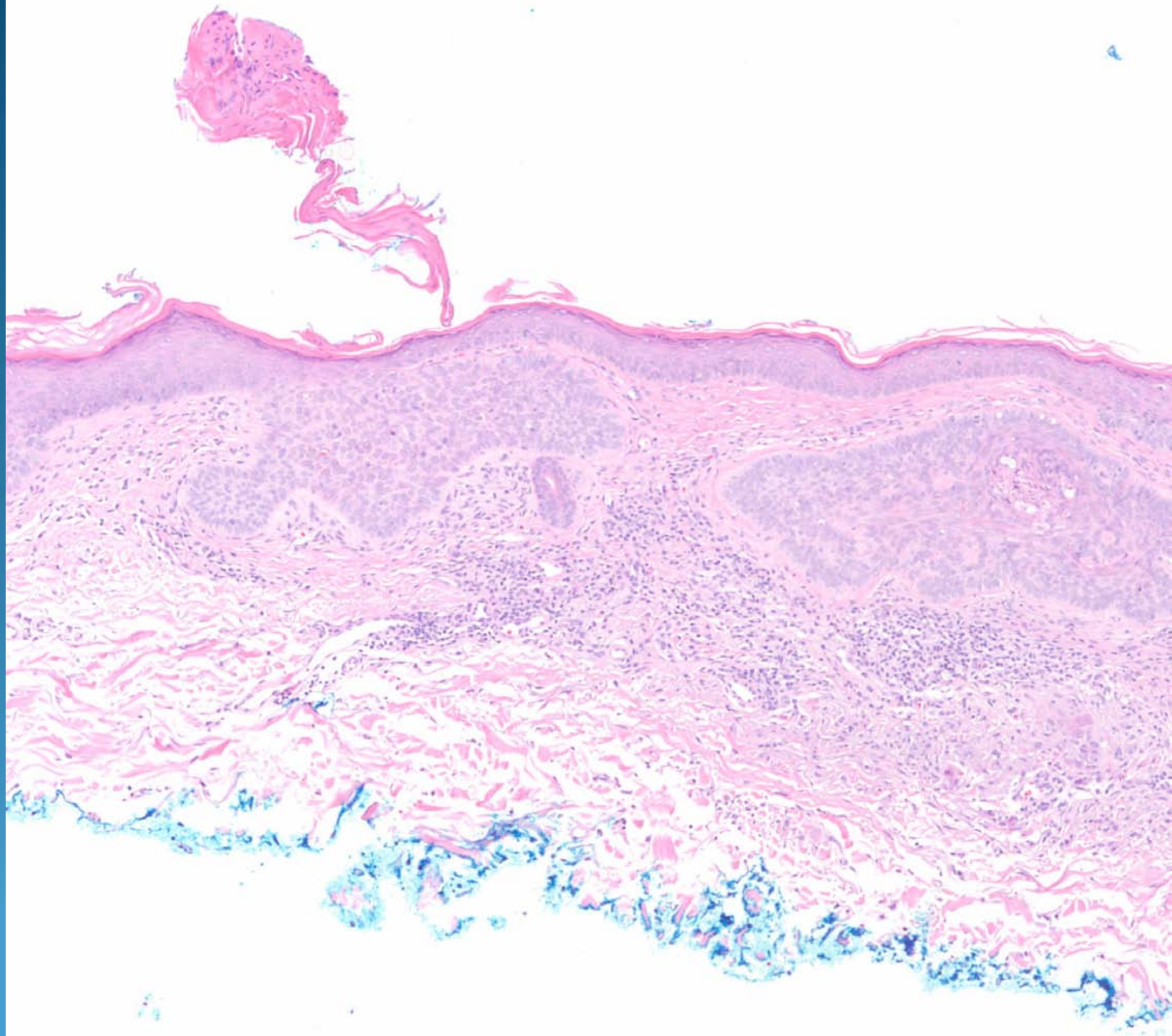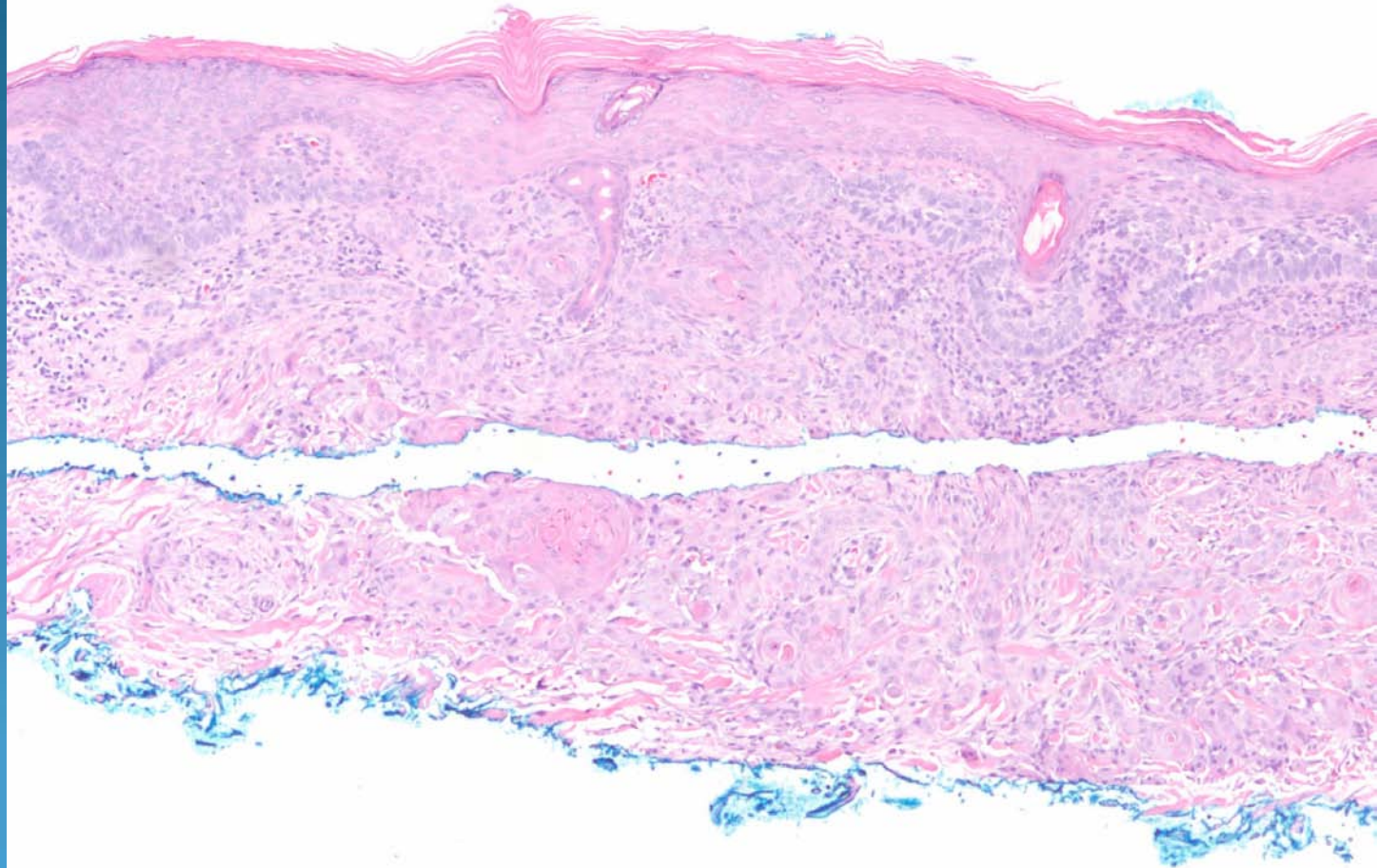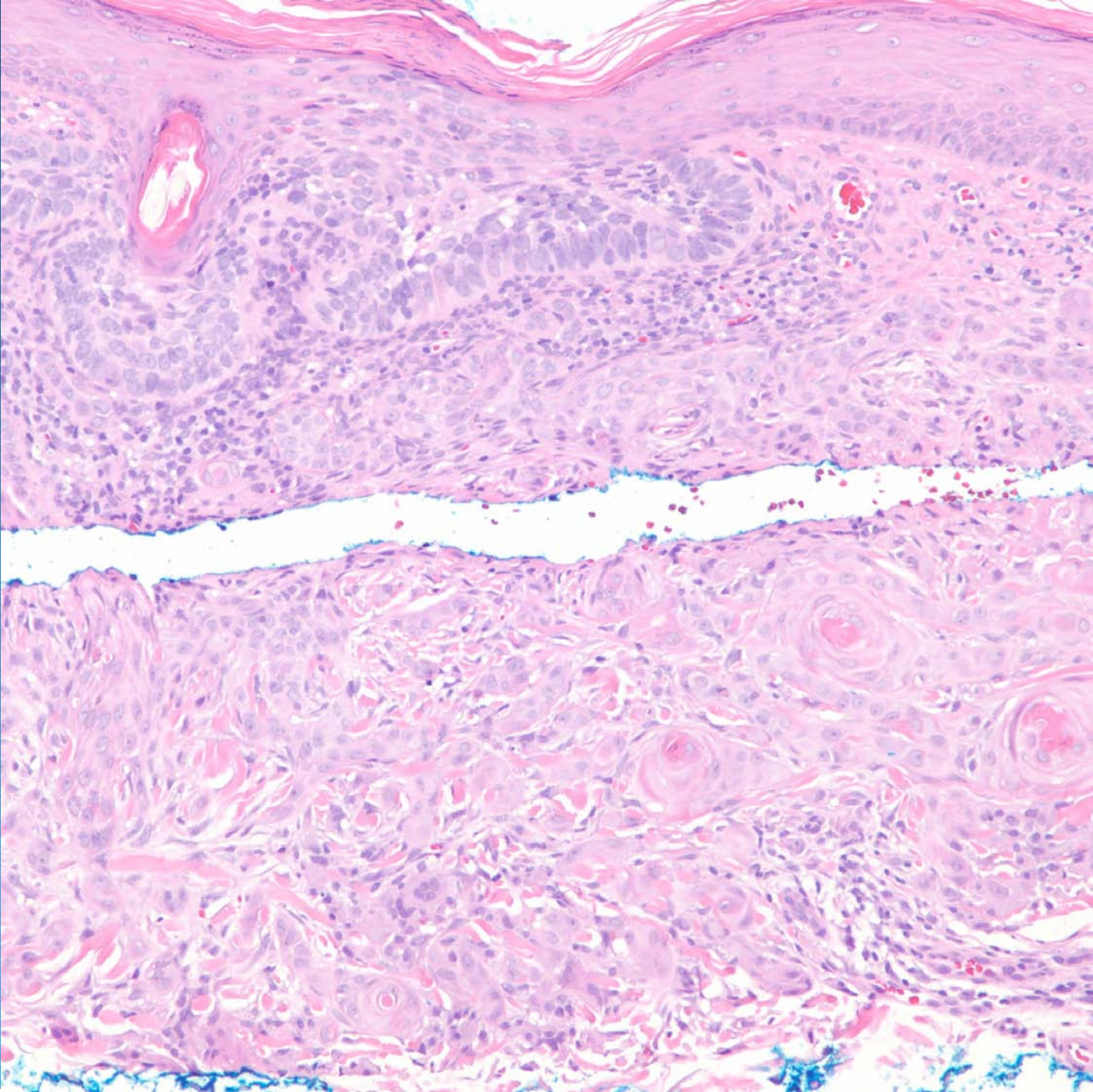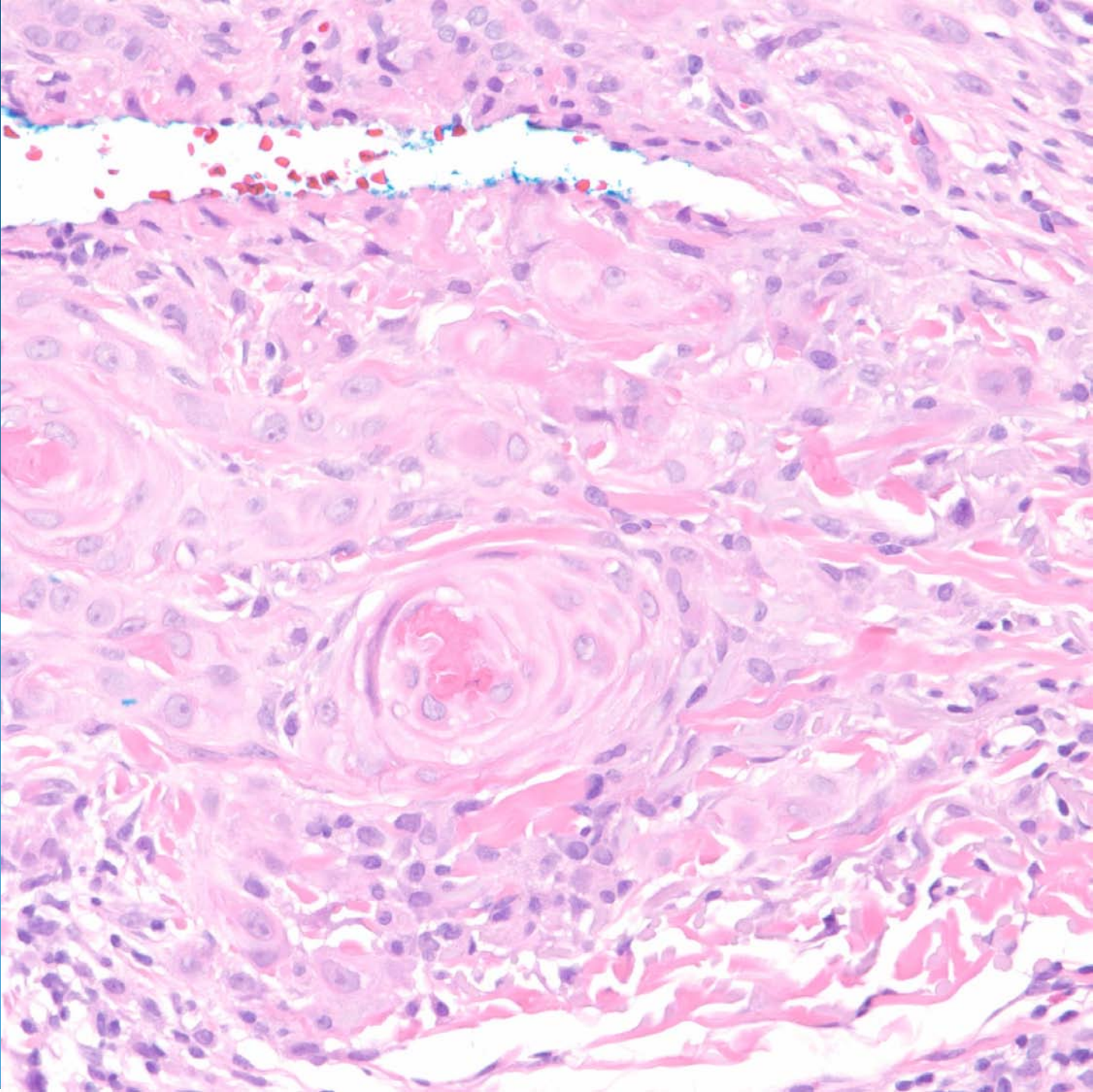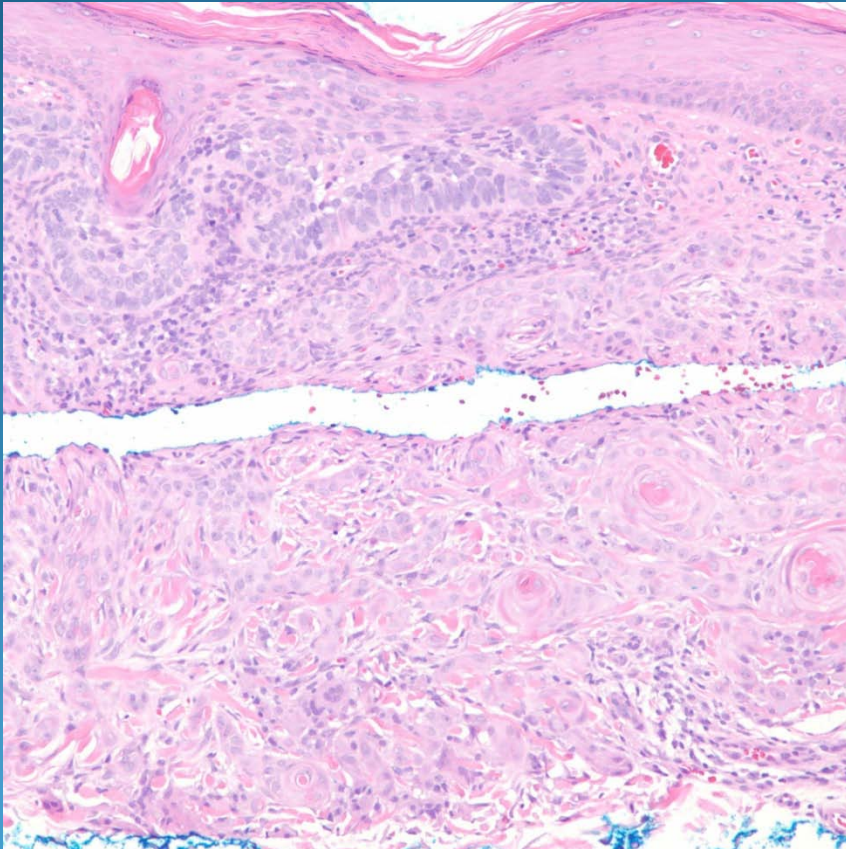


Basal Cell Carcinoma Arising in Association with a Squamous Cell Carcinoma

Pearls



- Should have 2 clearly distinct tumors with no transitional forms
- Should have typical squamous pearl formation for SCC if well differentiated
- BCC morphology dependent upon the type