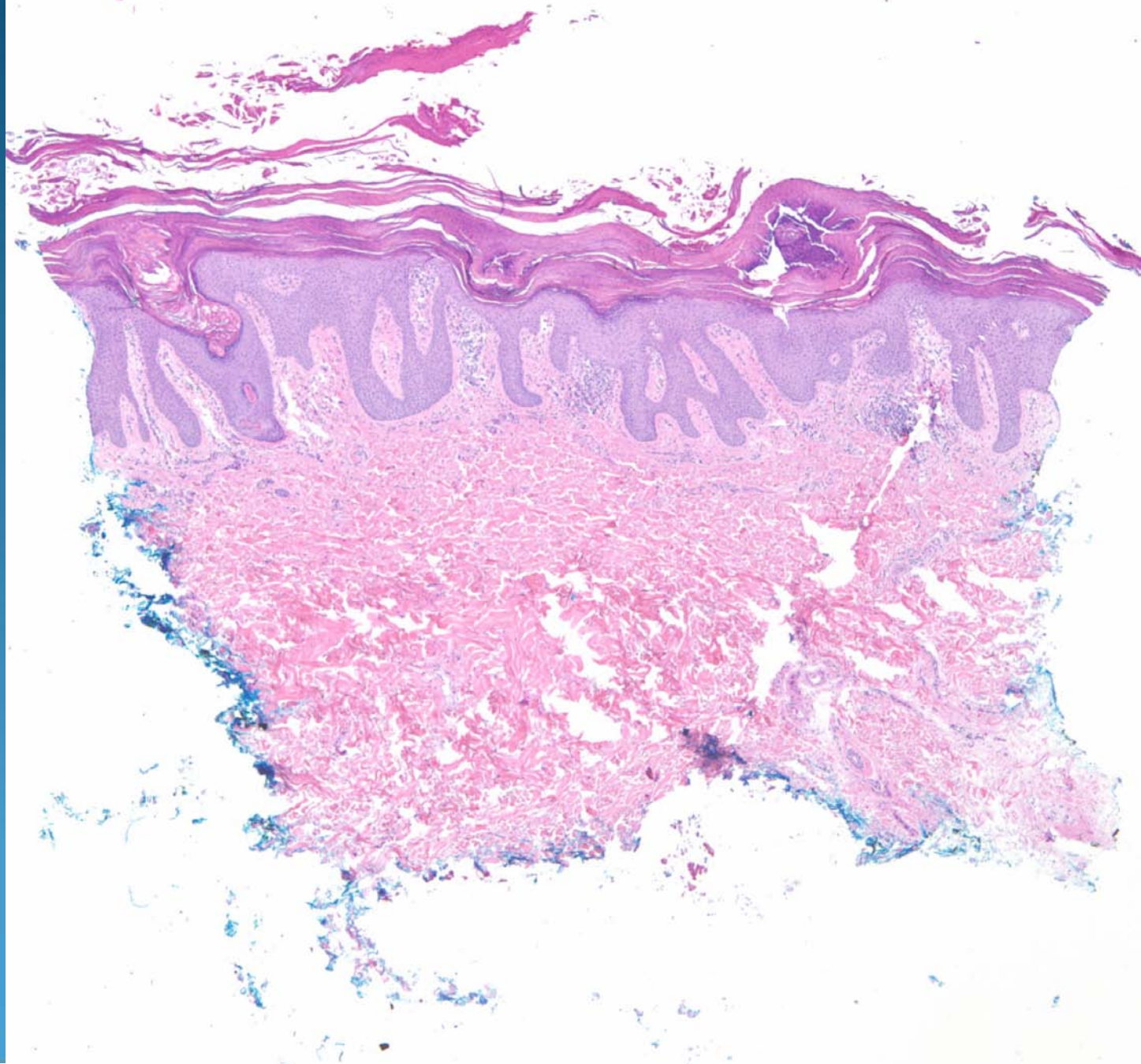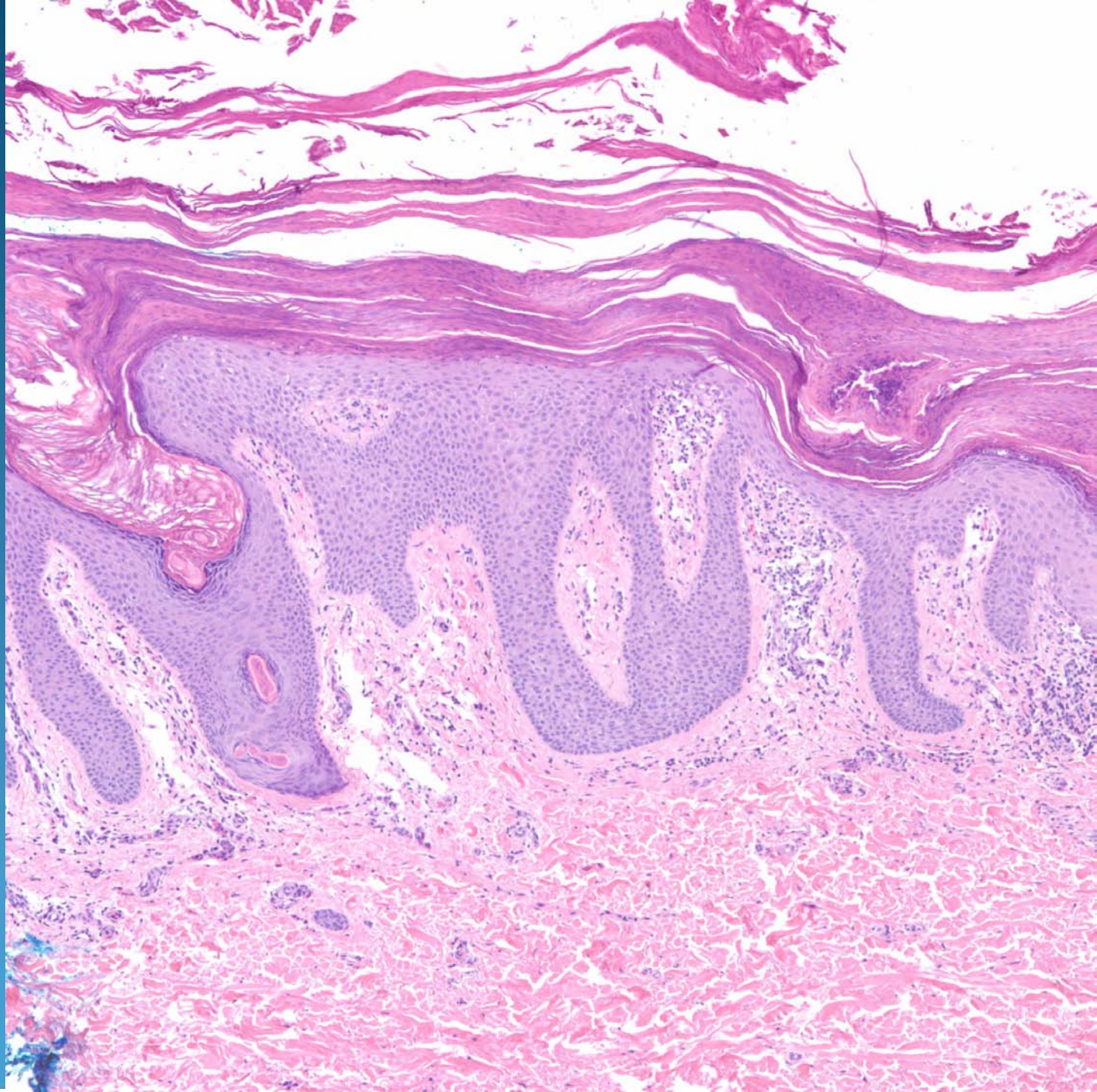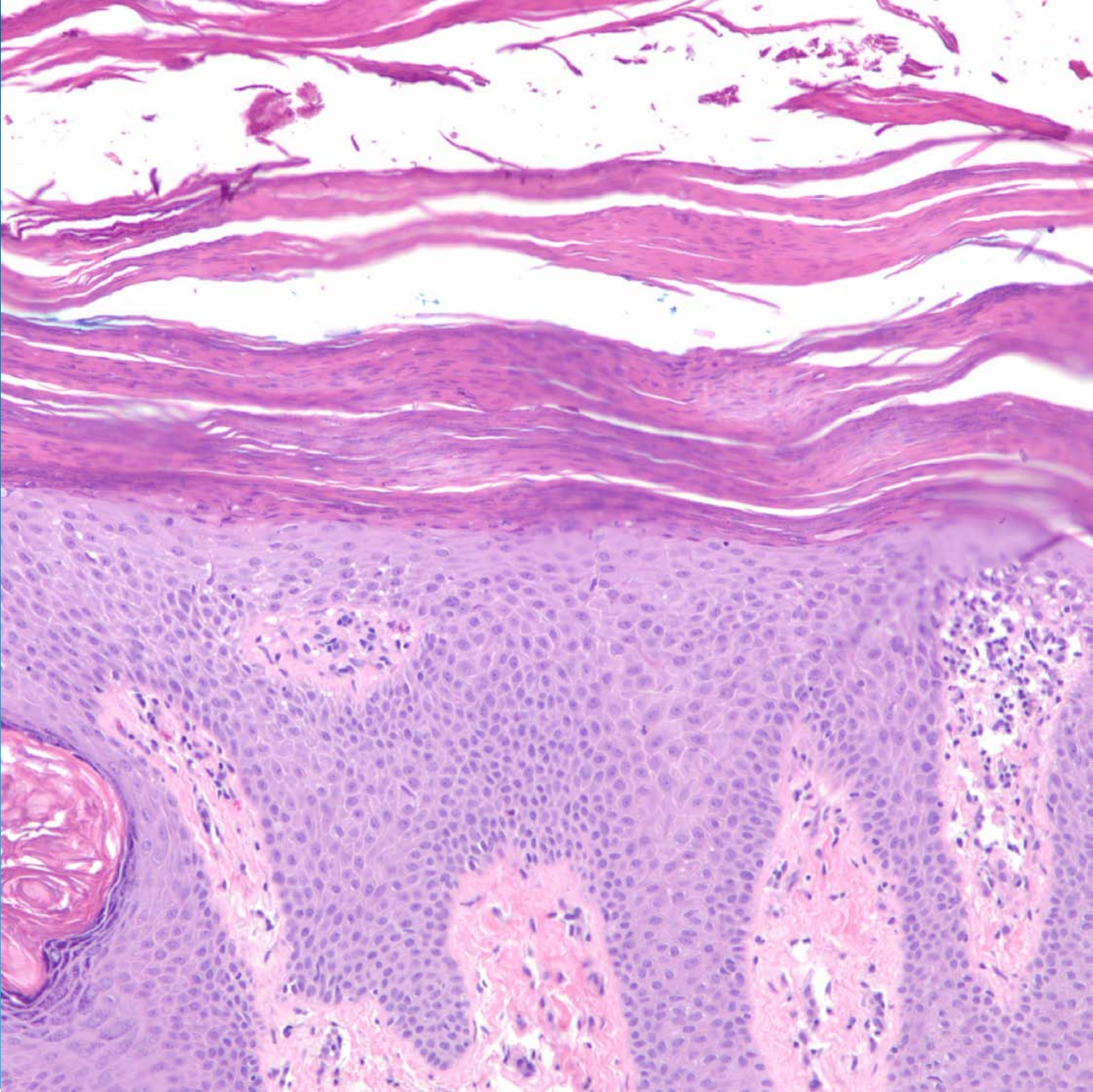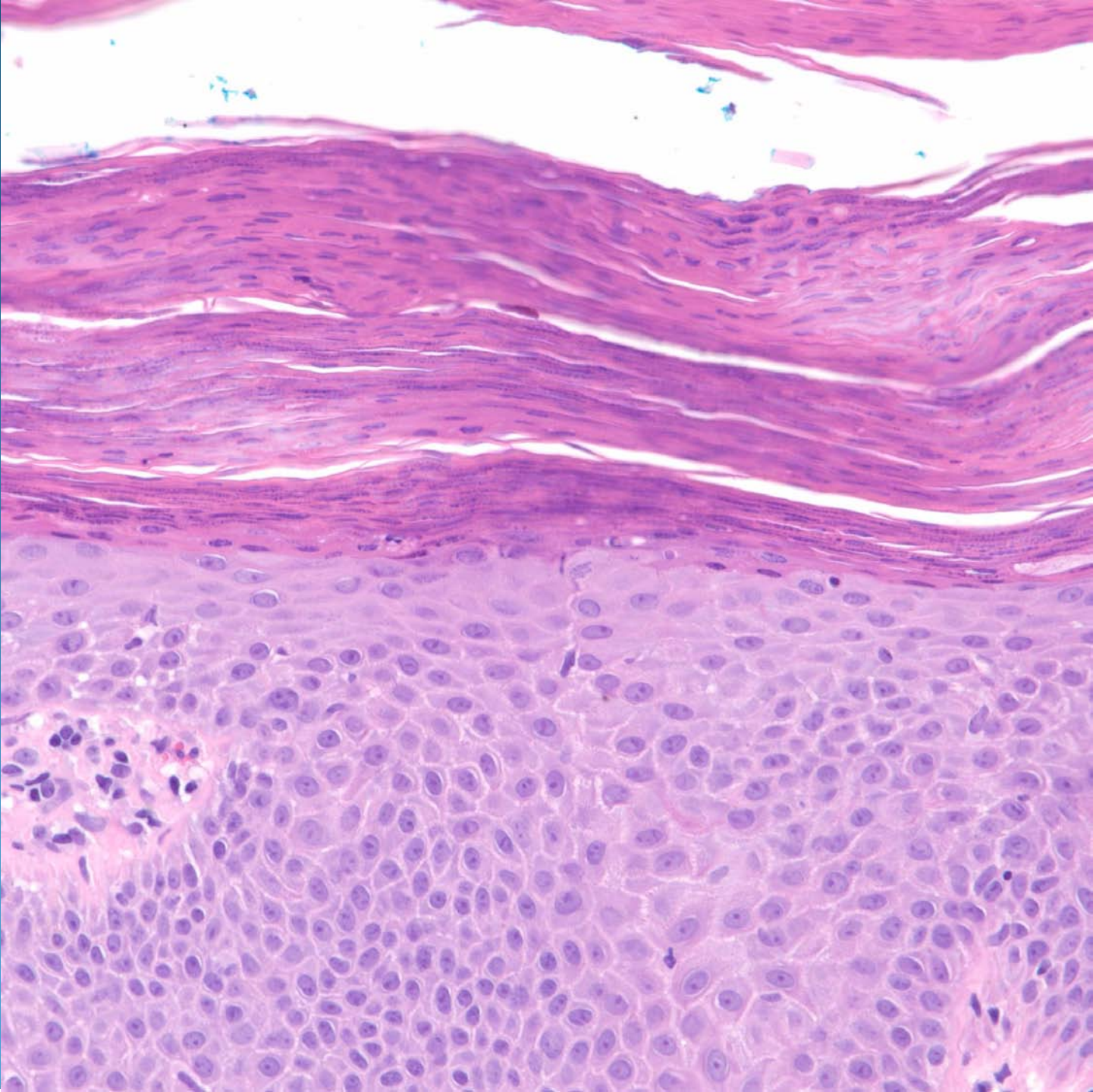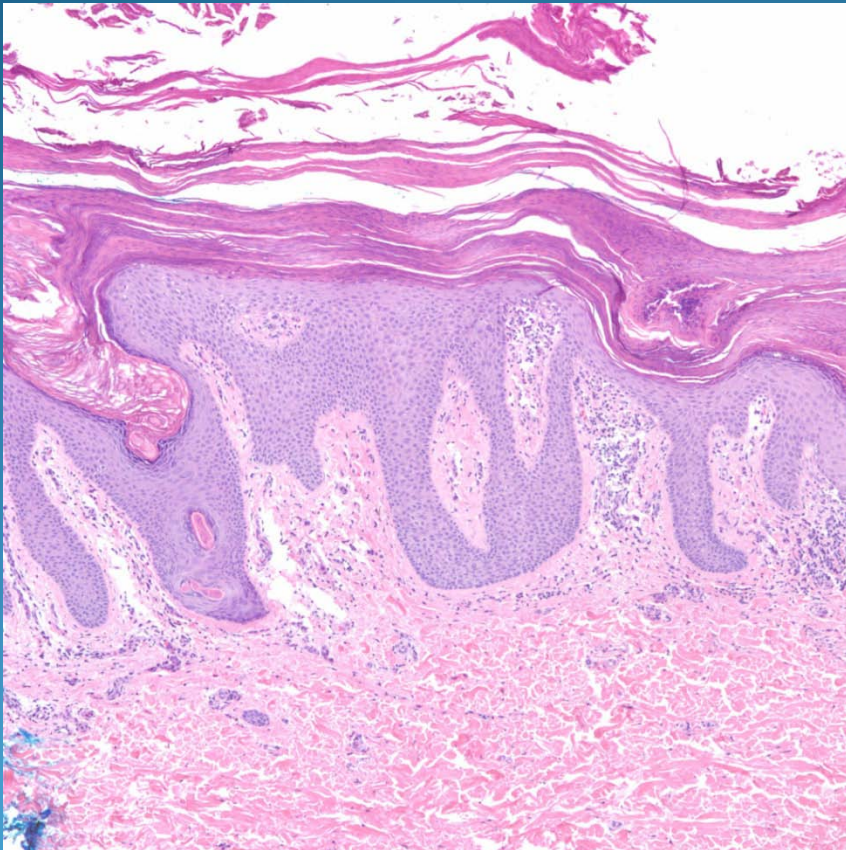


Axillary Granular Parakeratosis

Pearls



- Pronounced hyper- and parakeratotic scale without hypergranulosis
- Psoriasiform epidermal changes
- Clinical-pathological correlation
- DDX: Psoriasis, Pityriasis rubra pilaris