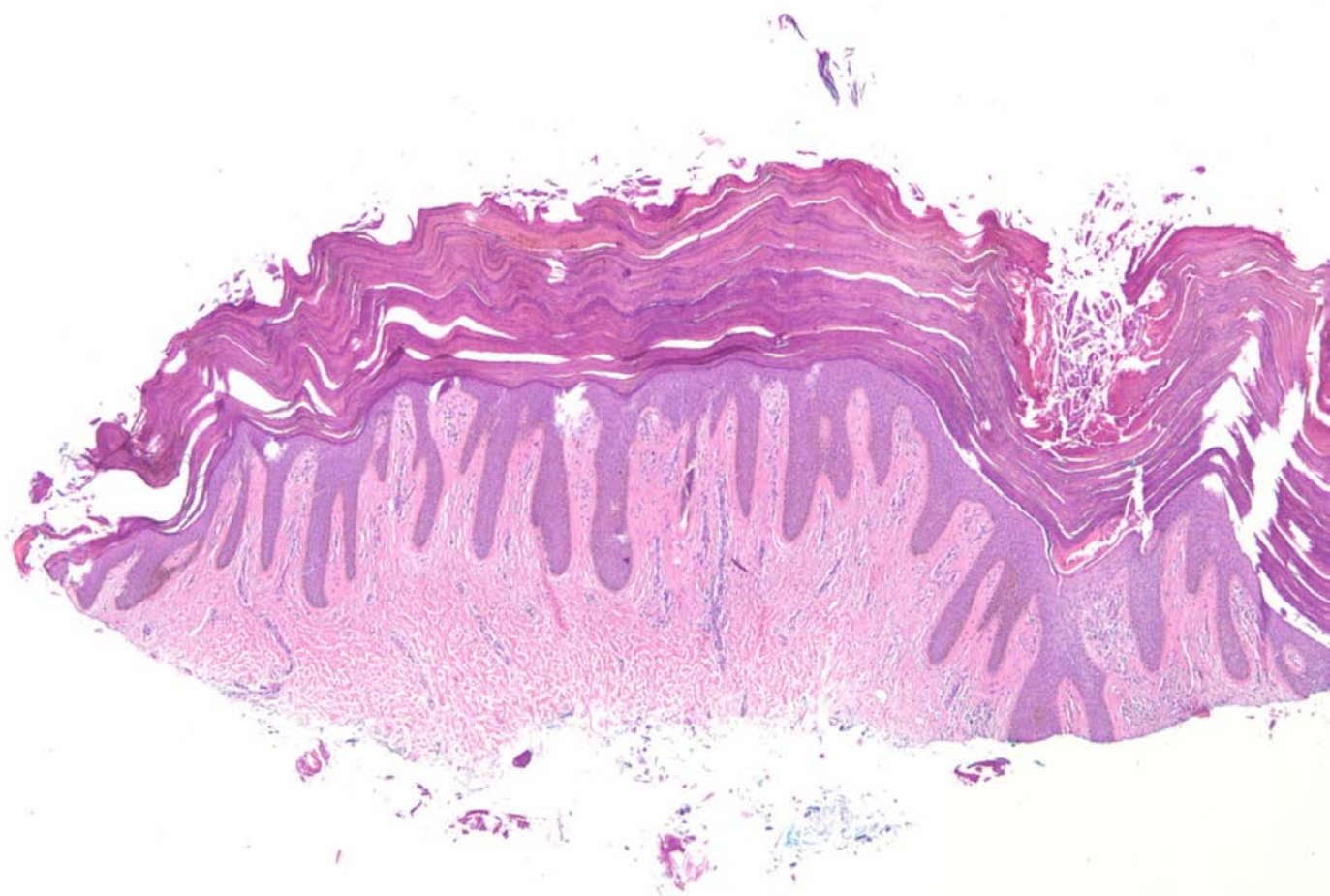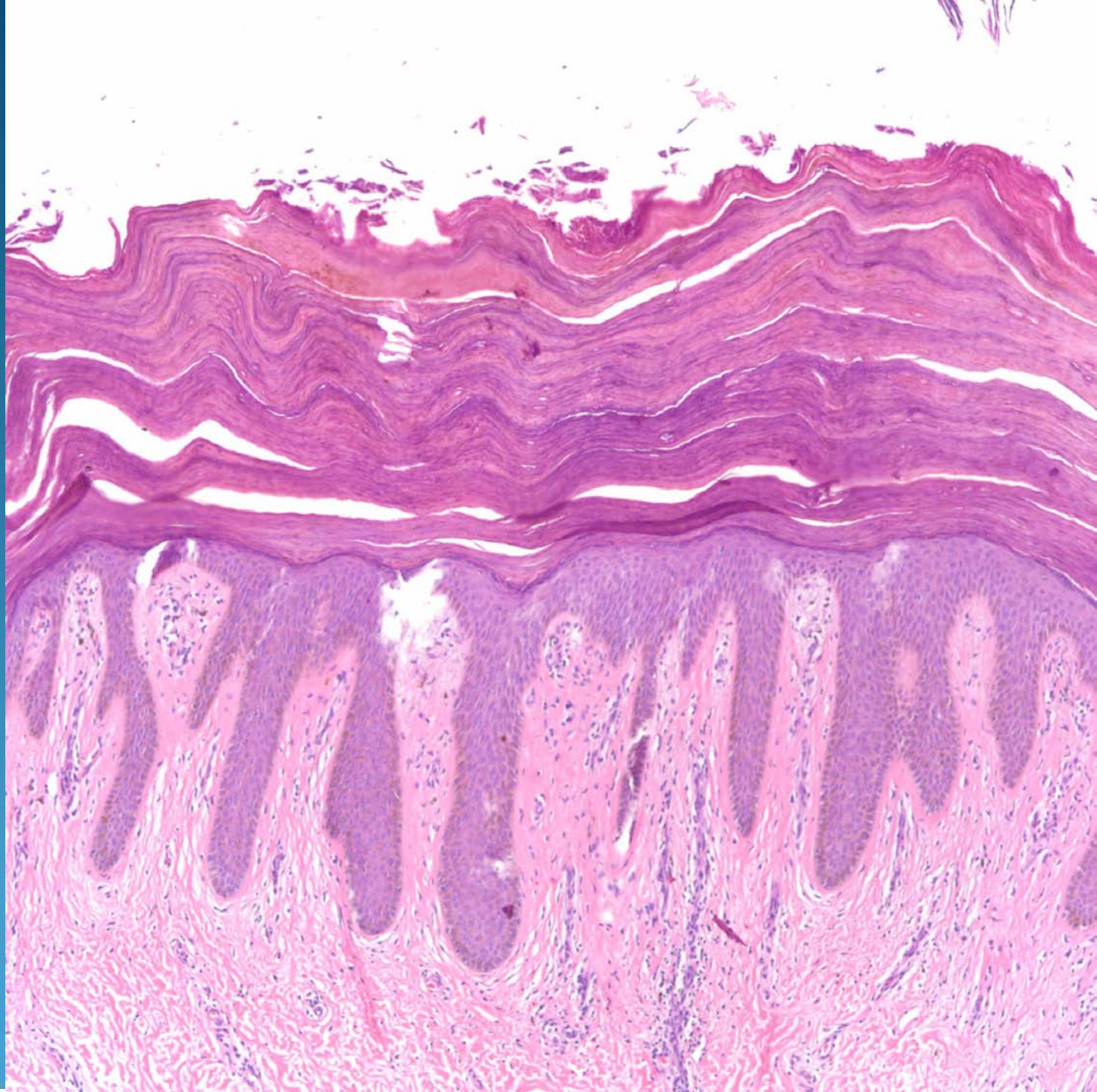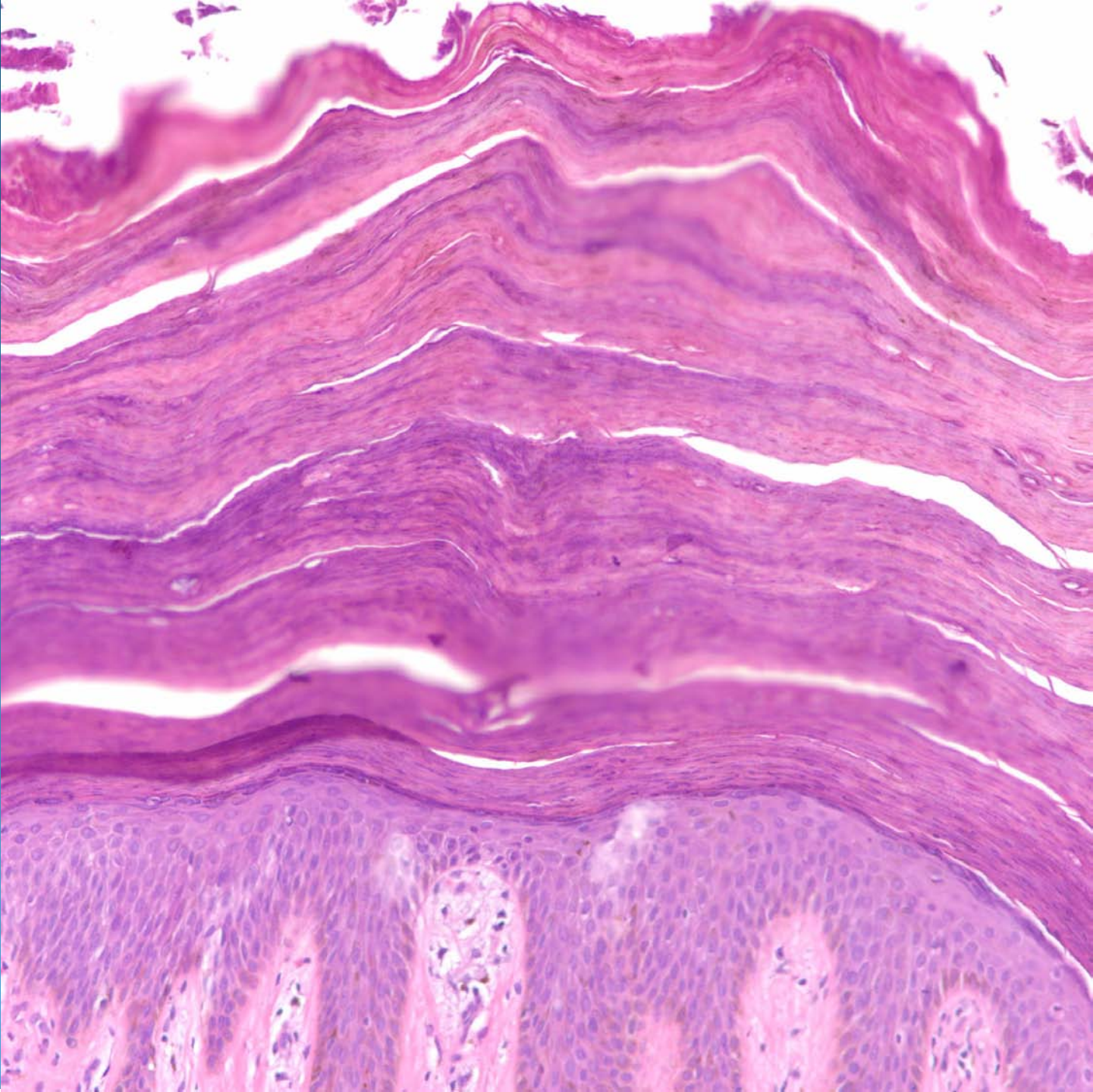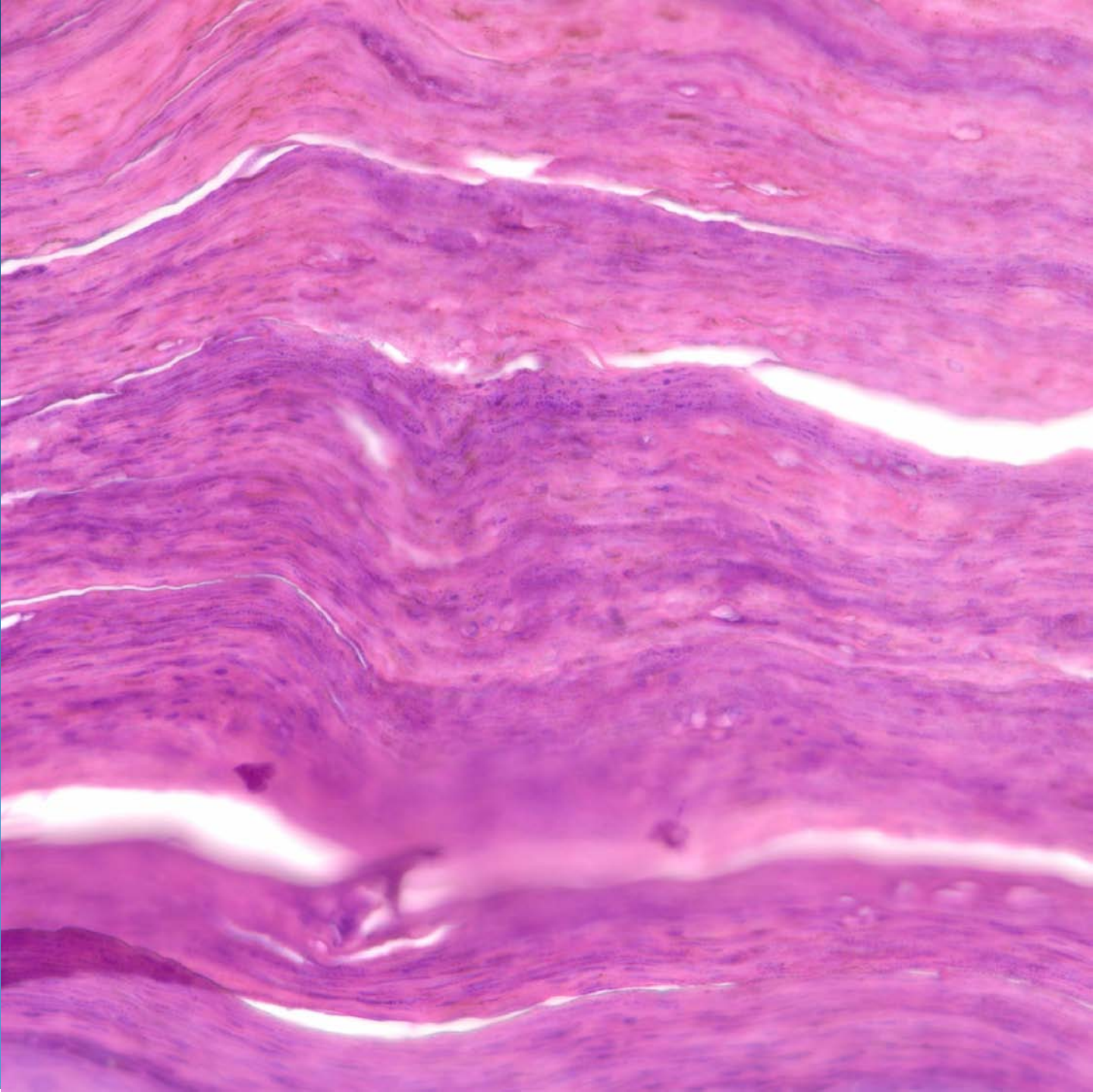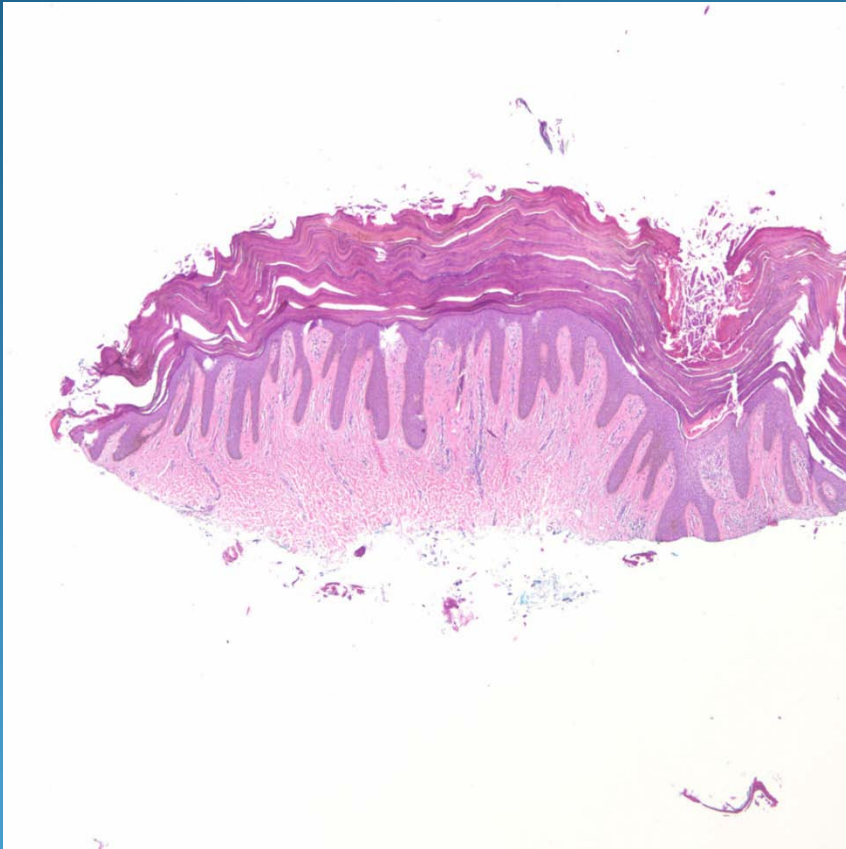


# Axillary Granular Parakeratosis

# Pearls



- Pronounced hyper and parakeratotic scale
- No viral cytopathic changes or dysplasia
- Psoriasiform elongation of rete ridges
- Minimal inflammation
- Clinical correlation with site although there are recent reports of extra-axillary lesions