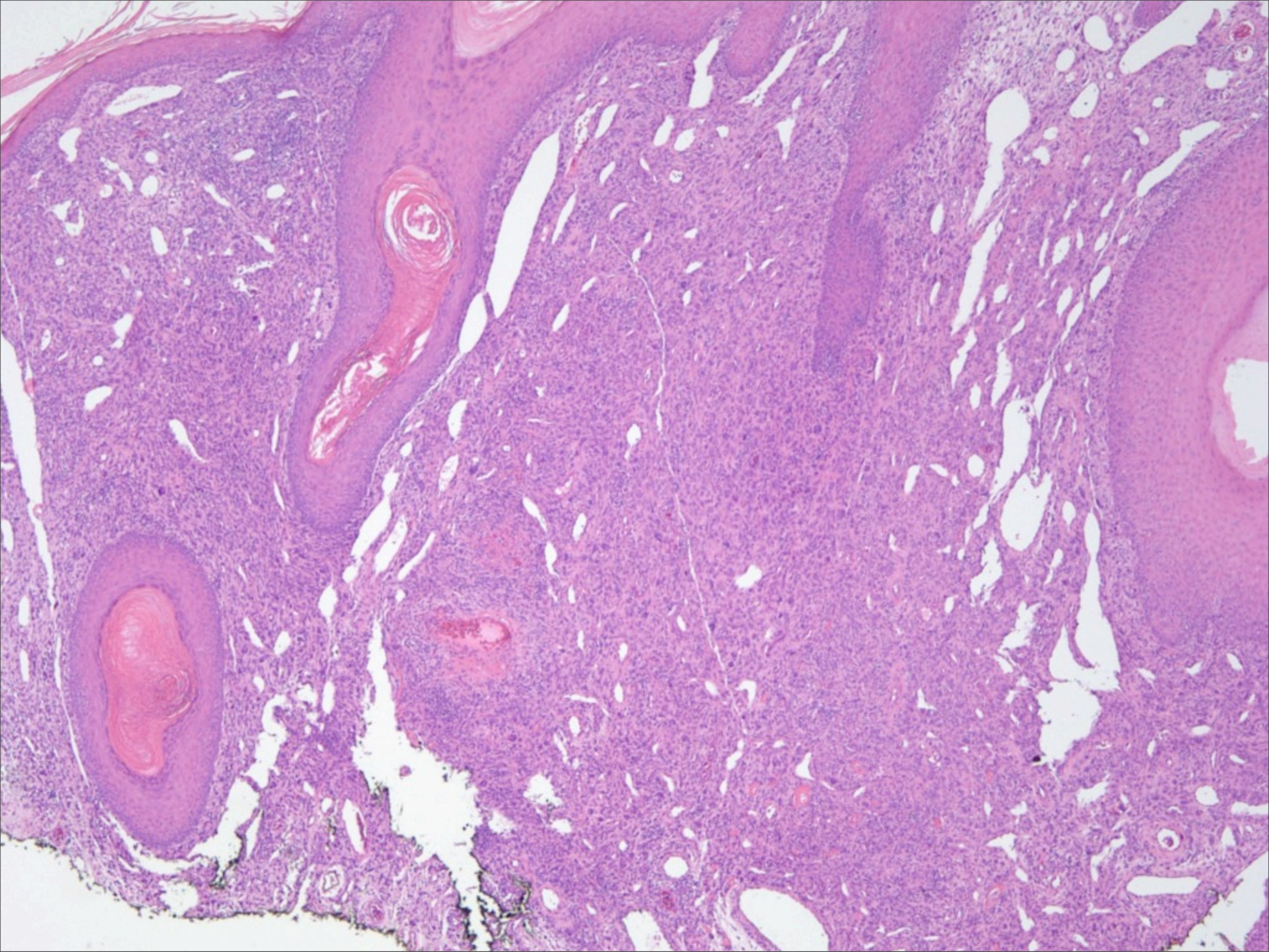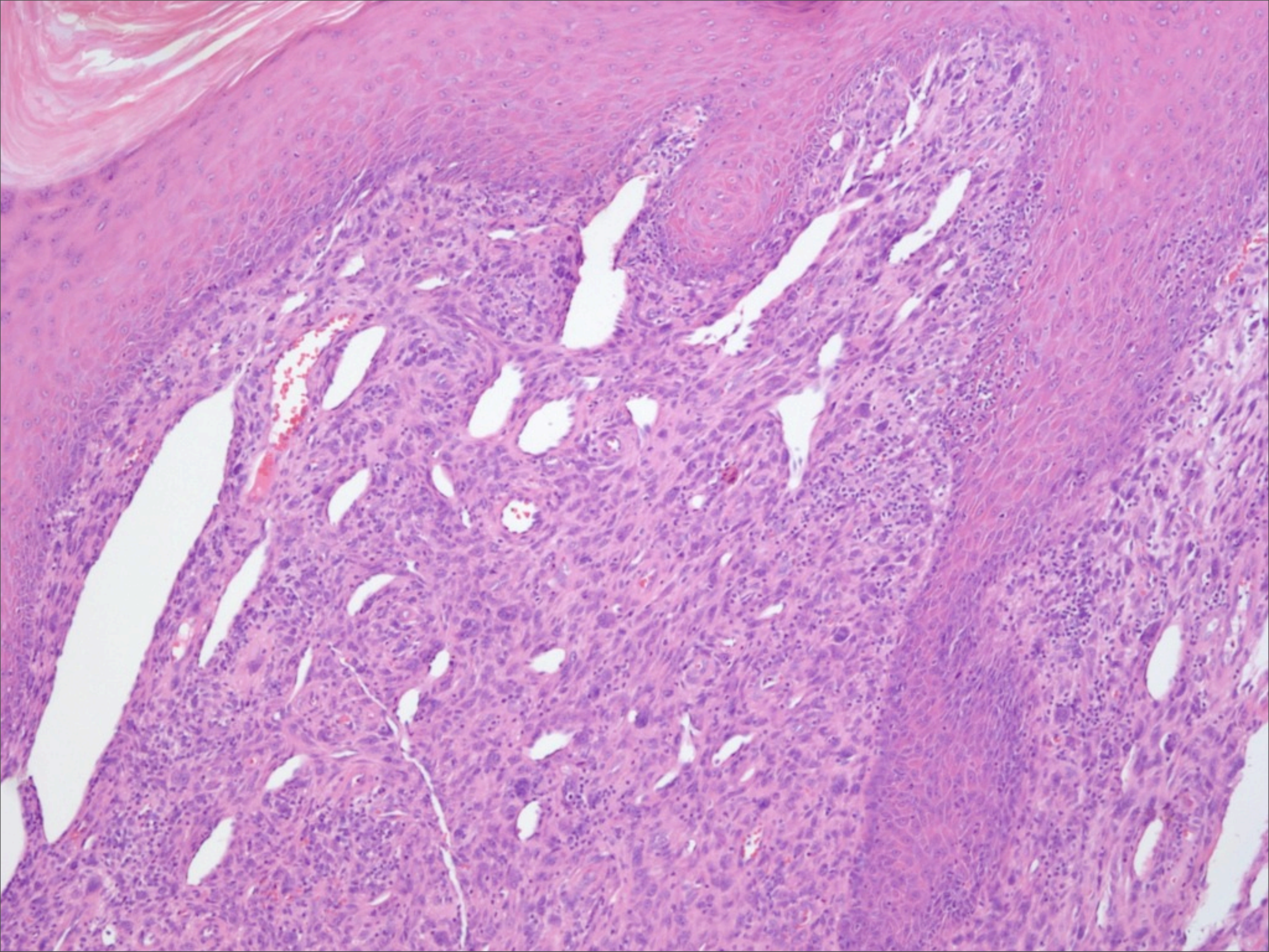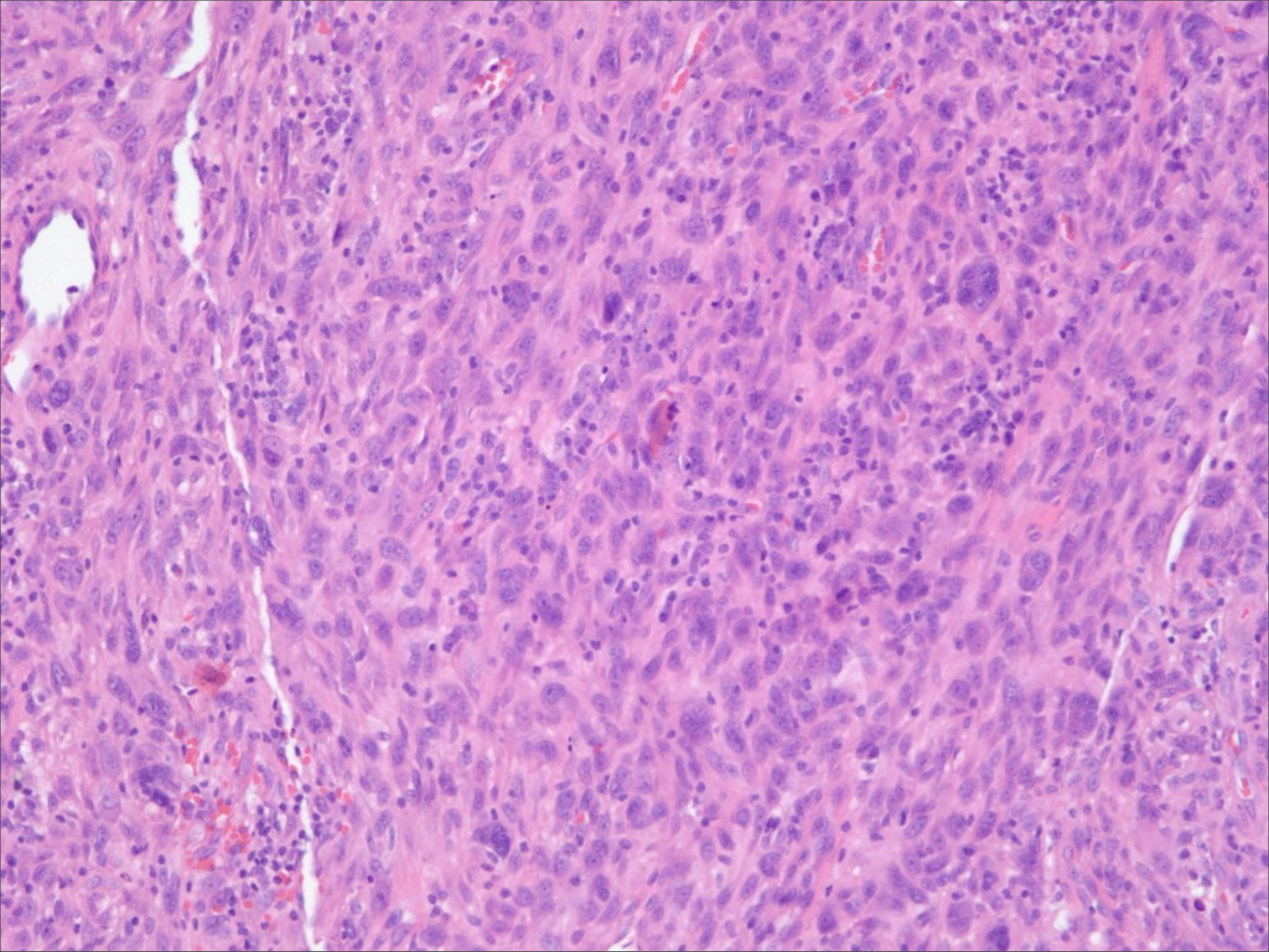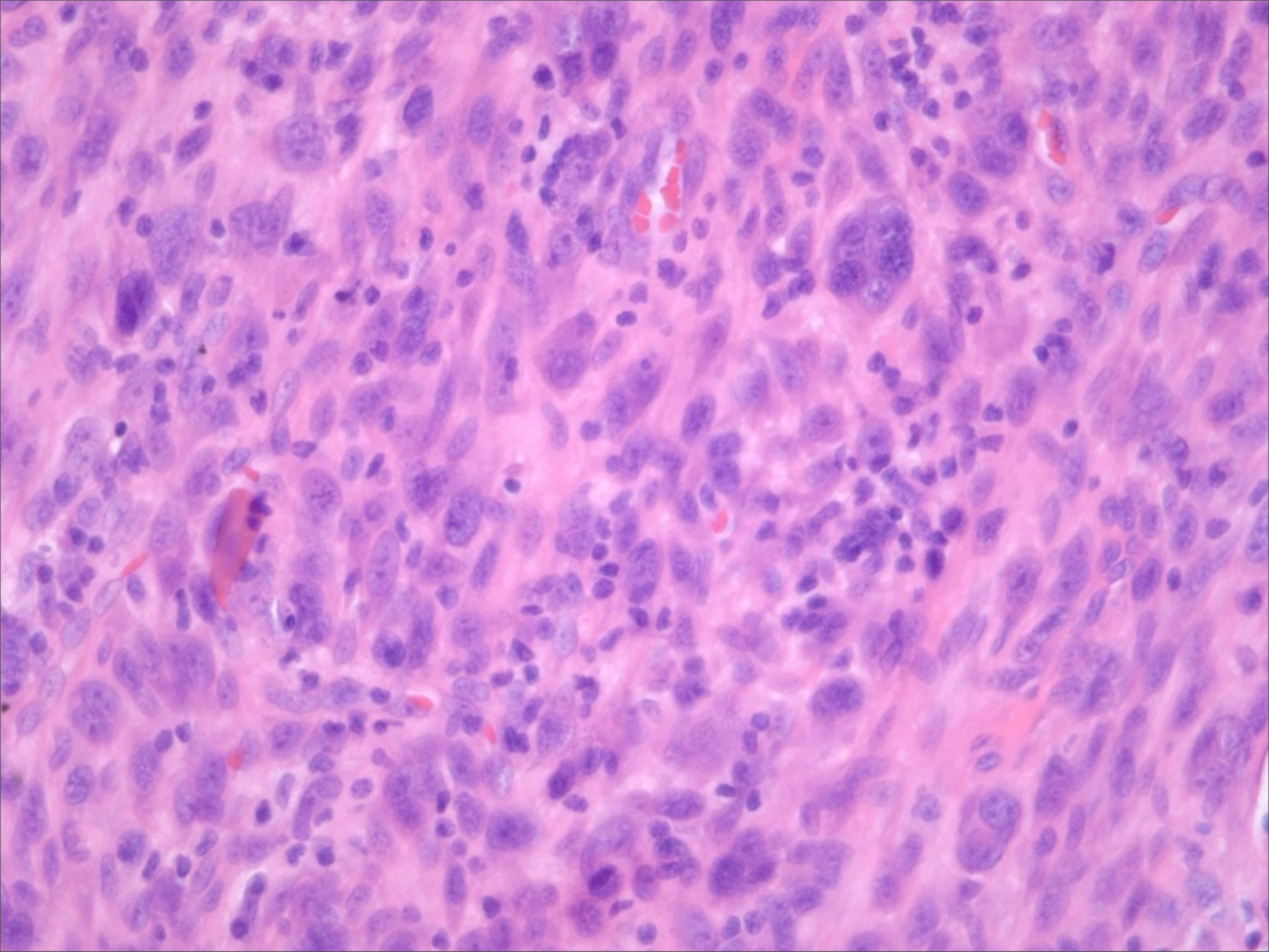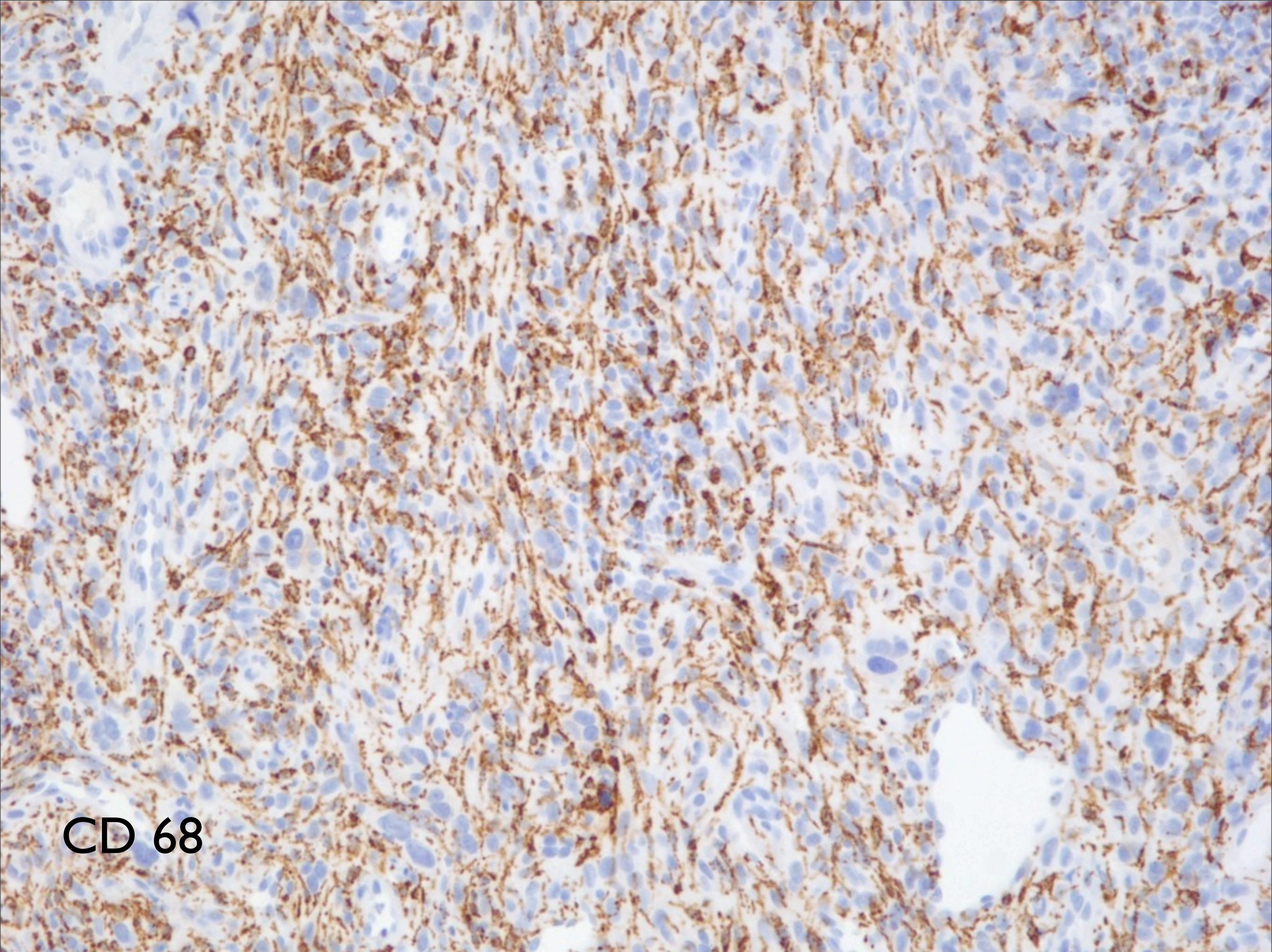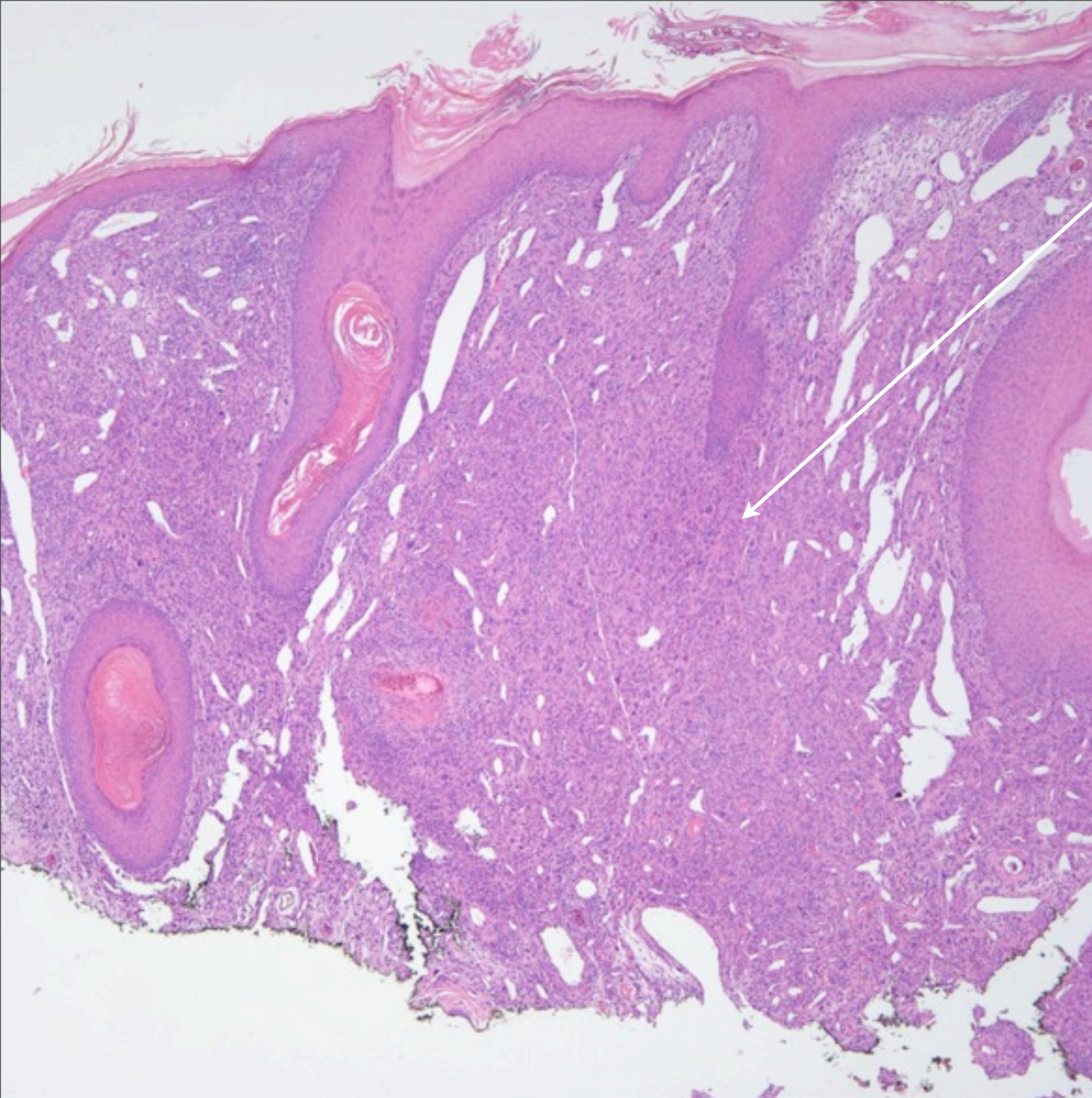


CD 68

Atypical Fibroxanthoma

Notes

- The tumor cells were negative for:
 - Smooth muscle actin, pan-cytokeratin, S100, Melan A, CD31, p63



Scattered malignant
multinucleated tumor
cells

Cytologically Malignant
Spindle Cells

Use IHC to confirm