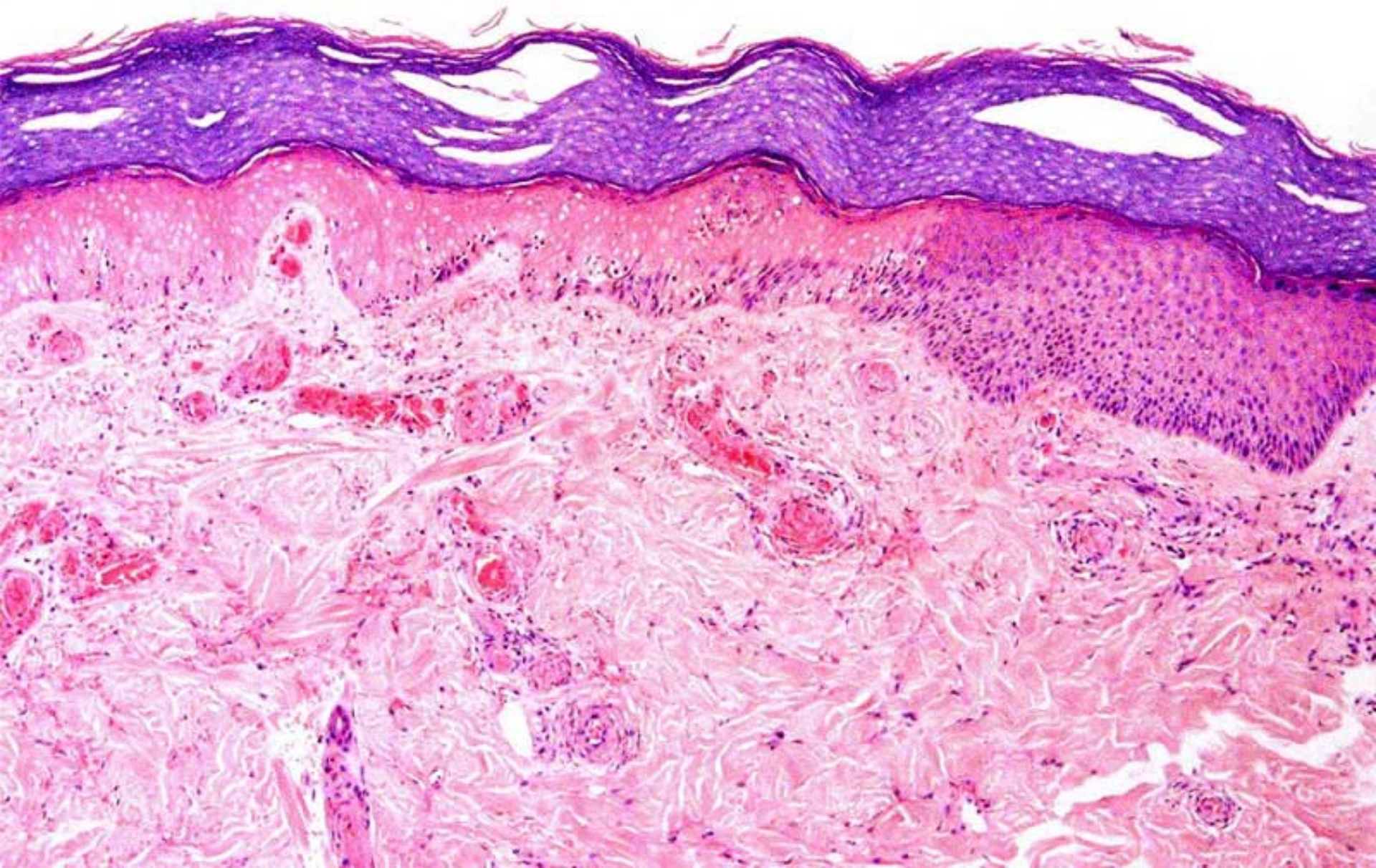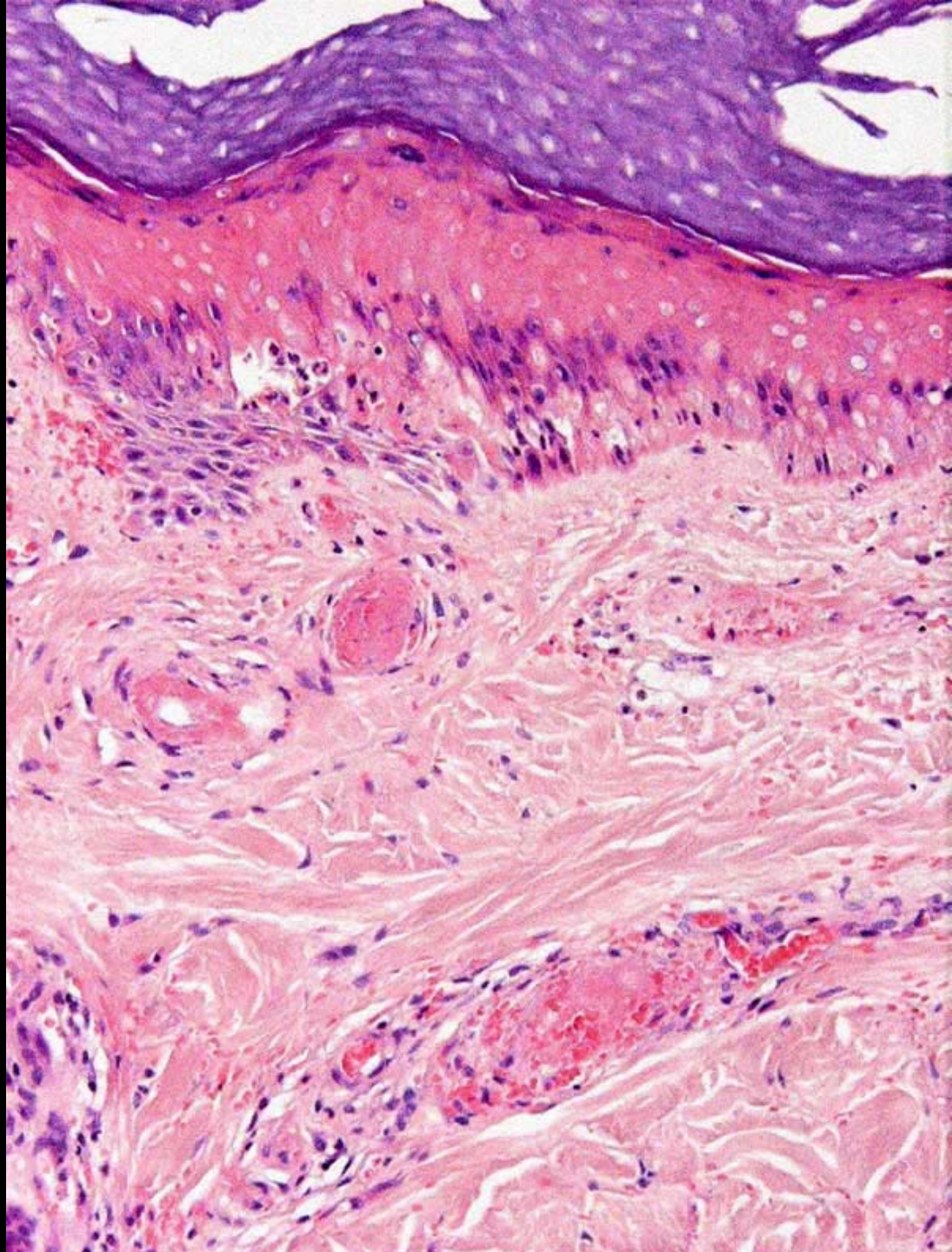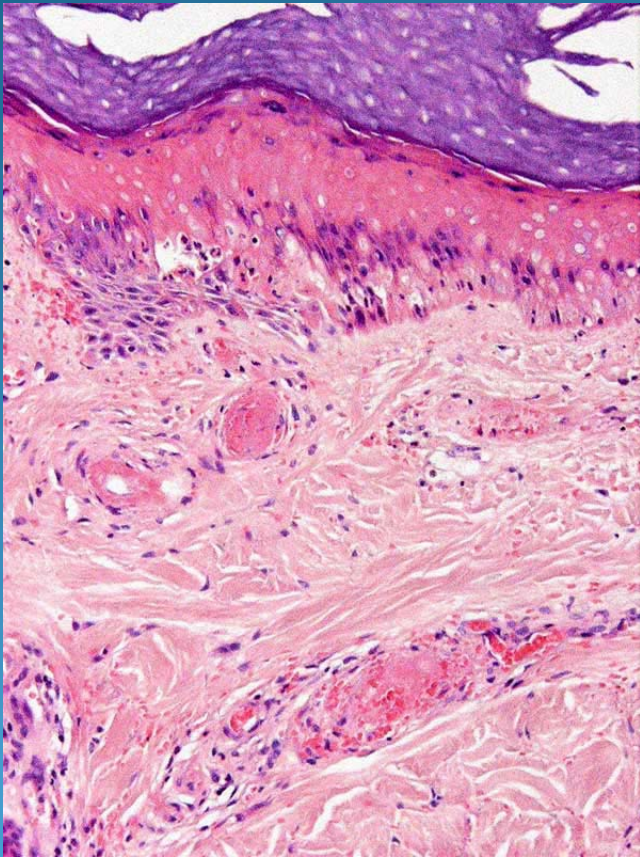


# Atrophie Blanche

# Pearls



- Acral skin with fibrin thrombi and dermal hemorrhage
- Fibrinoid necrosis within vessel walls
- Minimal leukocytoclasia