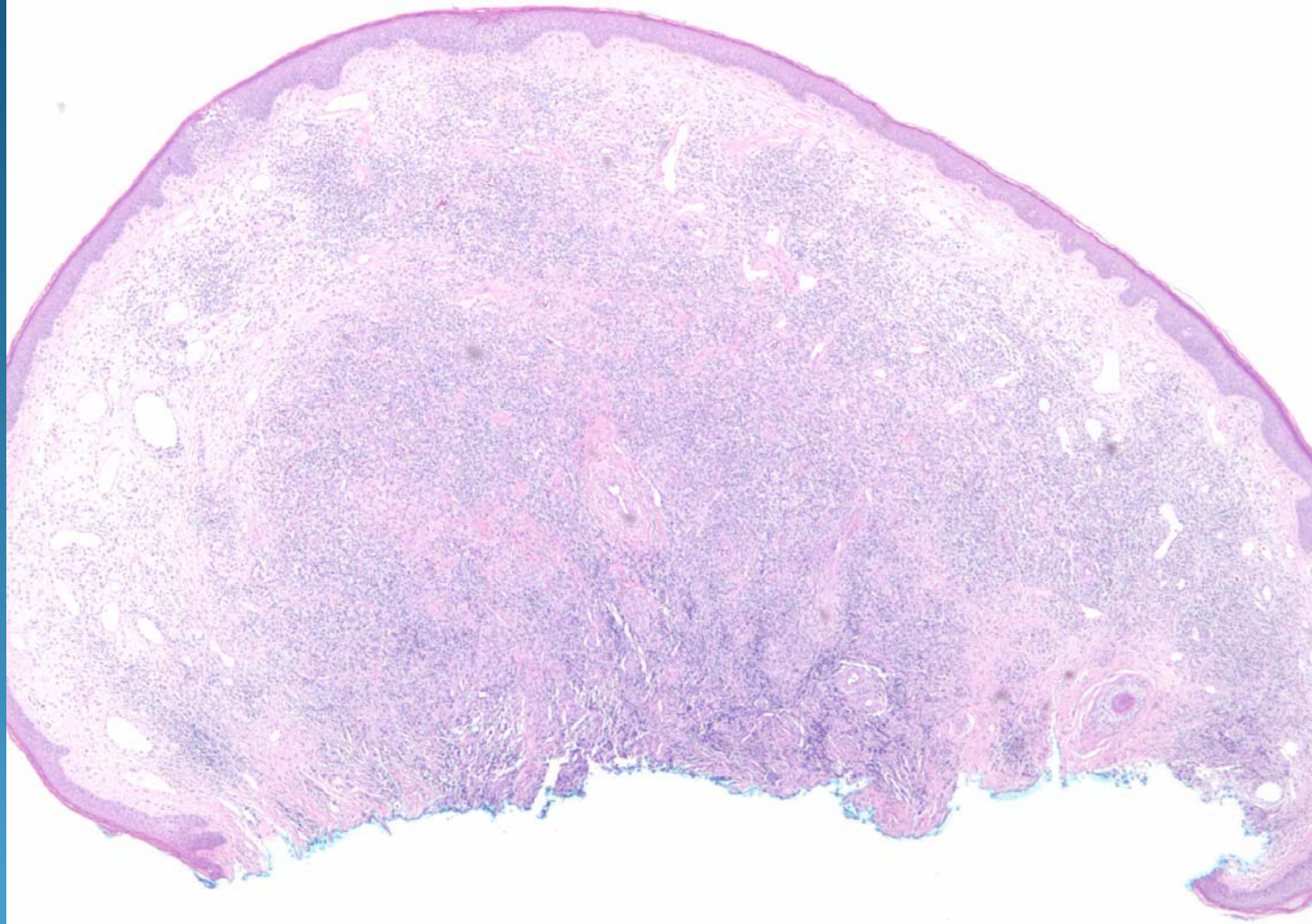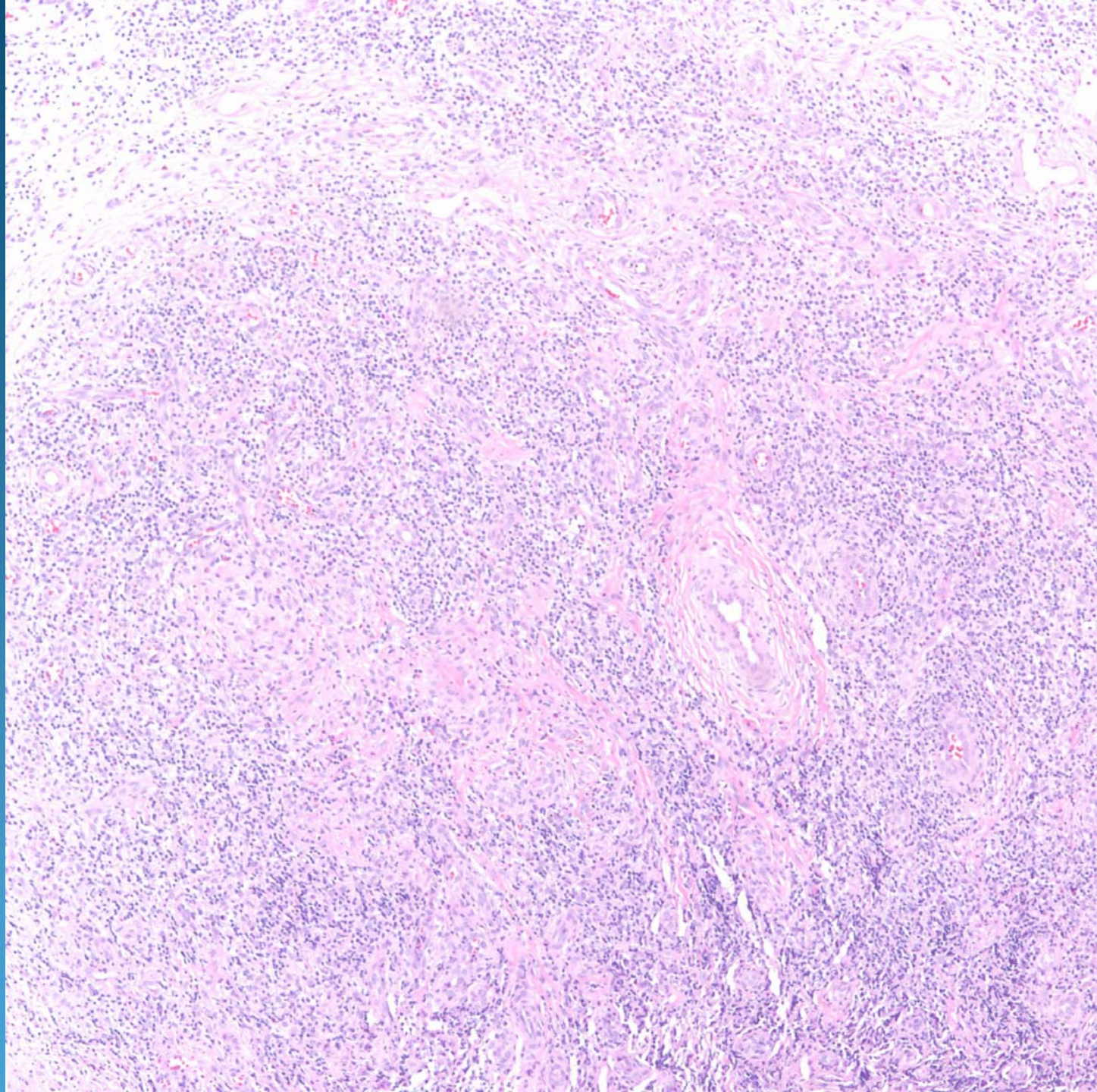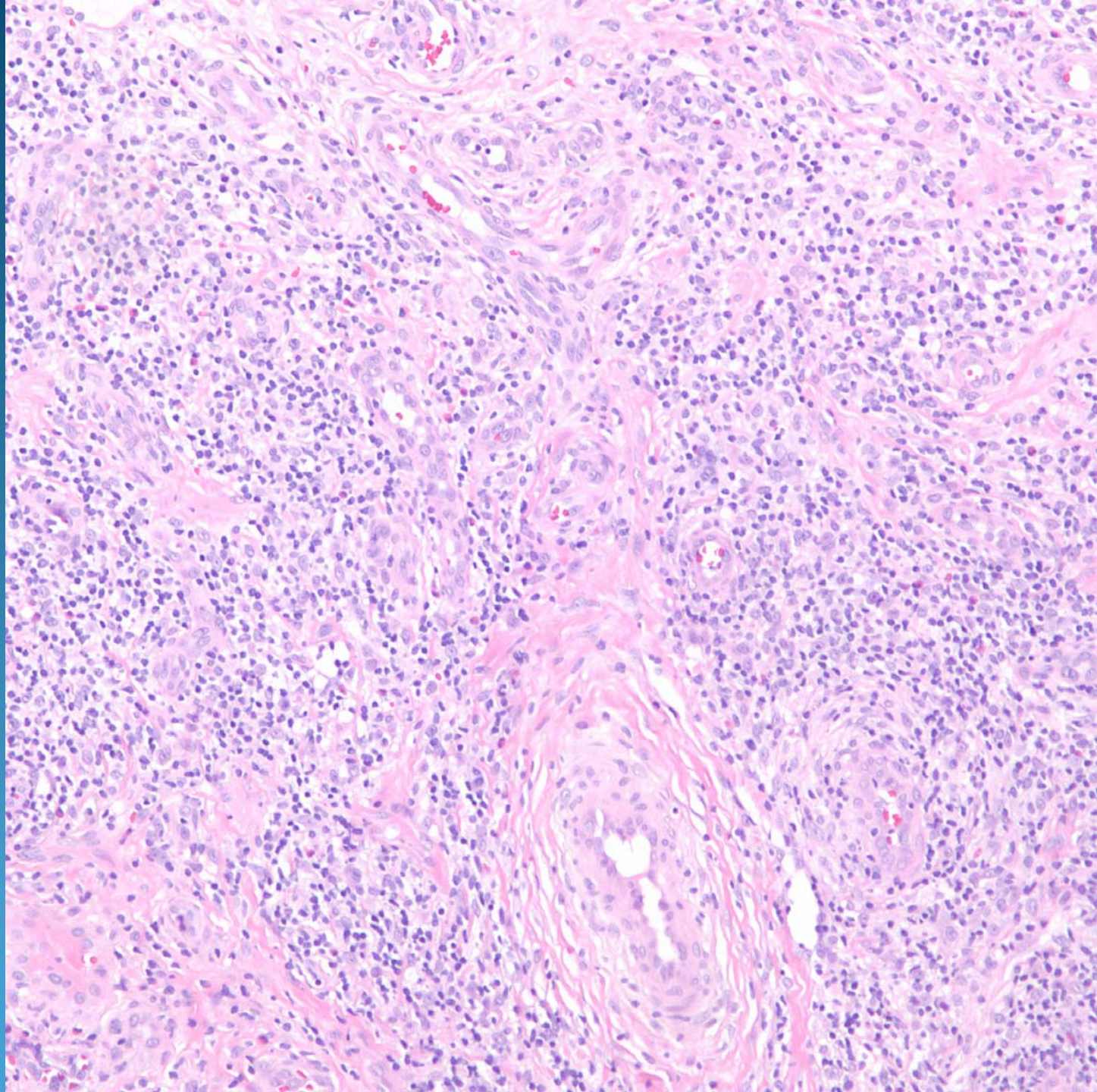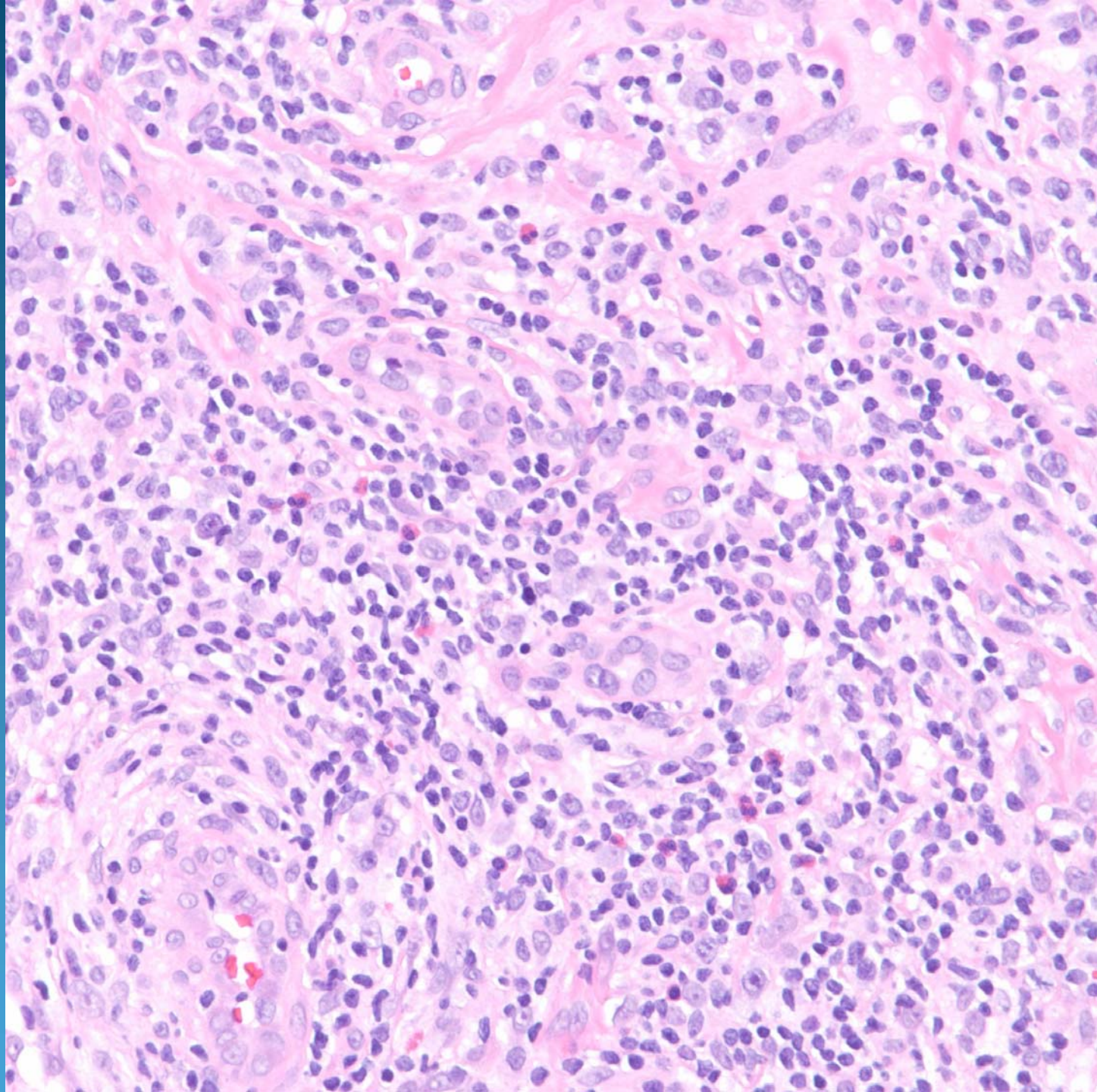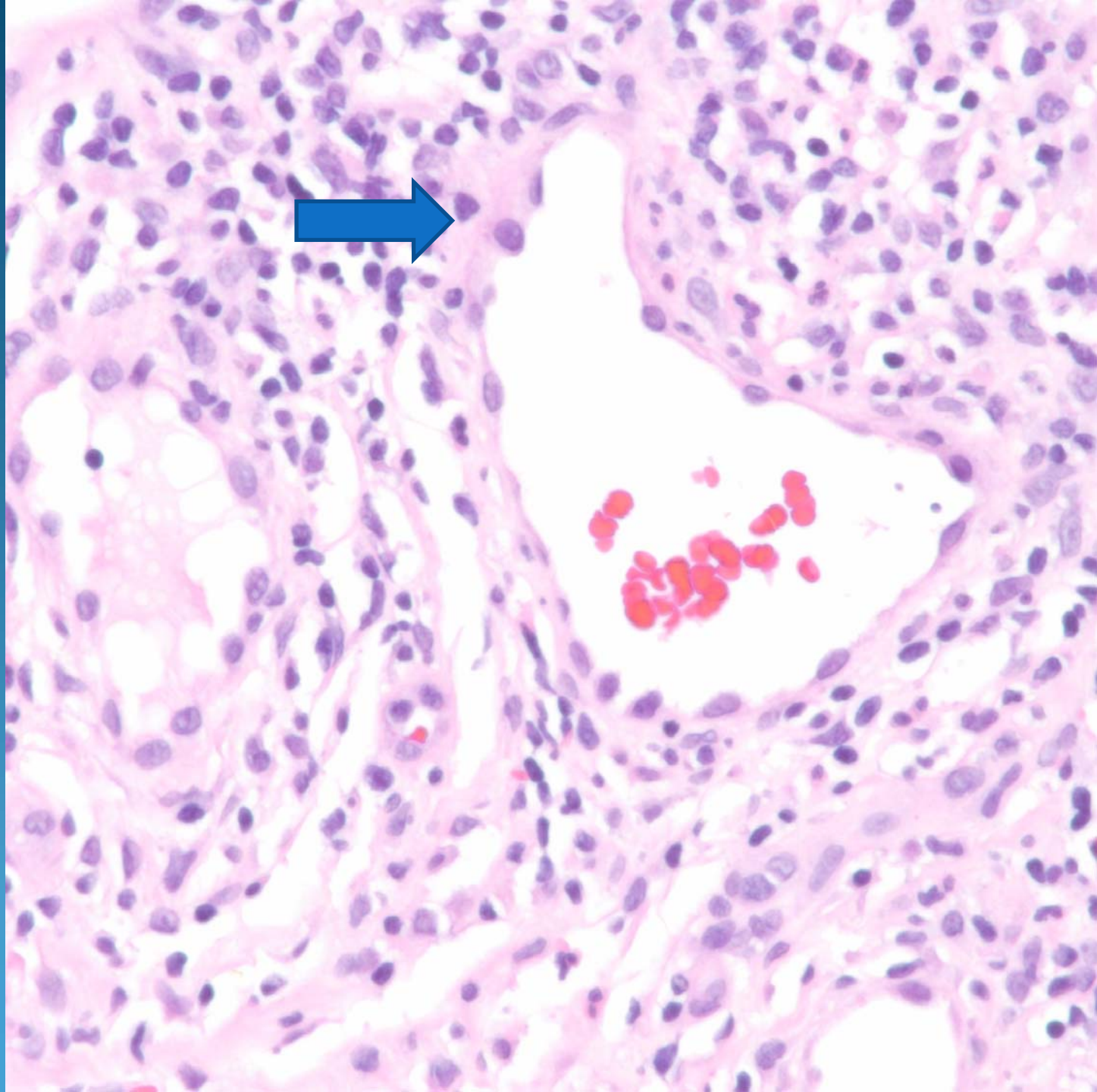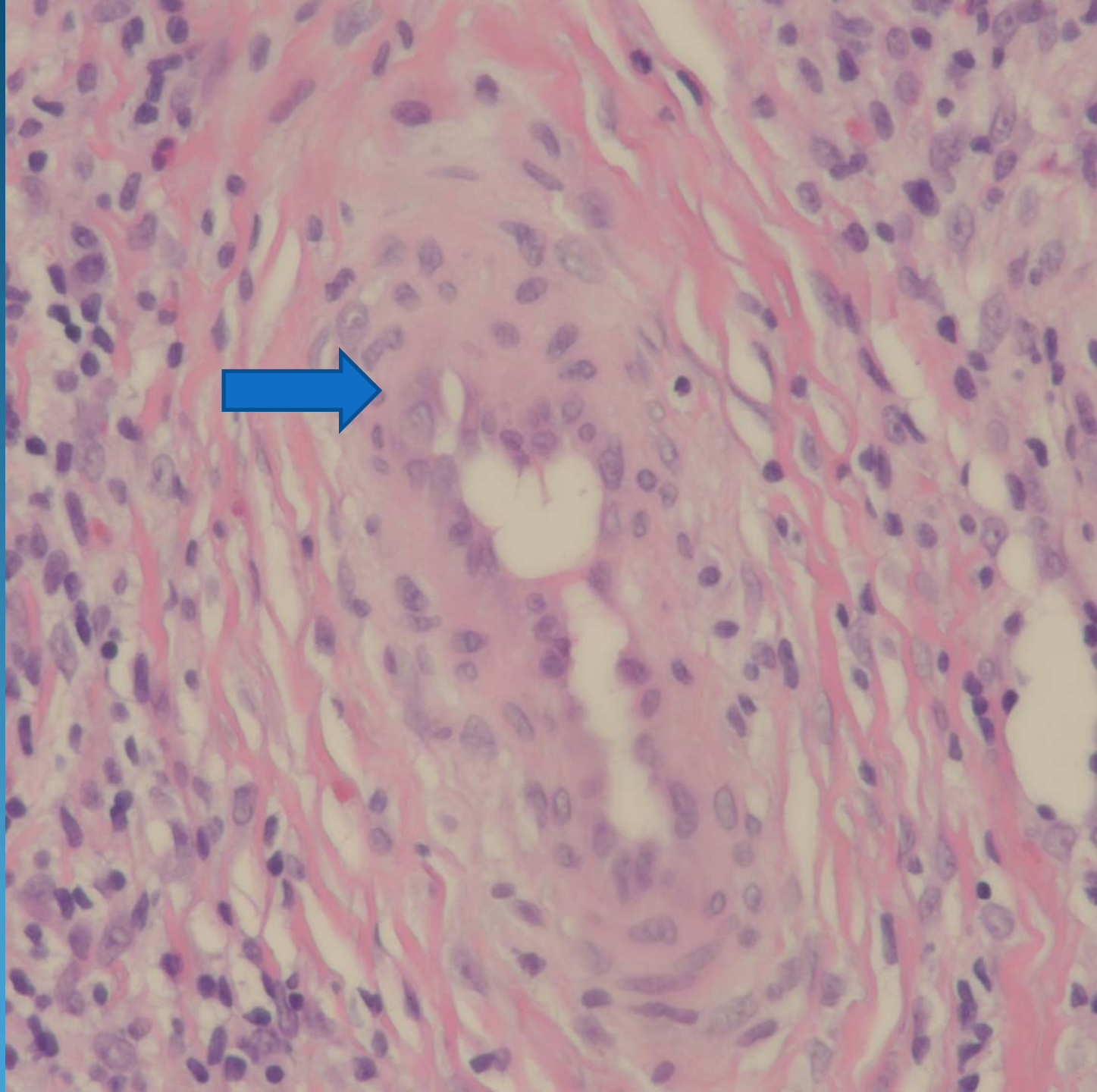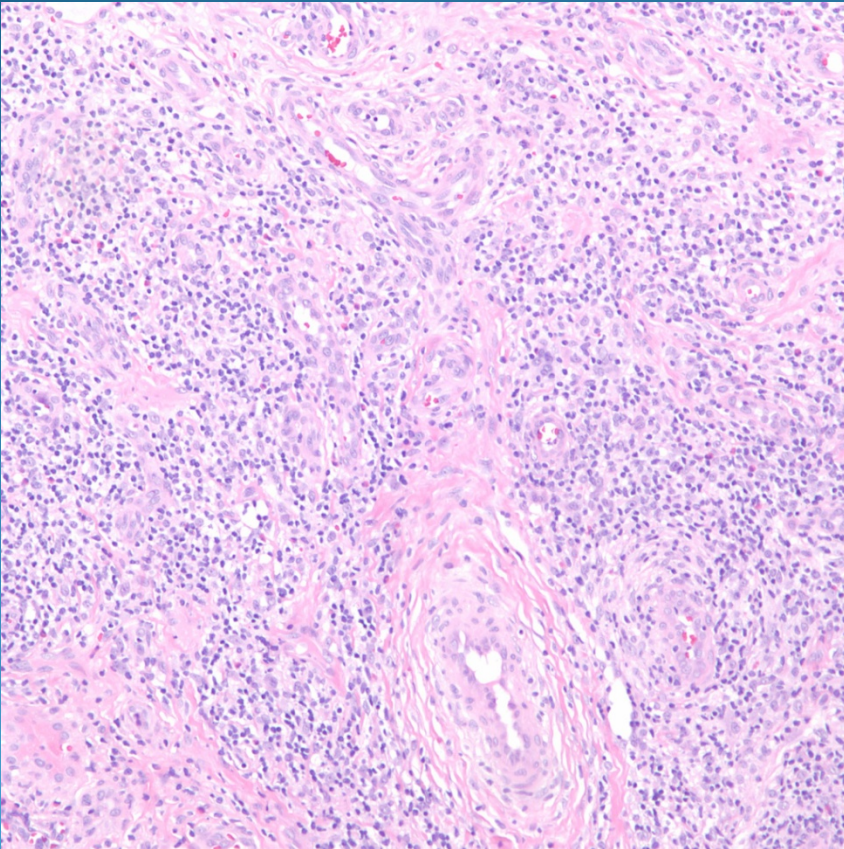


# Angiolymphoid Hyperplasia with Eosinophilia



# Pearls



- Superficial dermal nodular collection of lymphoid aggregates, eosinophils and thickened capillary sized vessels
- Hobnail endothelial cells with cytoplasmic vacuoles