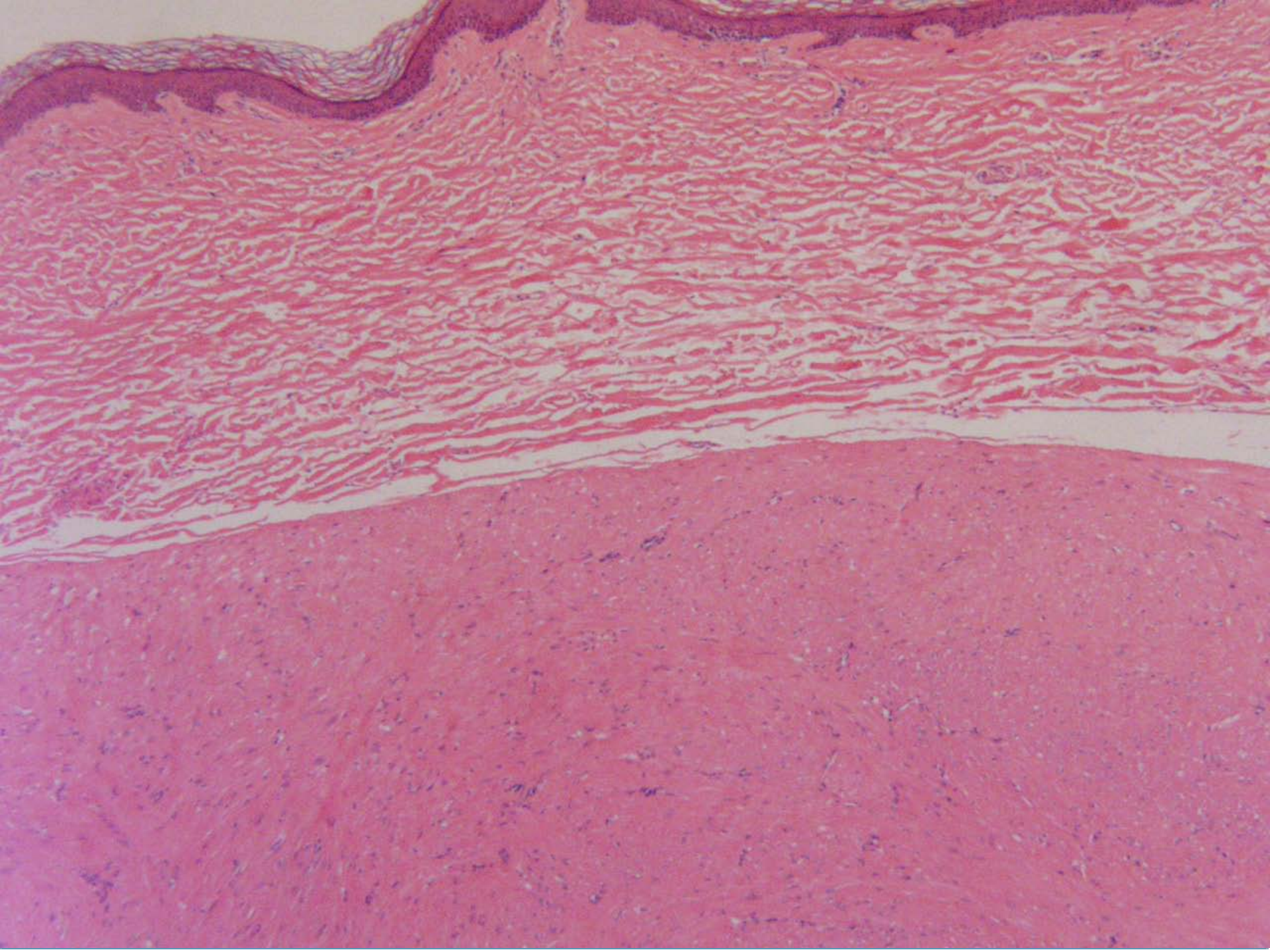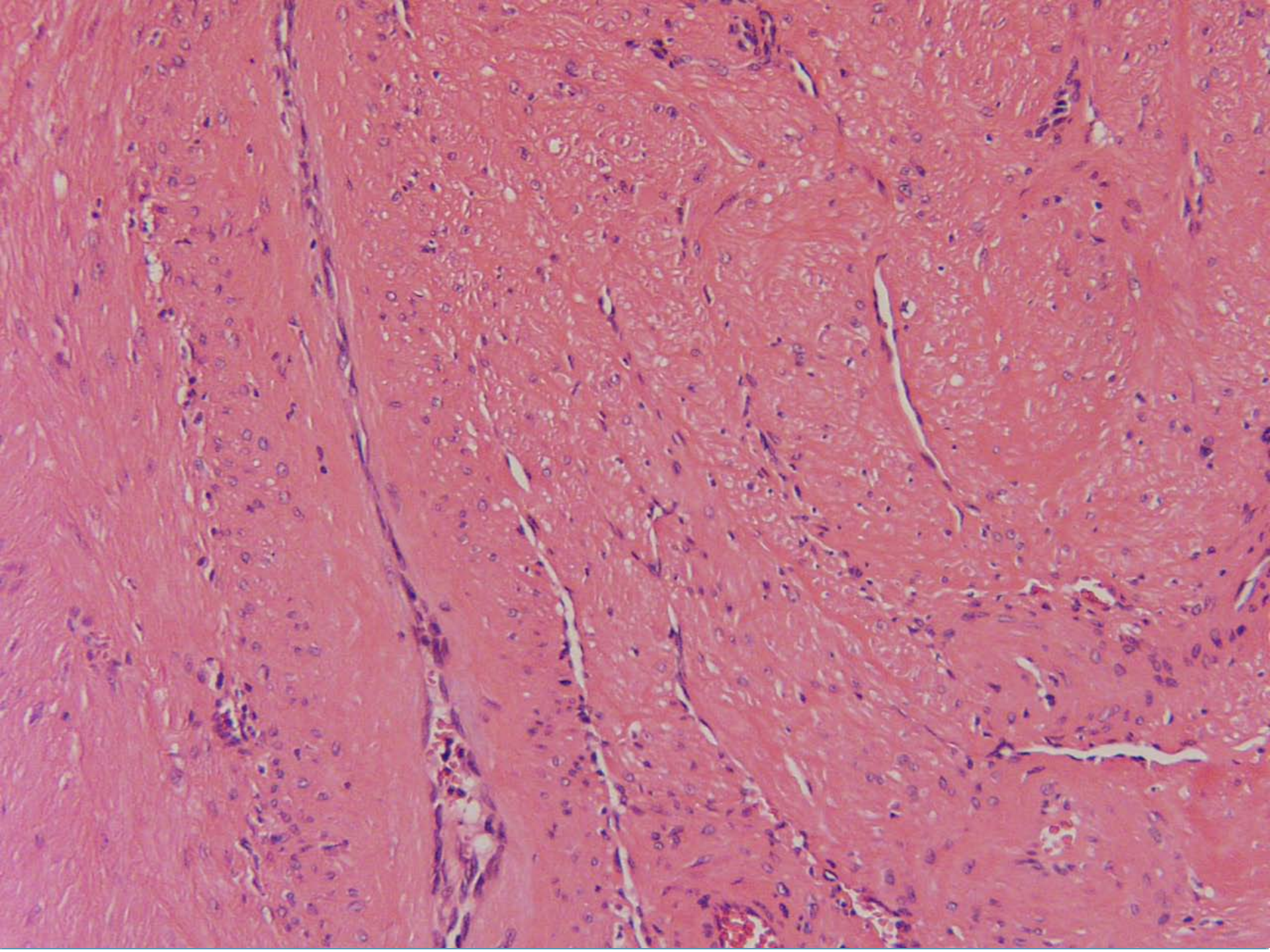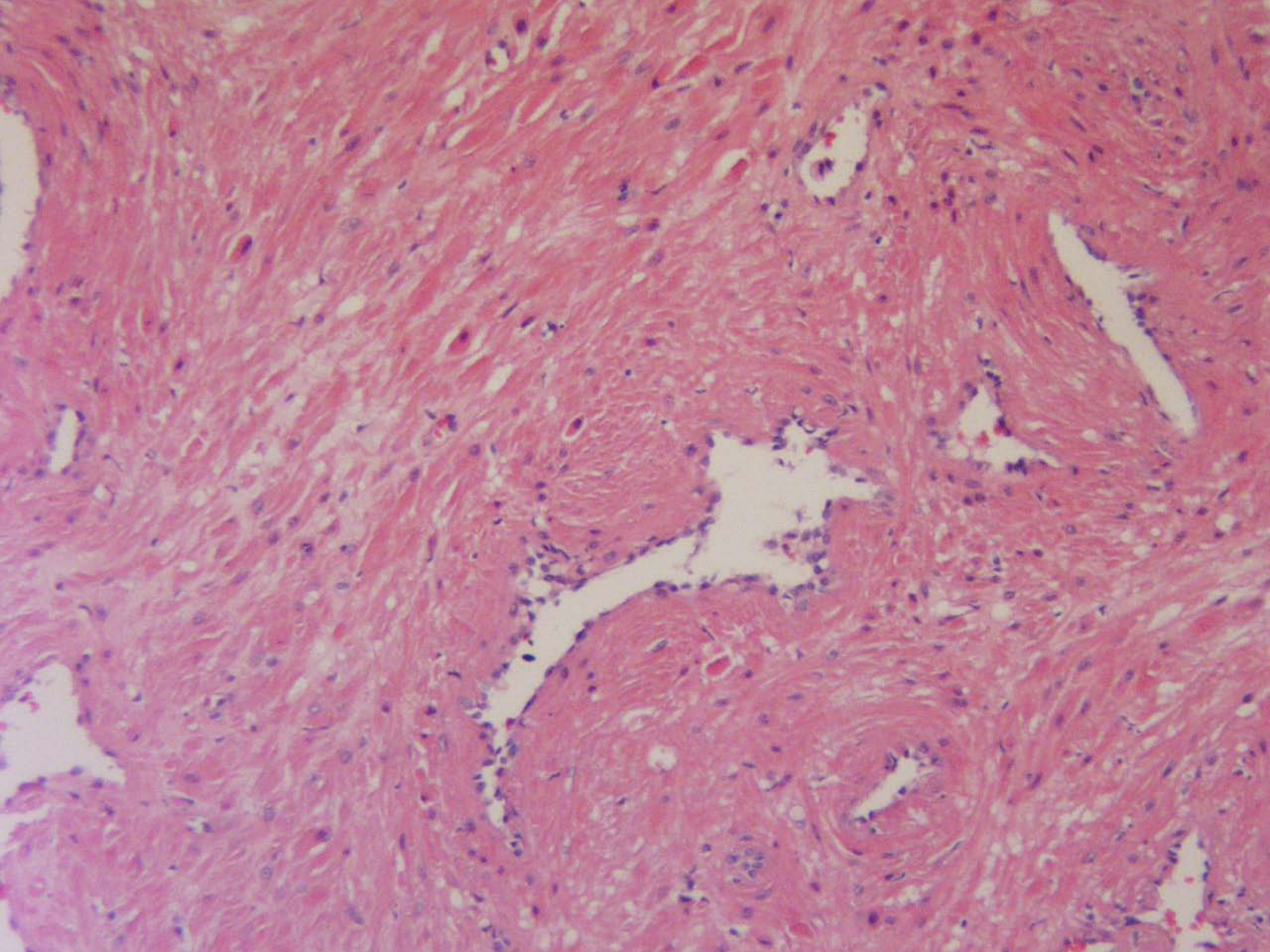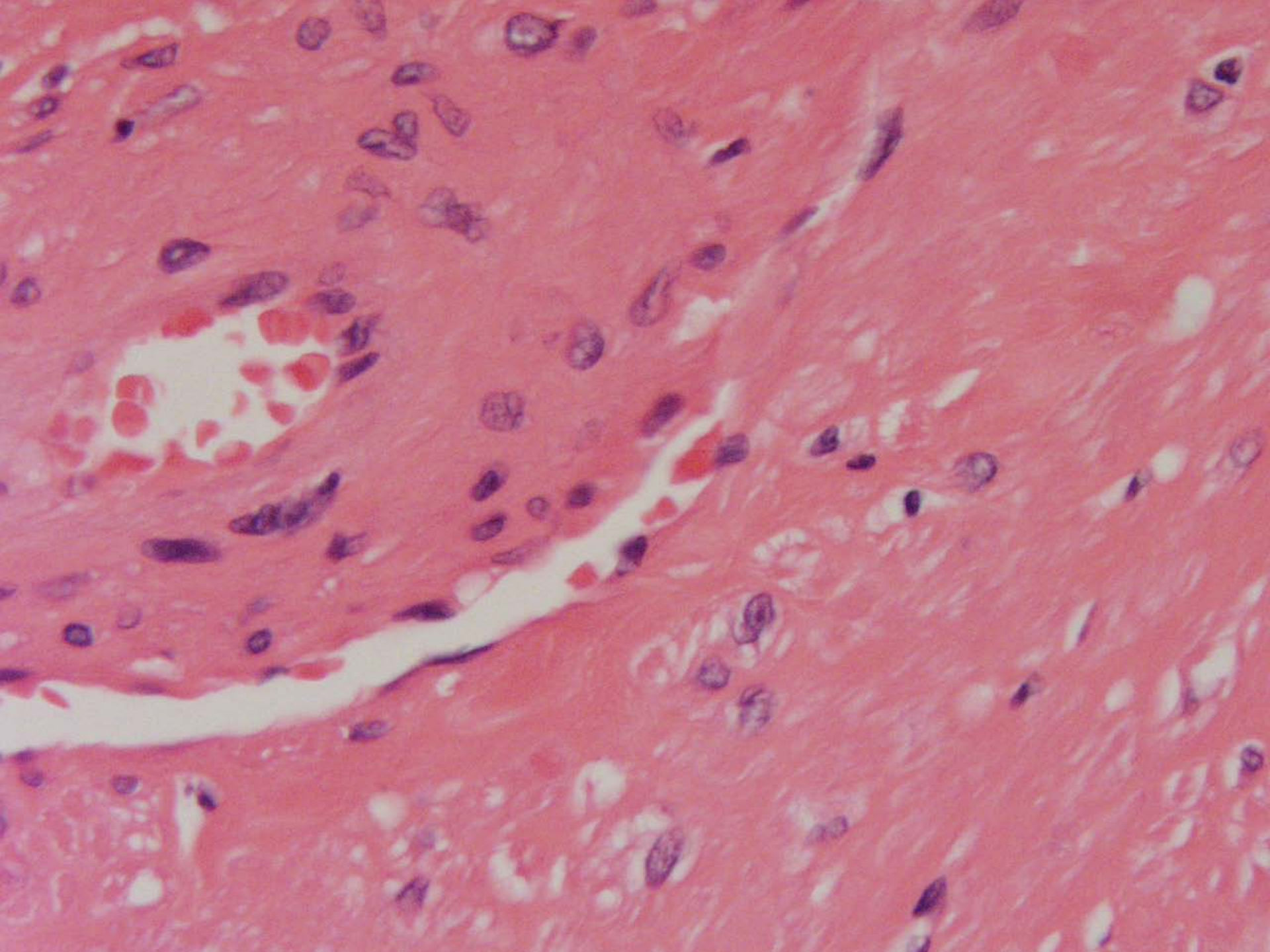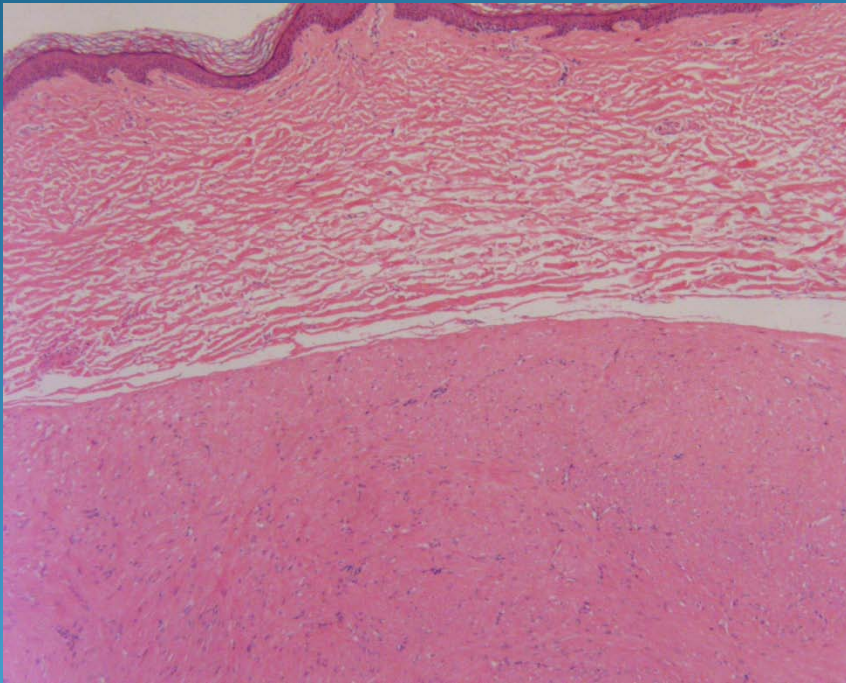


Angioleiomyoma

Pearls



- Well circumscribed dermal nodule, usually deep in reticular dermis
- Low cellularity with spindle cells arising from thick walled vessels