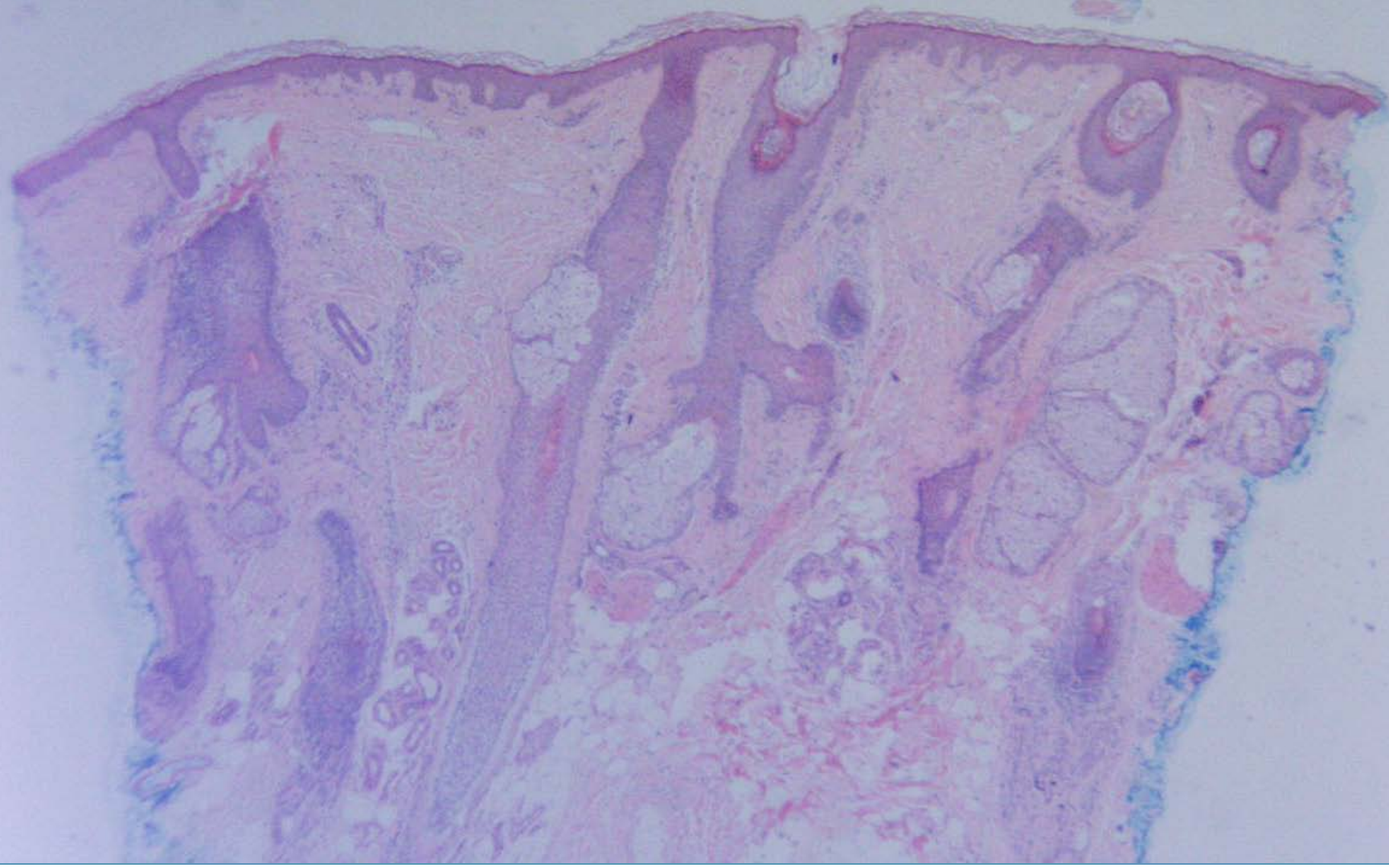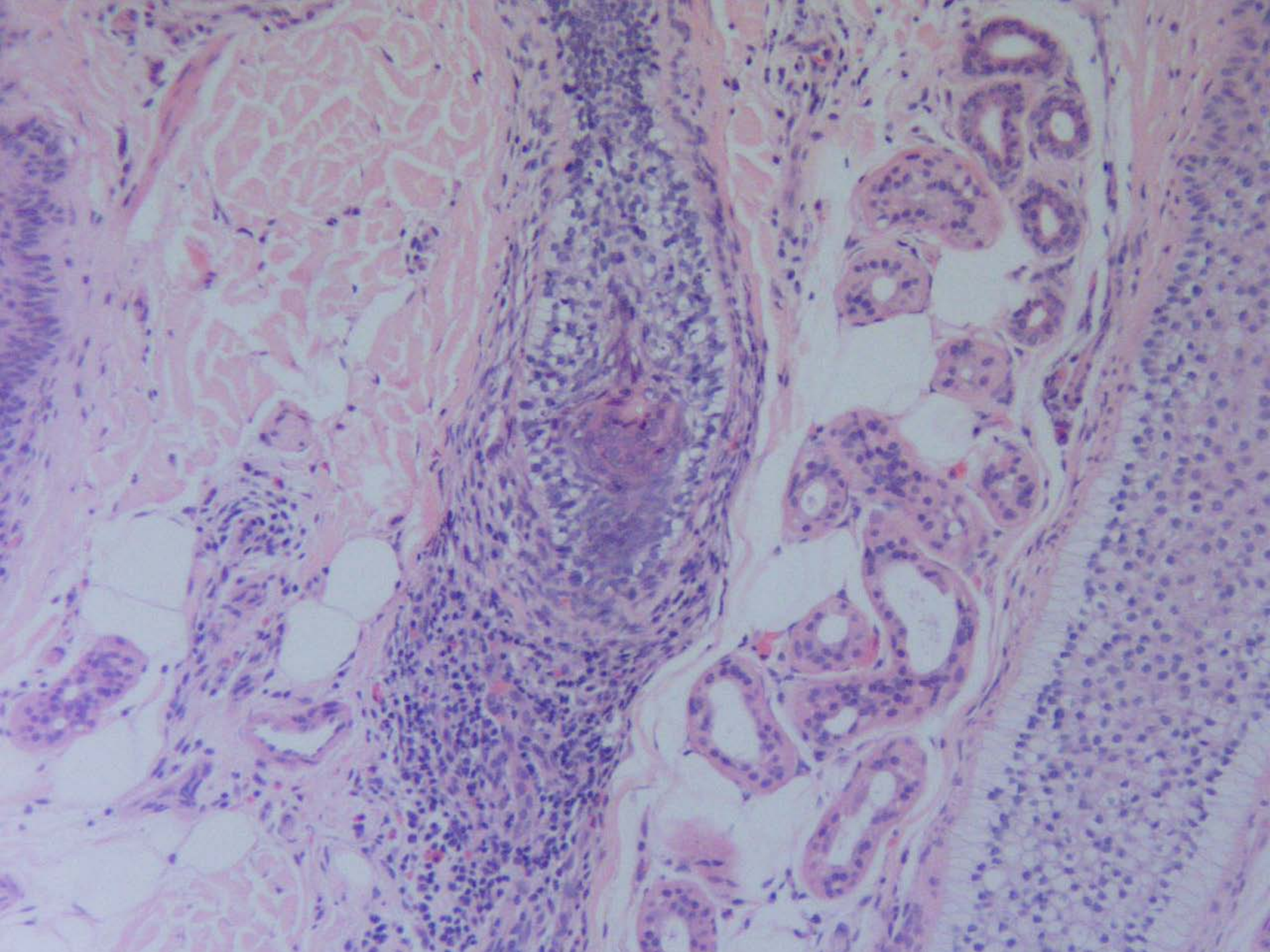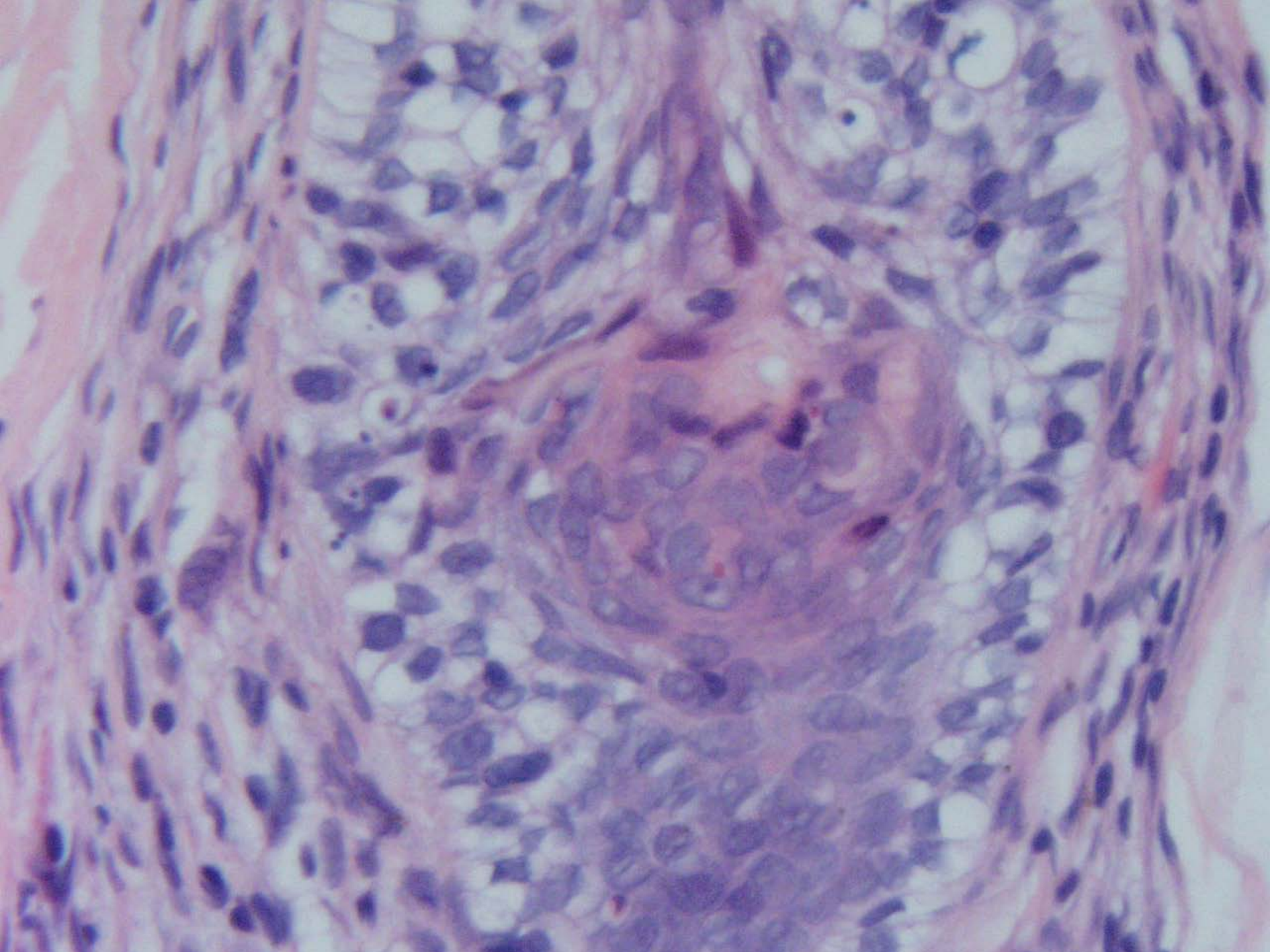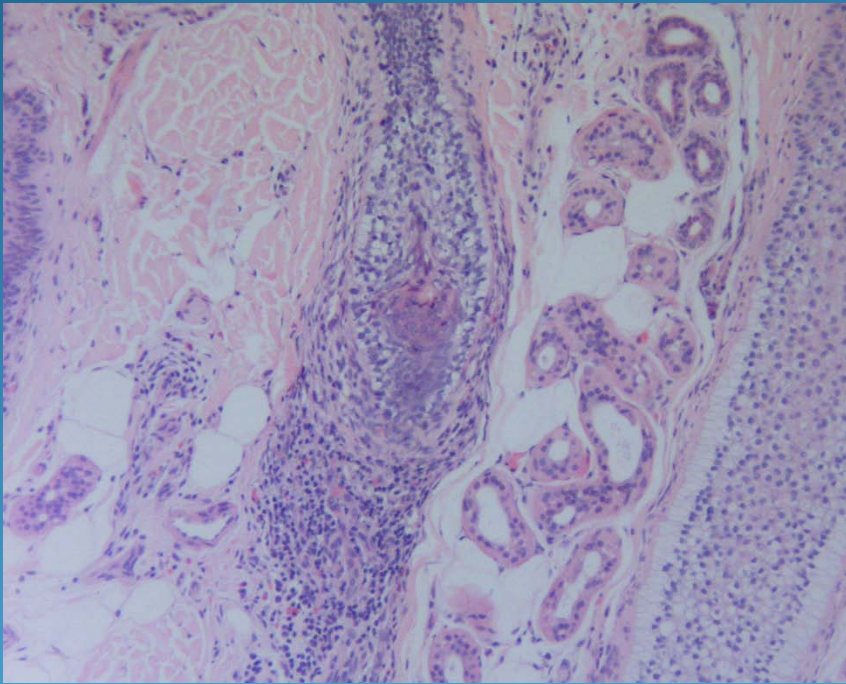


Alopecia Areata

Pearls



- Perifollicular collection of lymphocytes “swarm of bees”
- Non-scarring alopecia
- May show increased catagen hairs