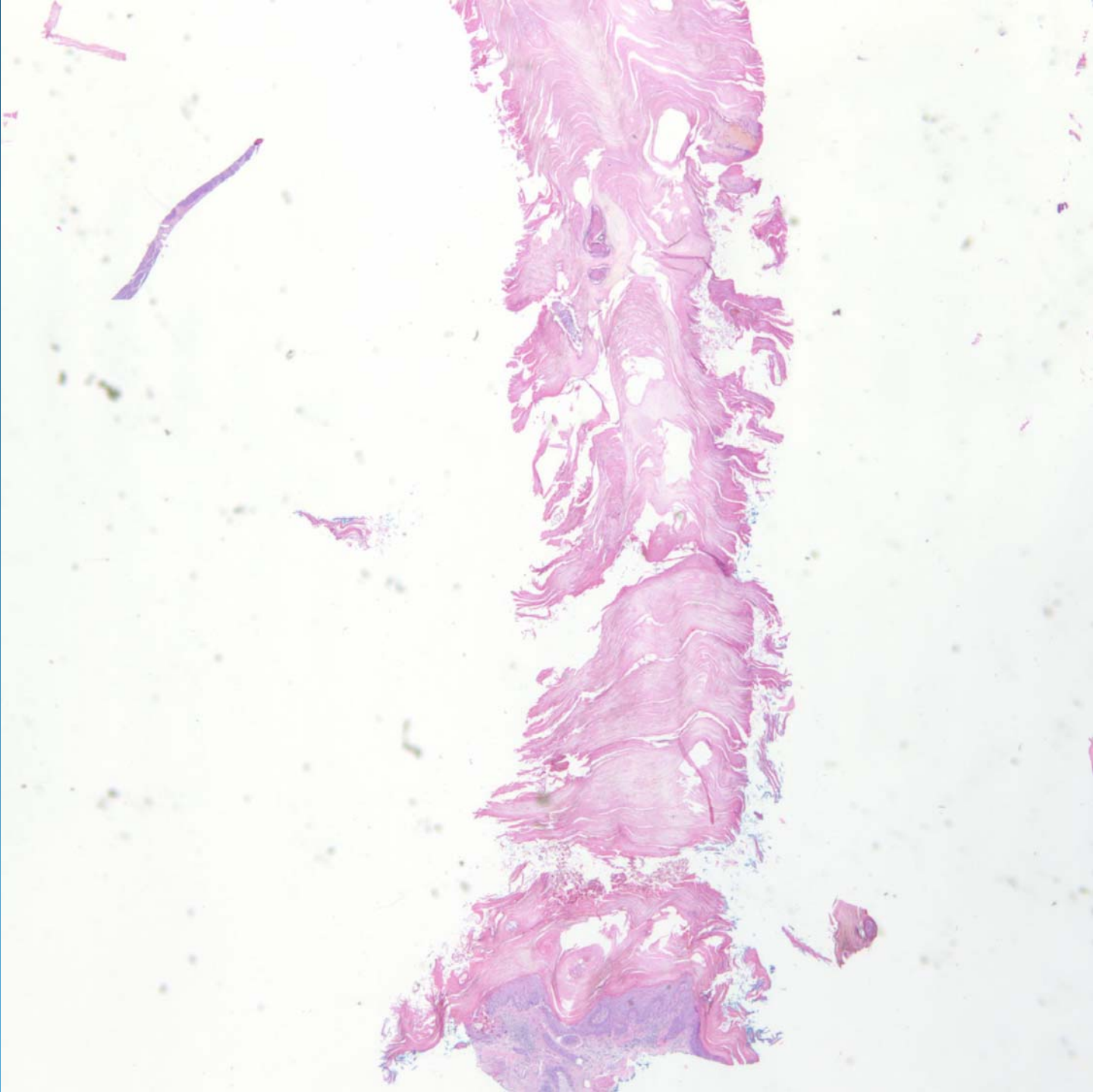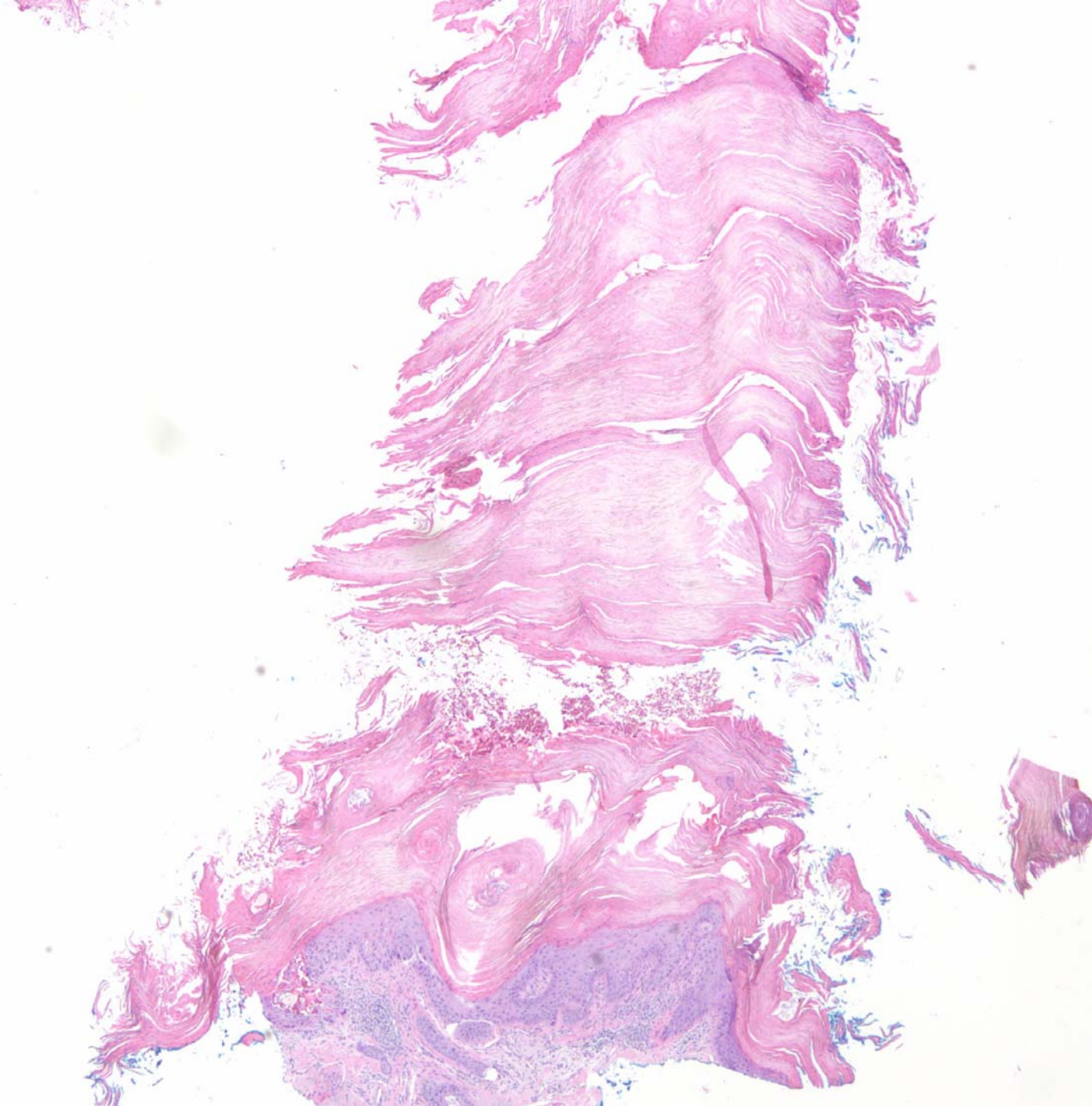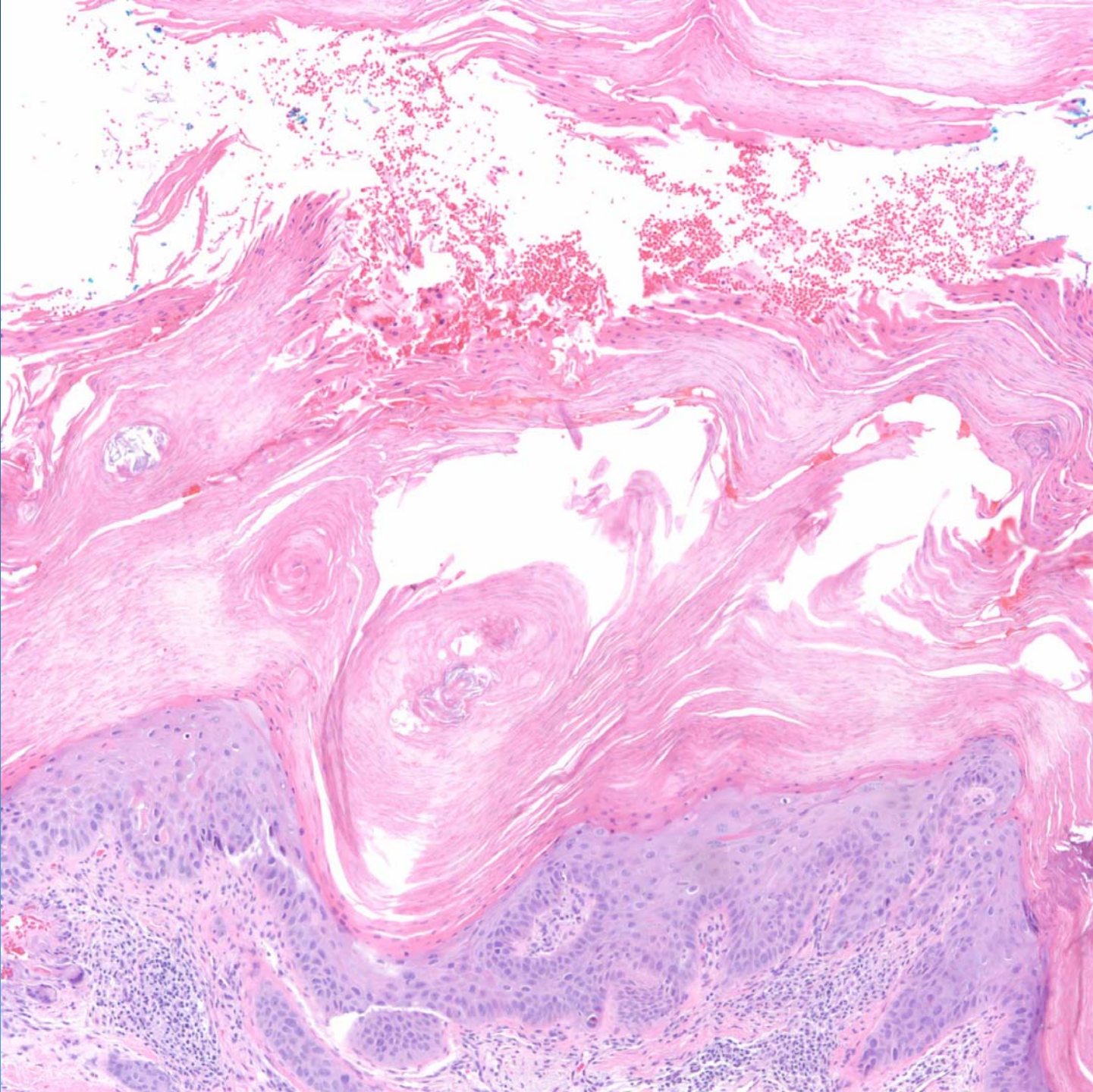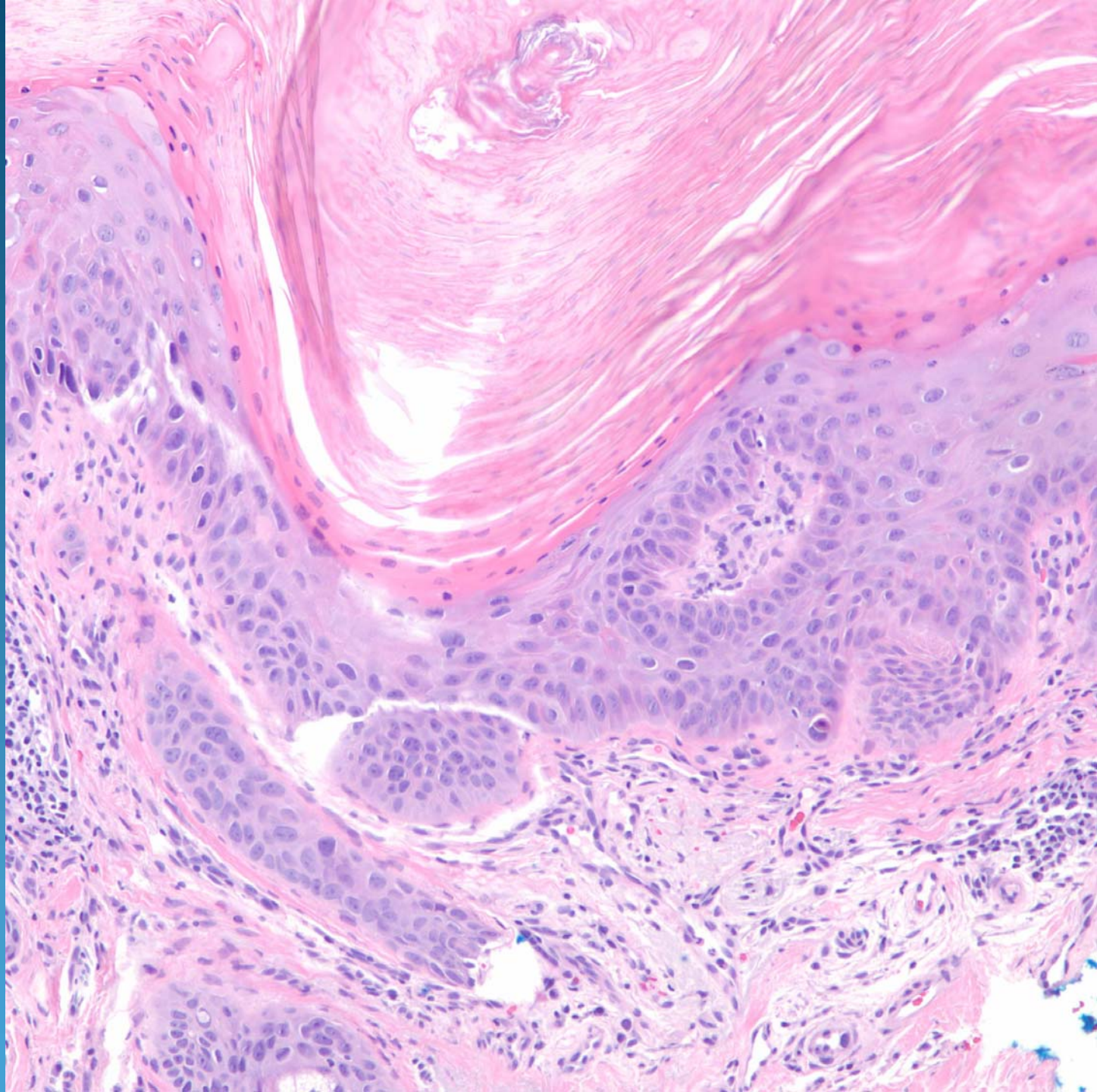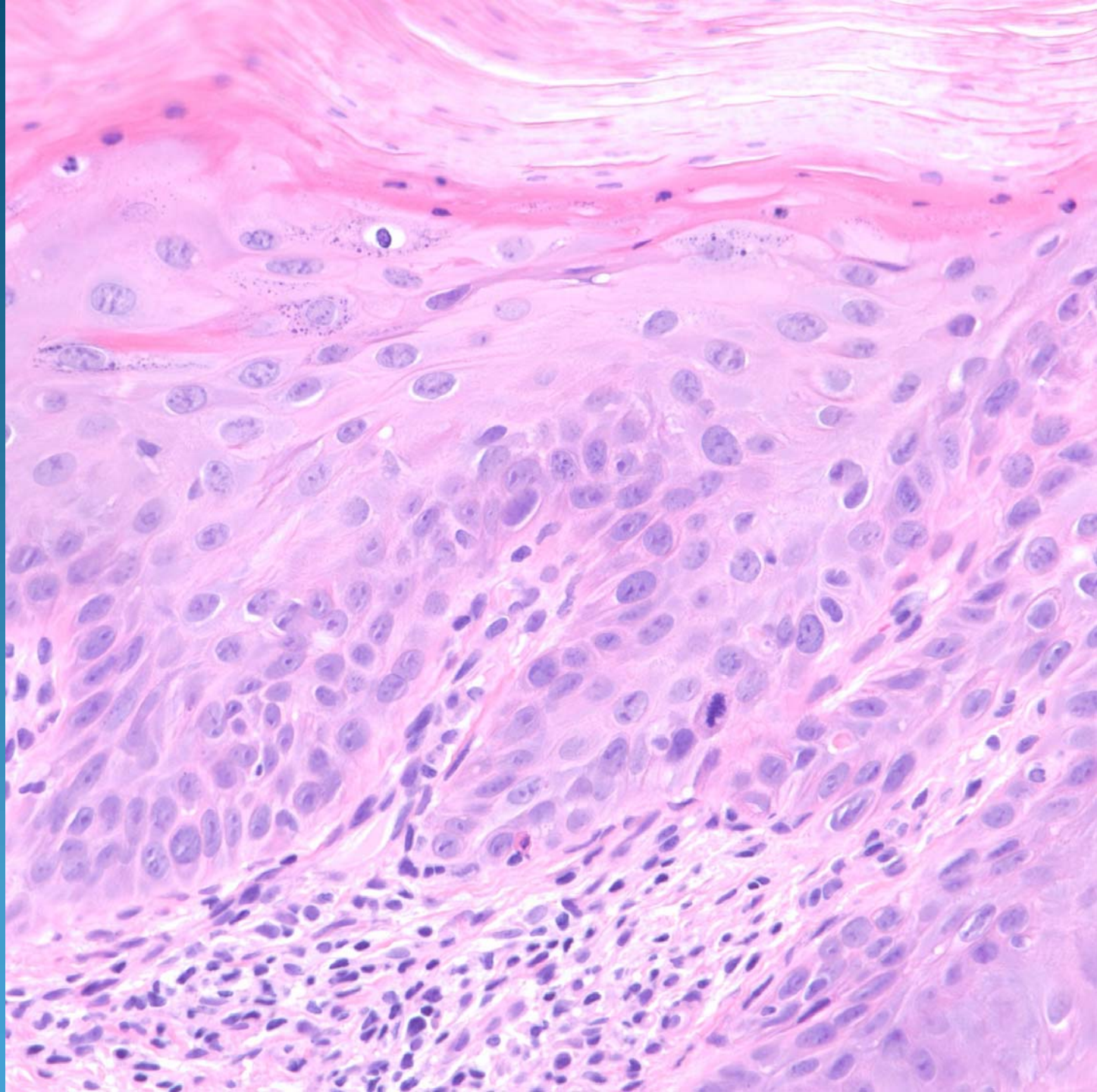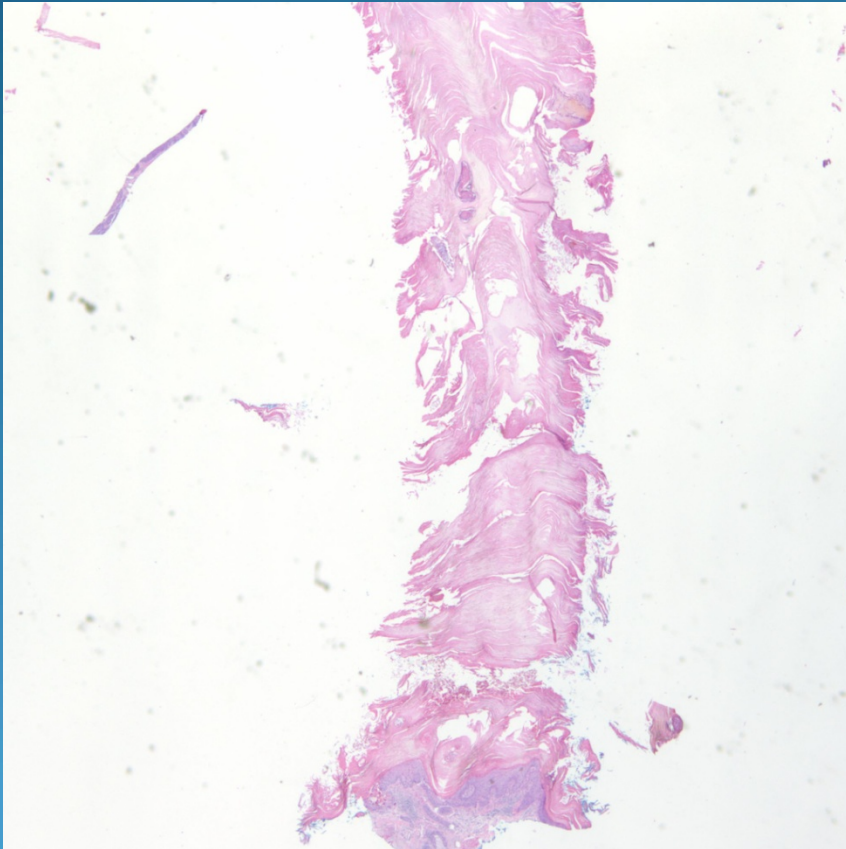


Actinic Keratosis with Cutaneous Horn

Pearls



- Cutaneous horn may be seen with benign or malignant epithelial proliferations
- Need to assess the base of each lesion for definitive diagnosis