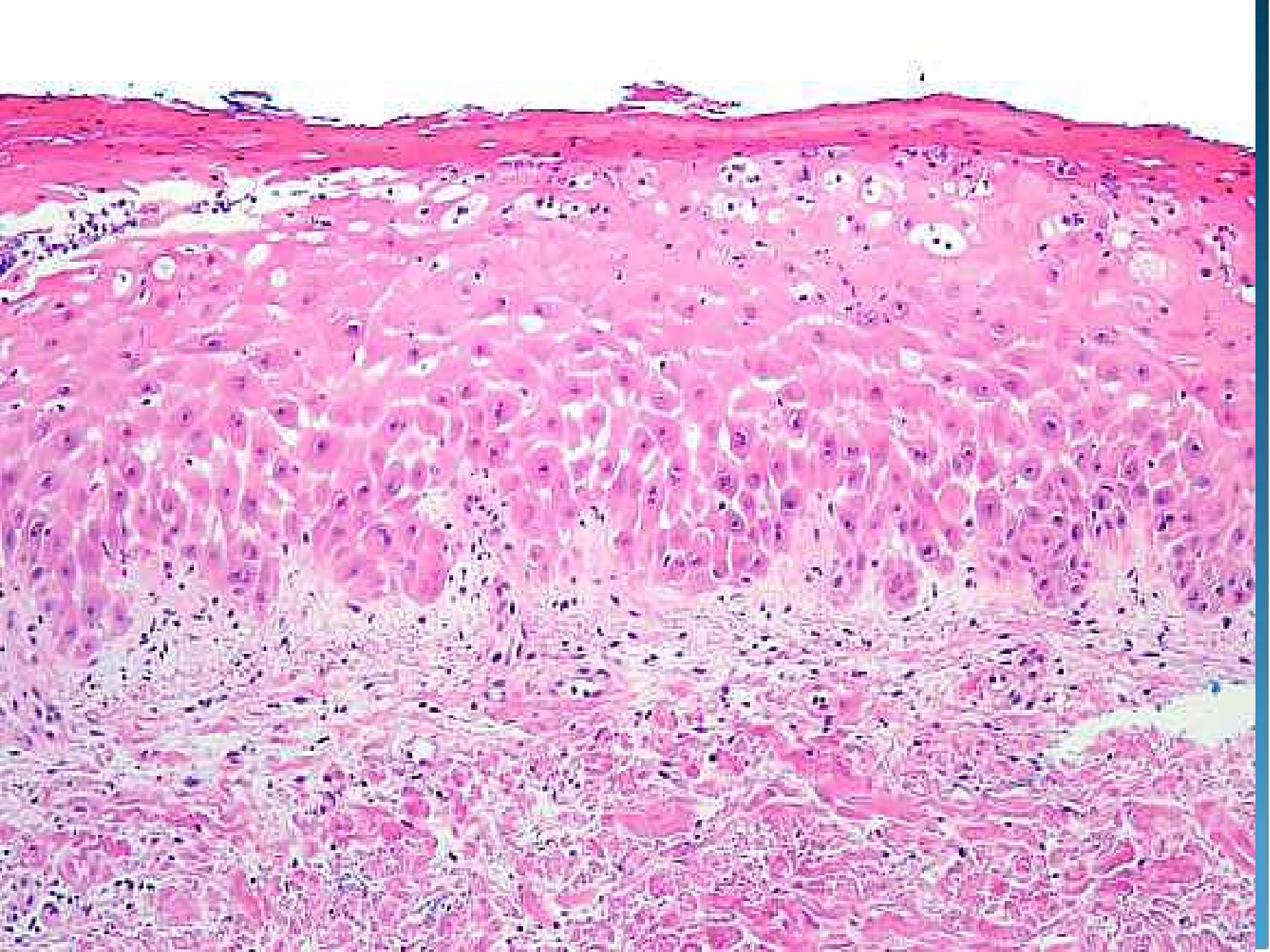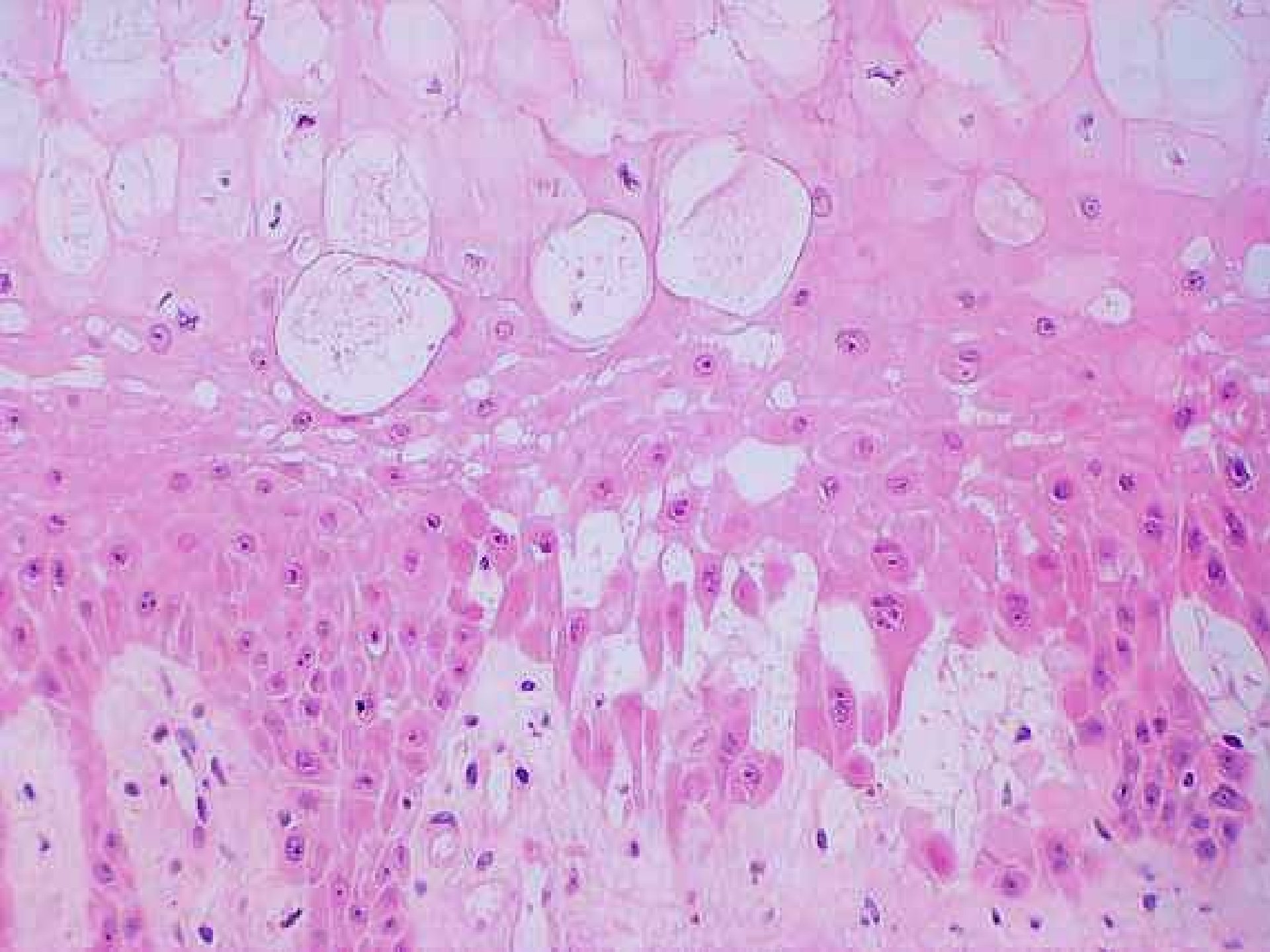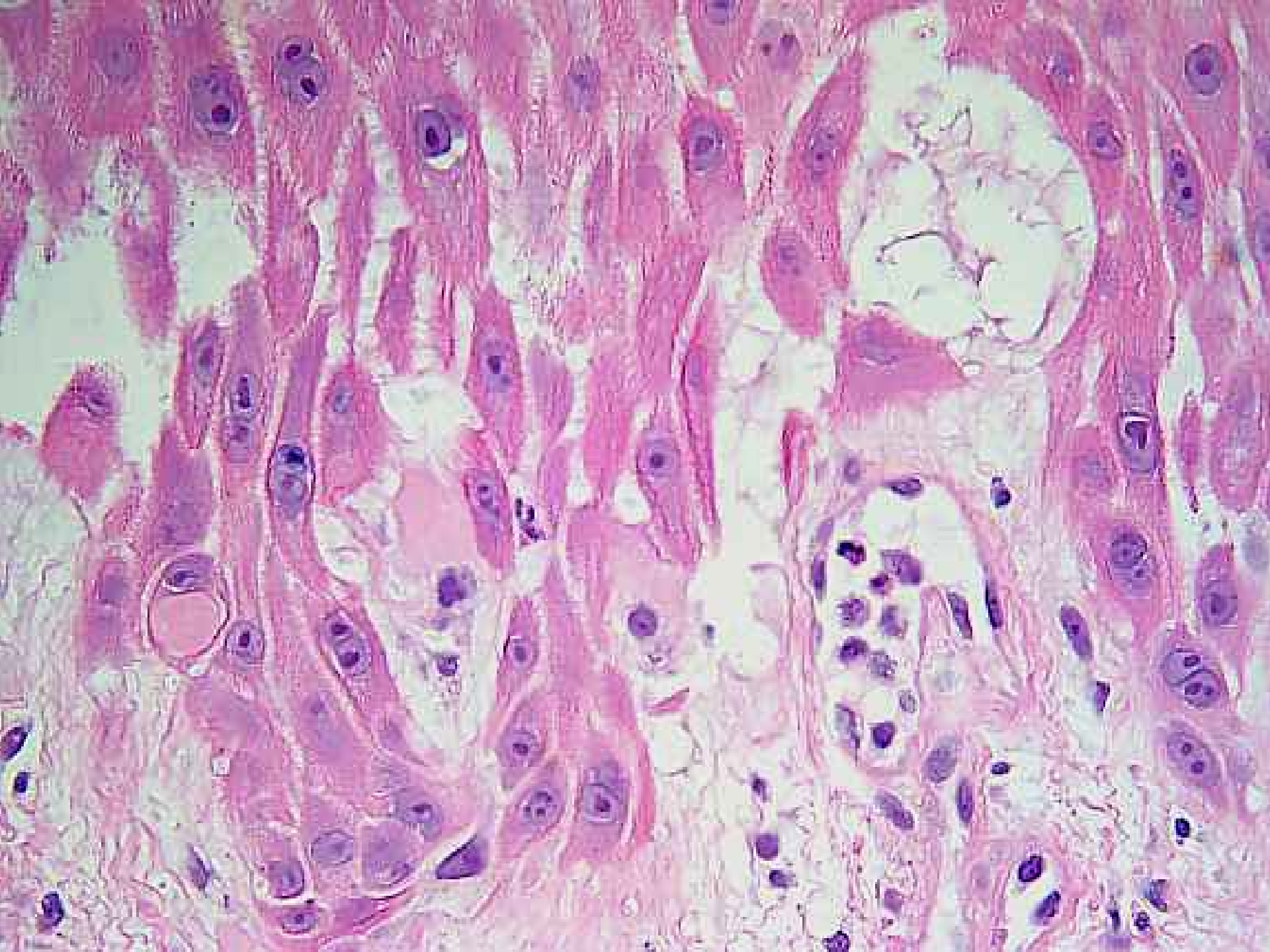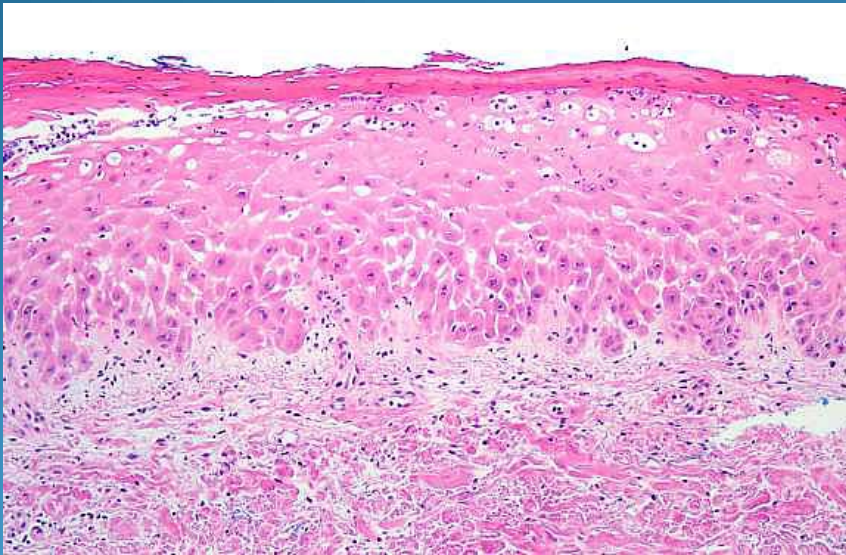


Acrodermatitis Enteropathica

Pearls



- Sharply demarcated area of necrosis in superficial epidermis
- May present with keratinocytic pallor
- Rule out other vitamin deficiencies