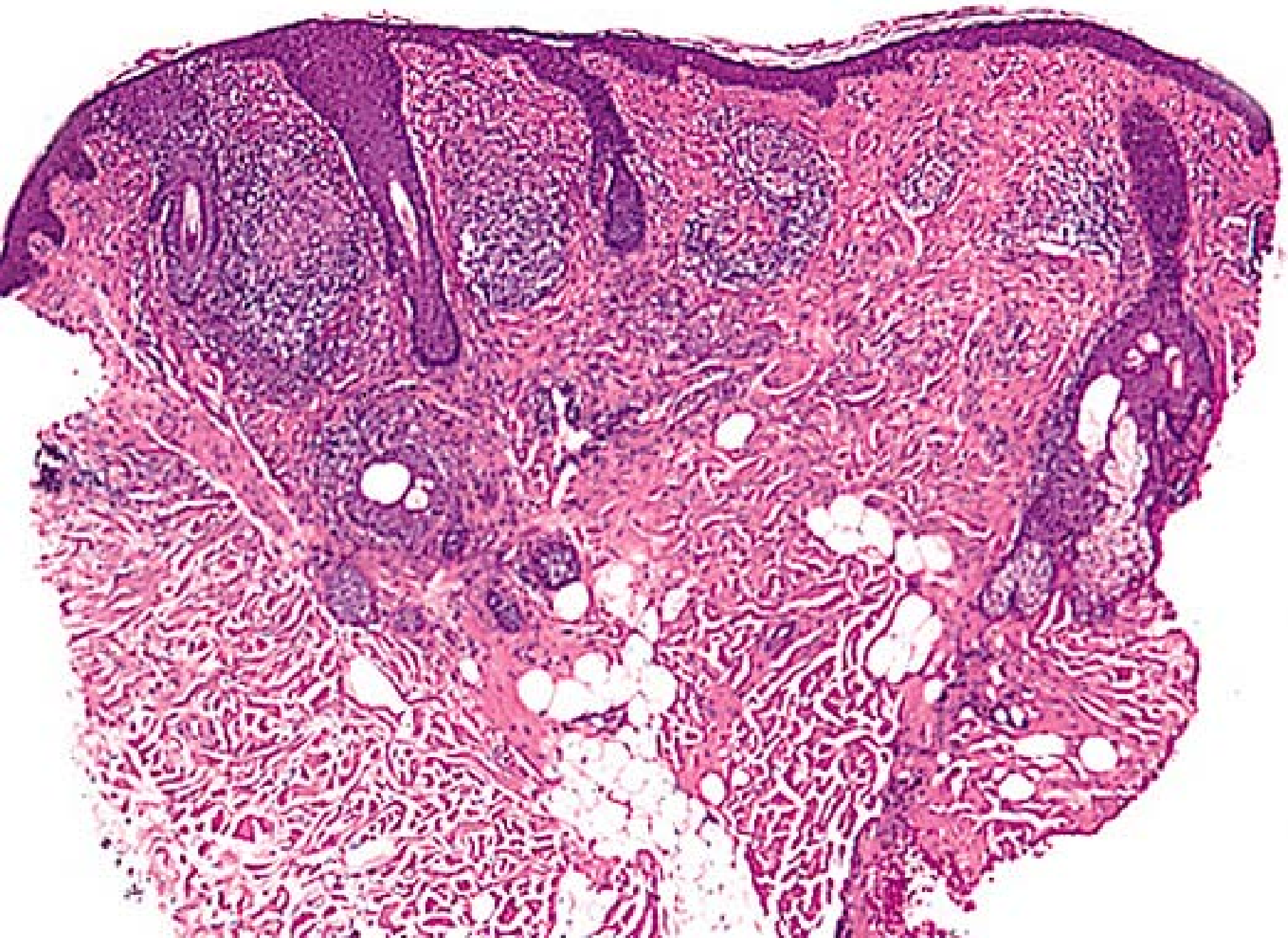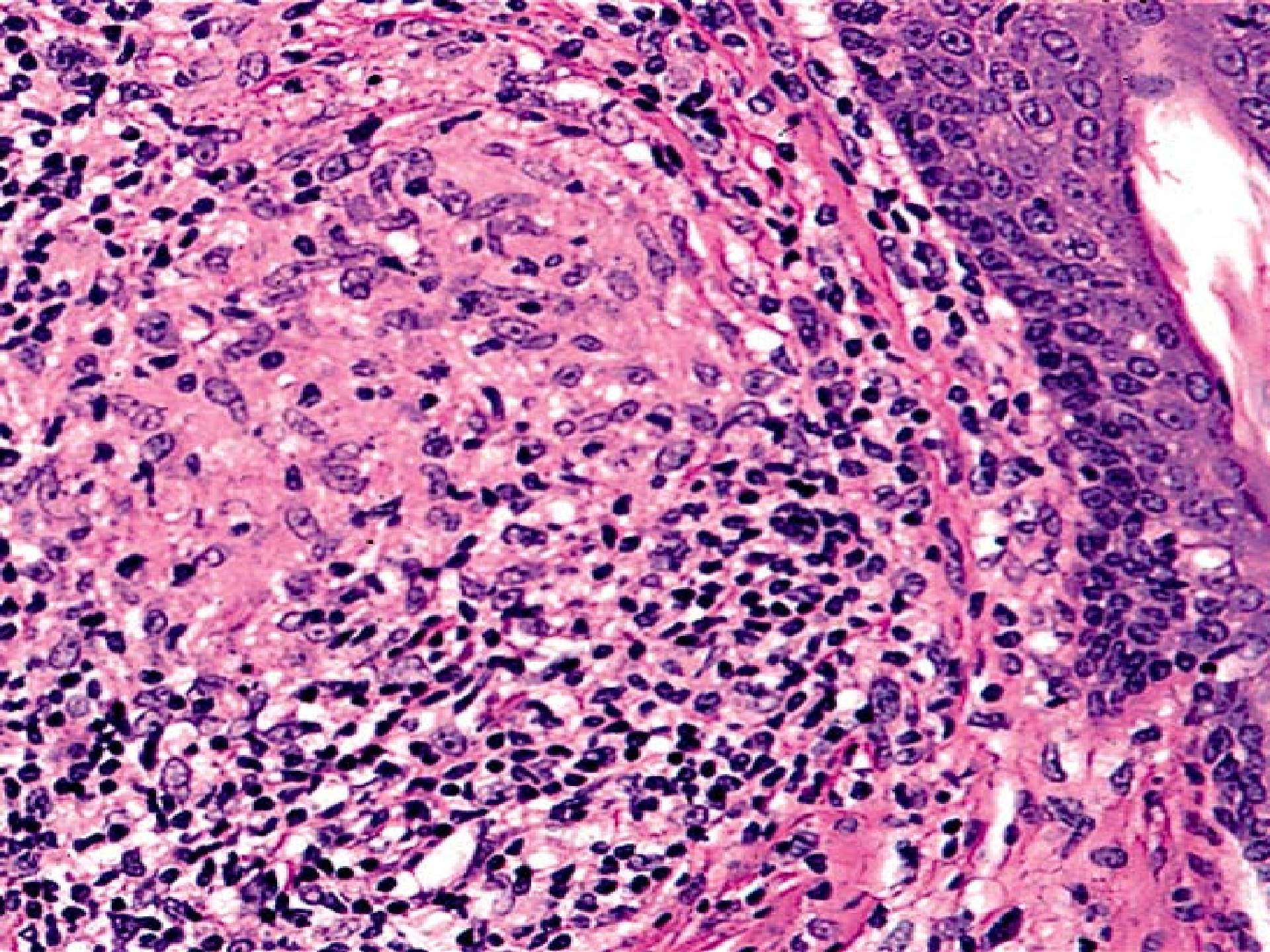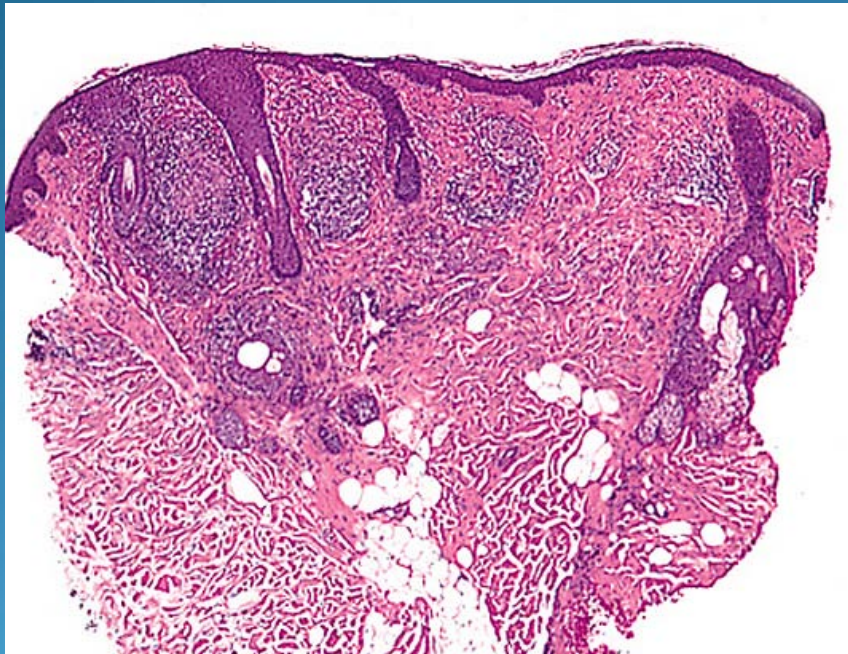


Rosacea

Pearls



- Perifollicular dermatitis
- Variable telangiectasia
- May have non-caseating granulomas
- Rhinophyma with extensive edema