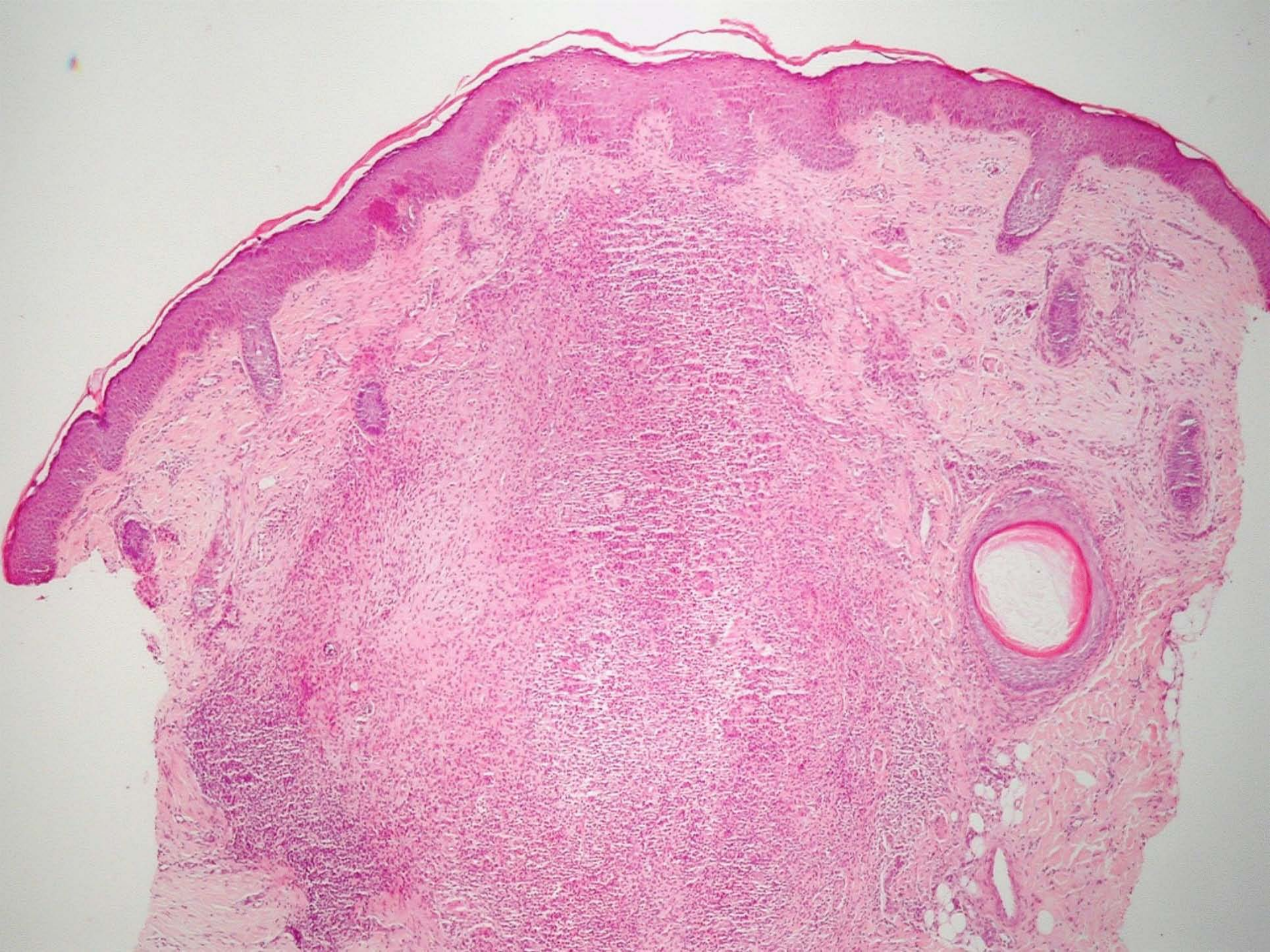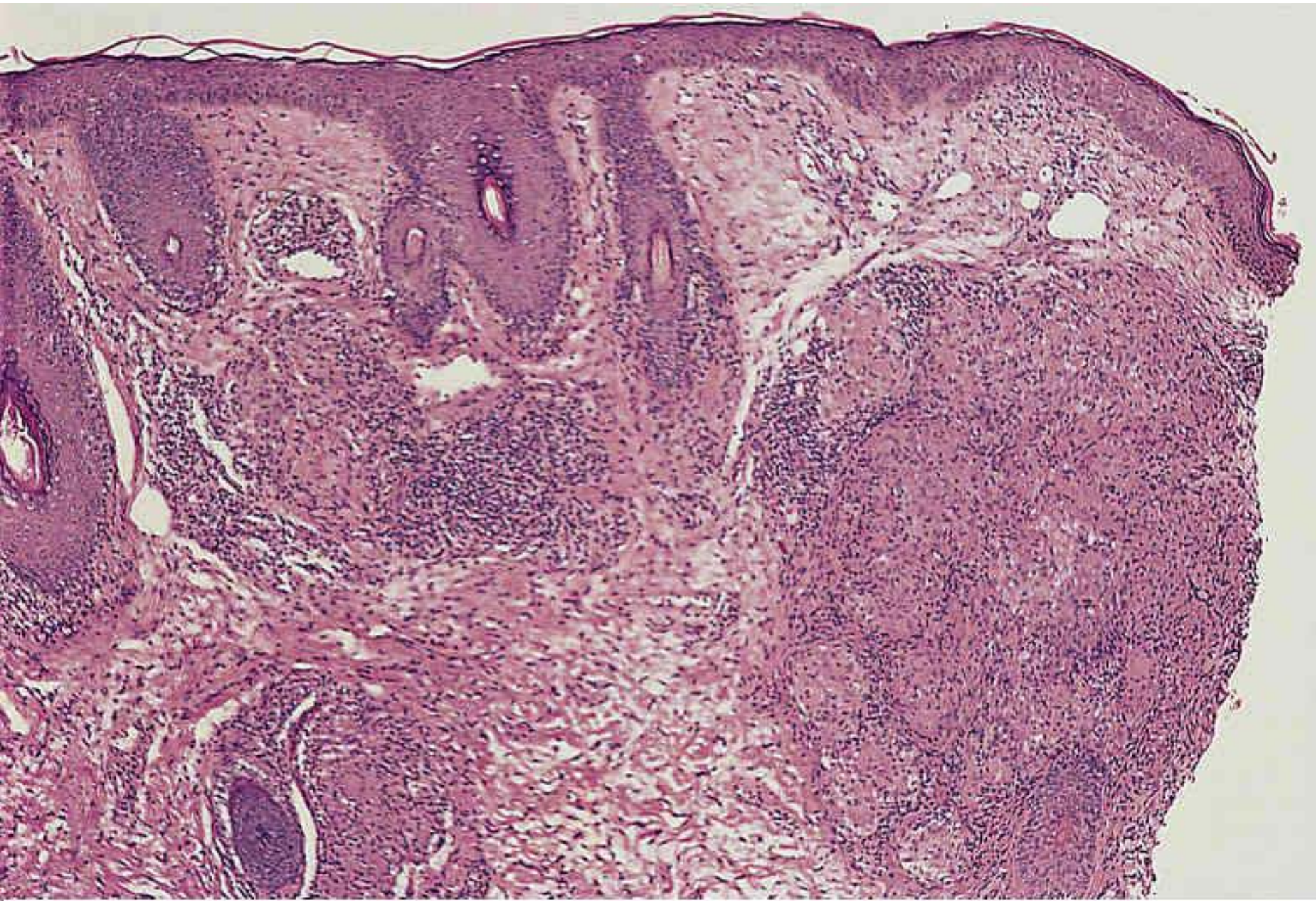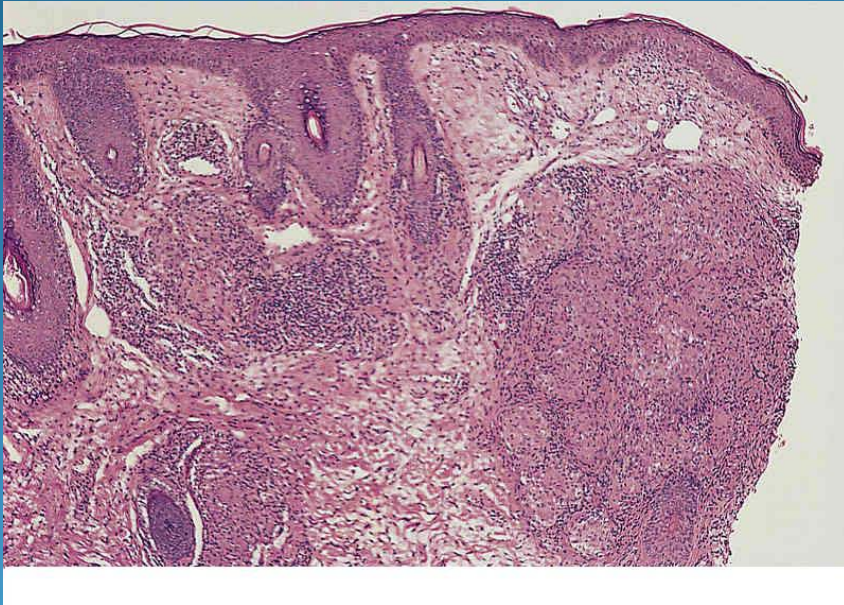


Granulomatous Rosacea (Lupus miliaris disseminatus faciei)

Pearls



- Perifollicular granulomas
- May be caseating or non-caseating
- Usually increased chronic inflammation