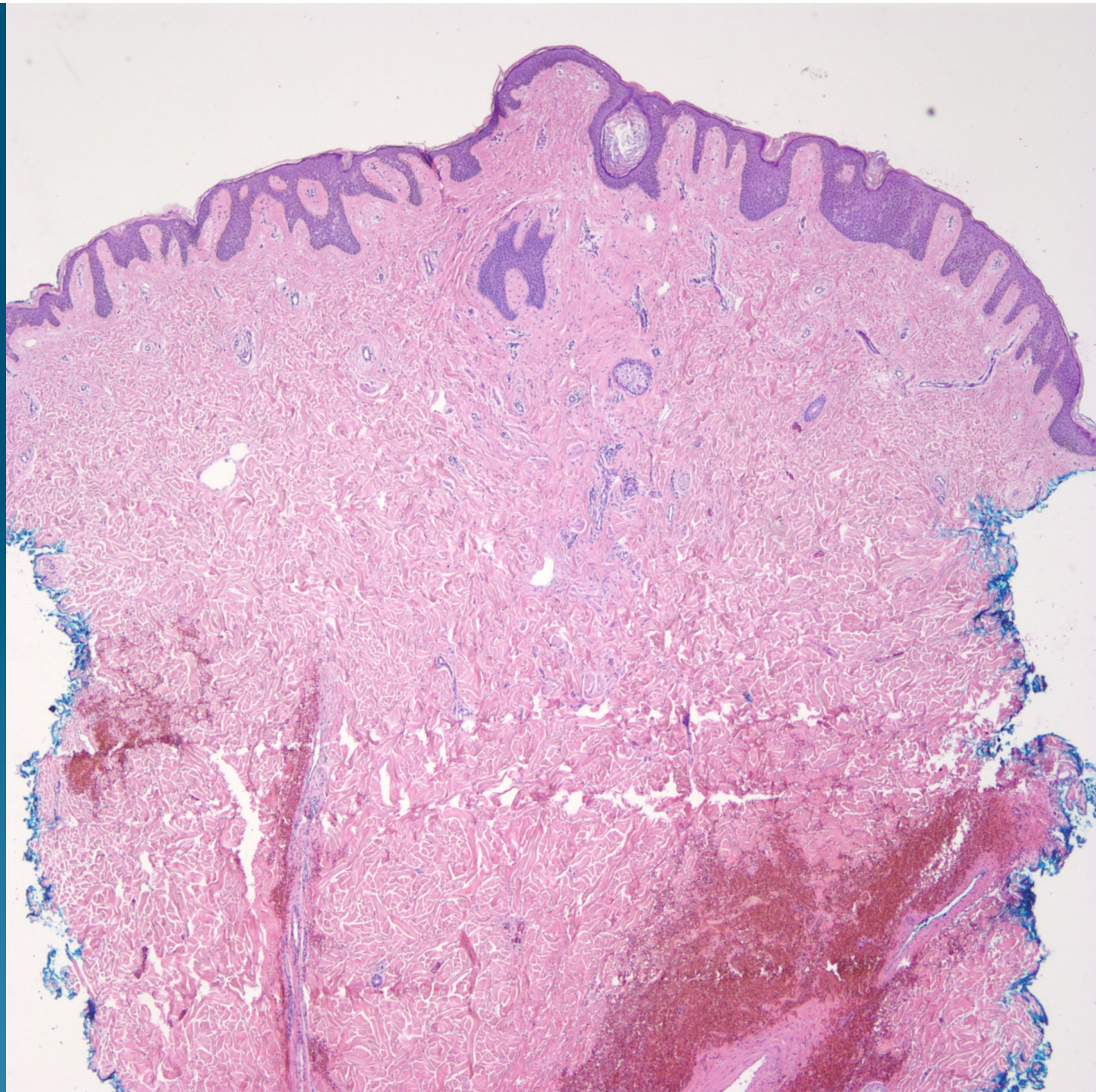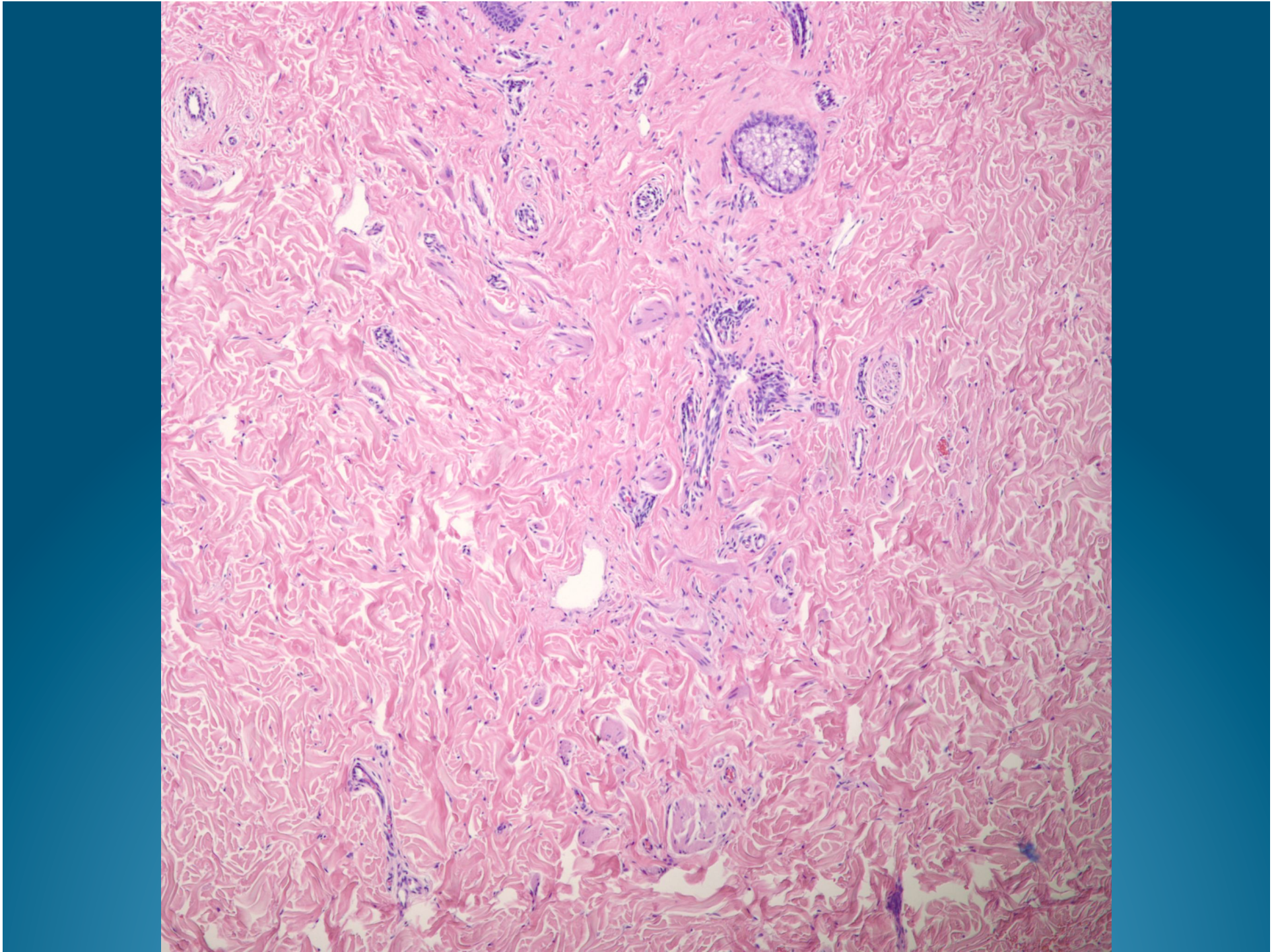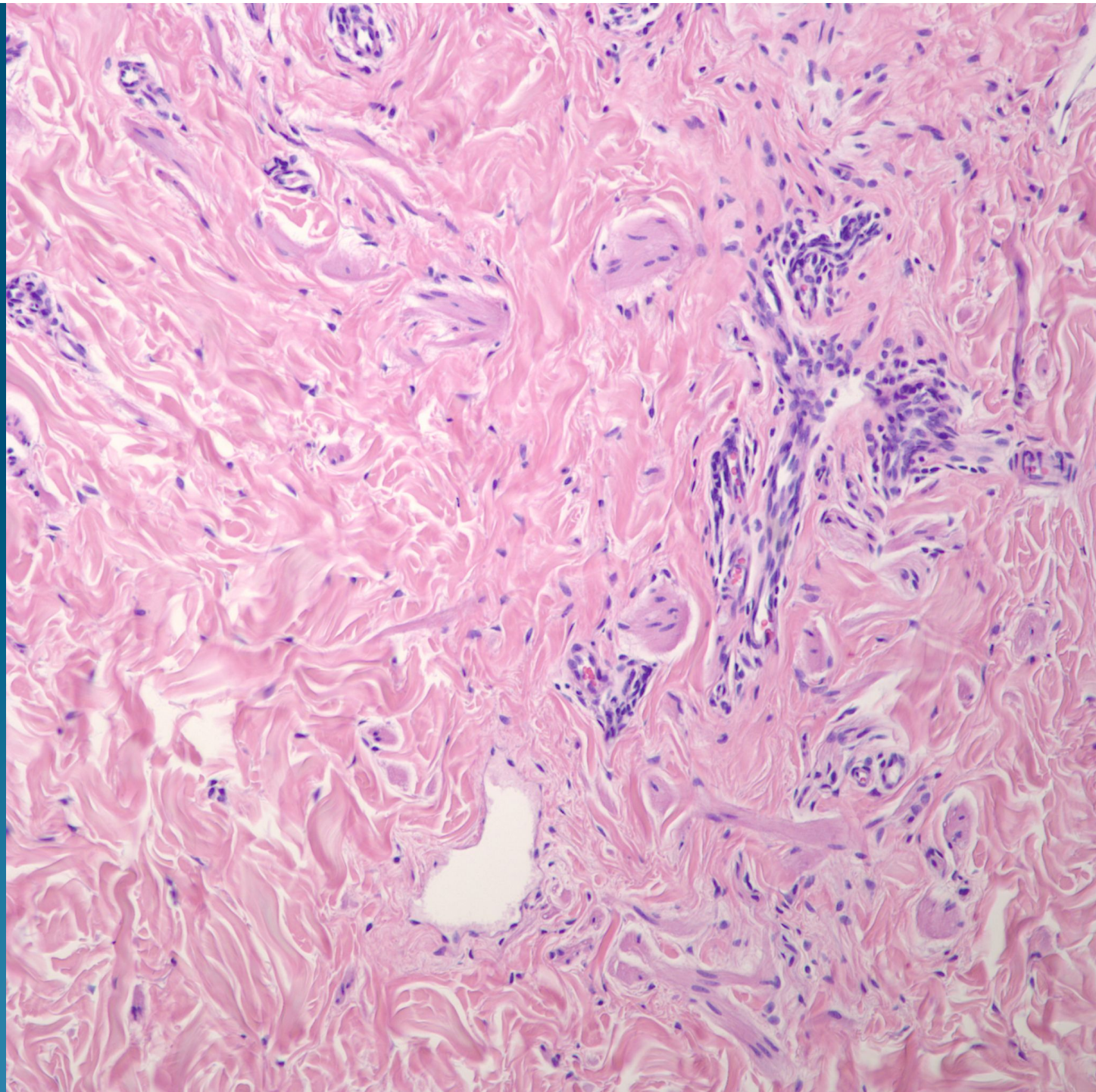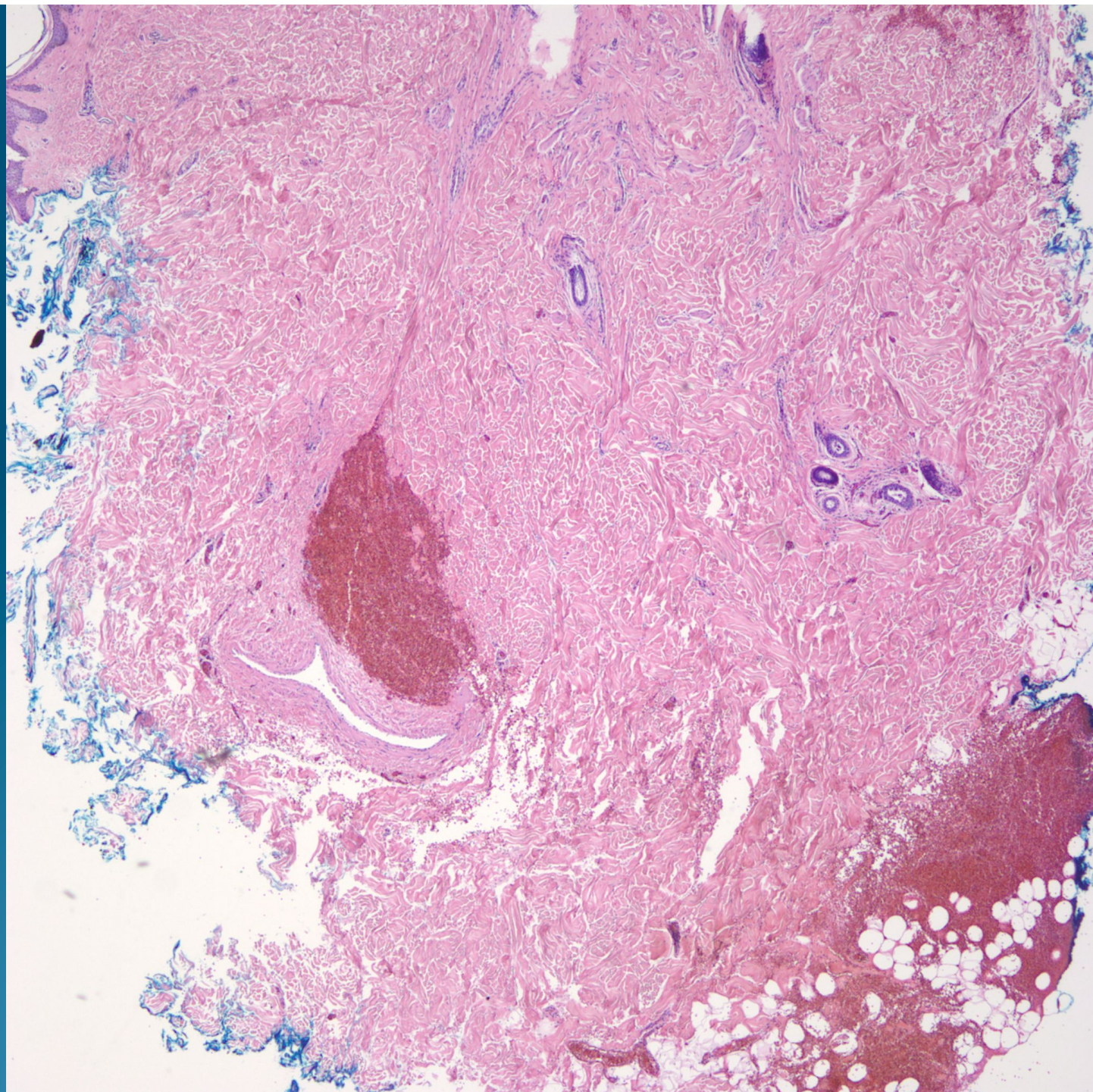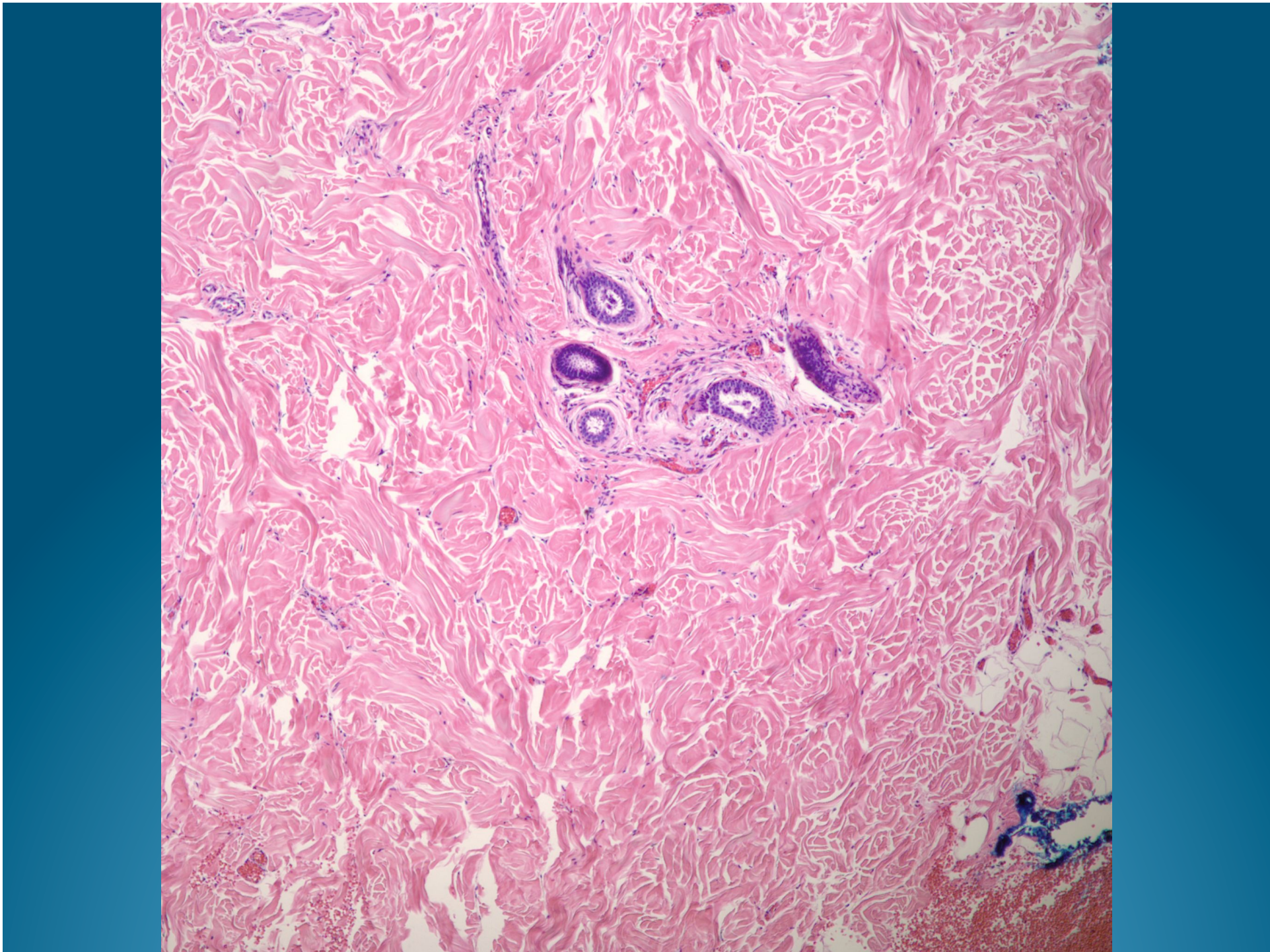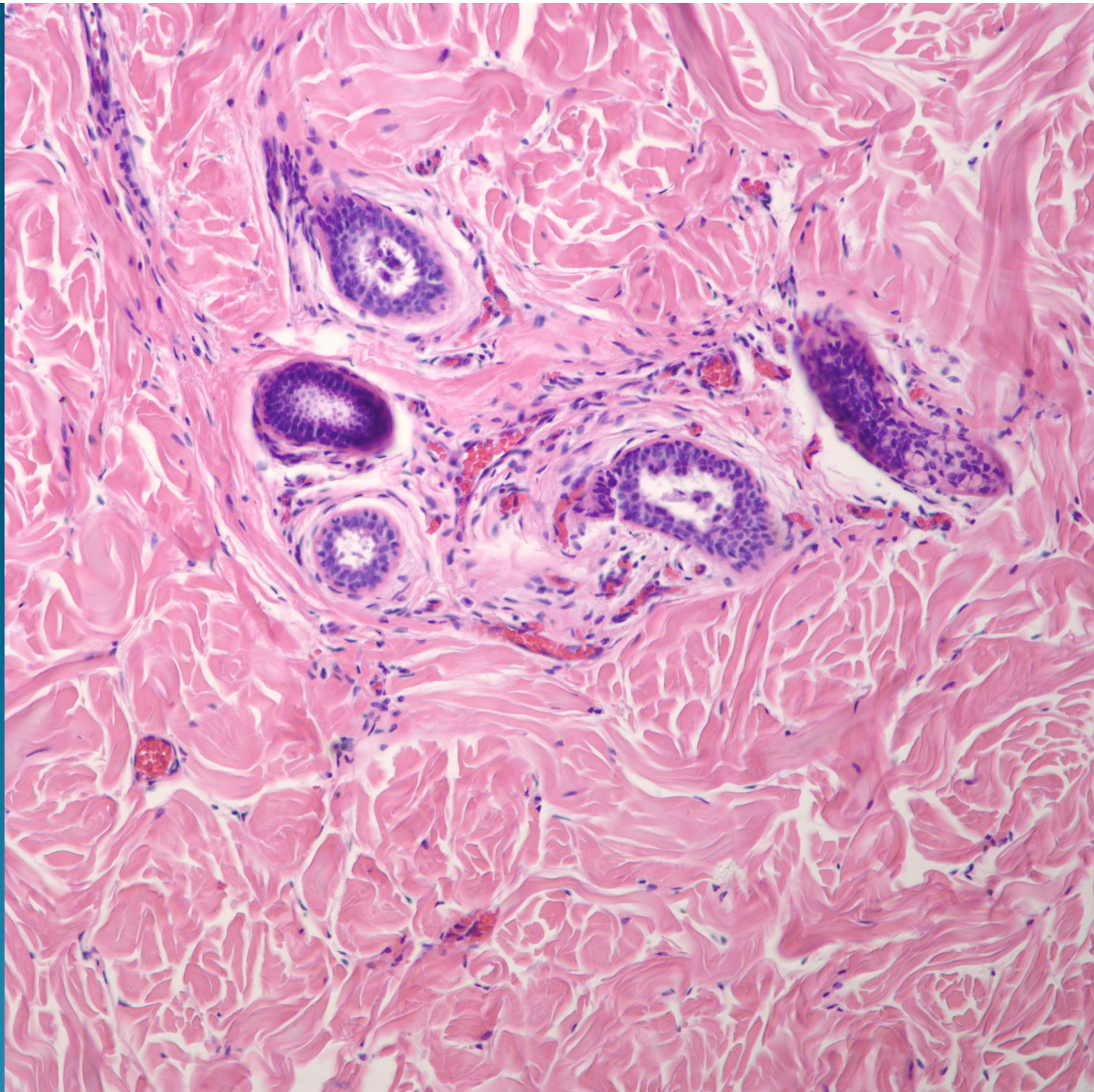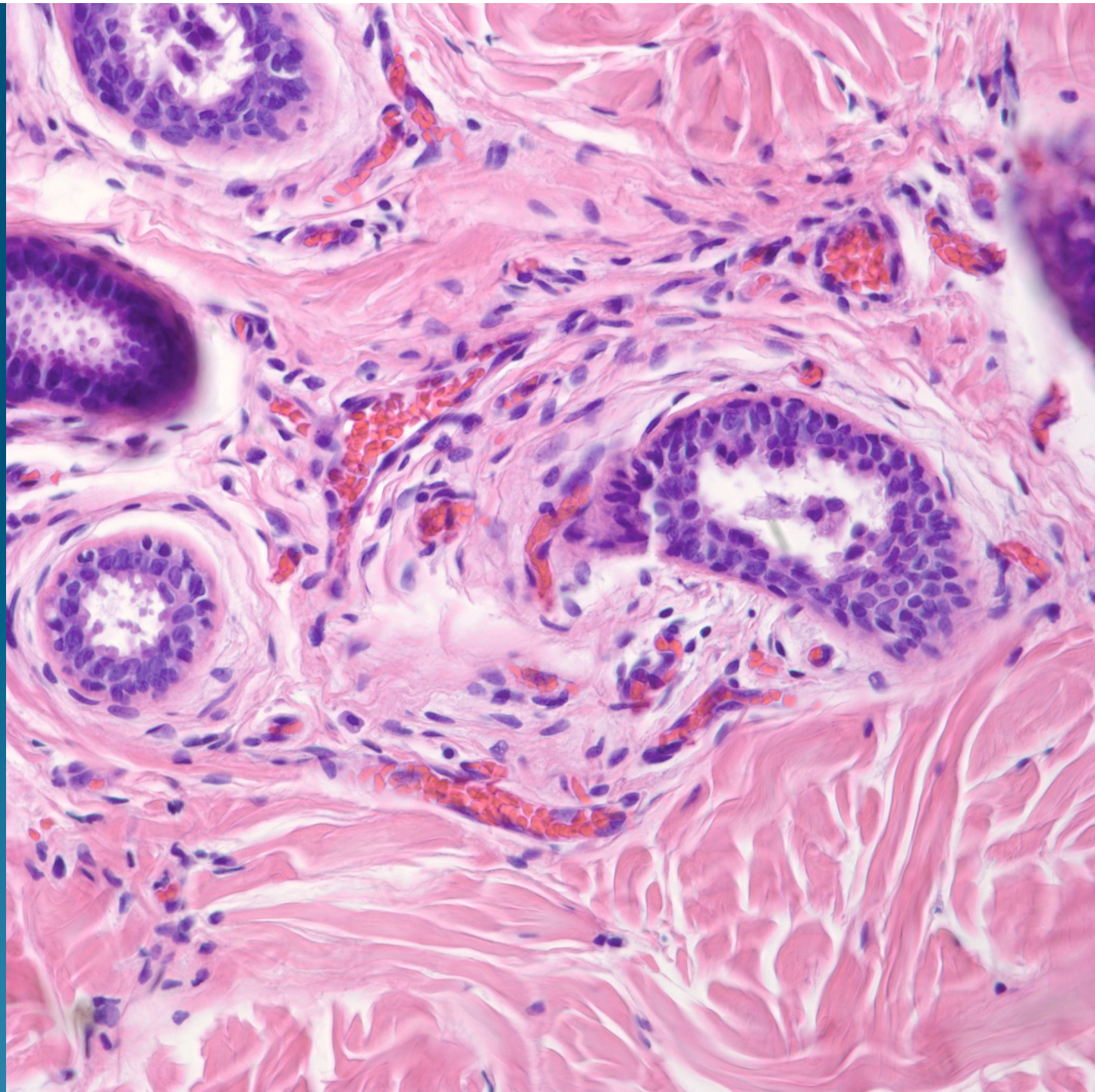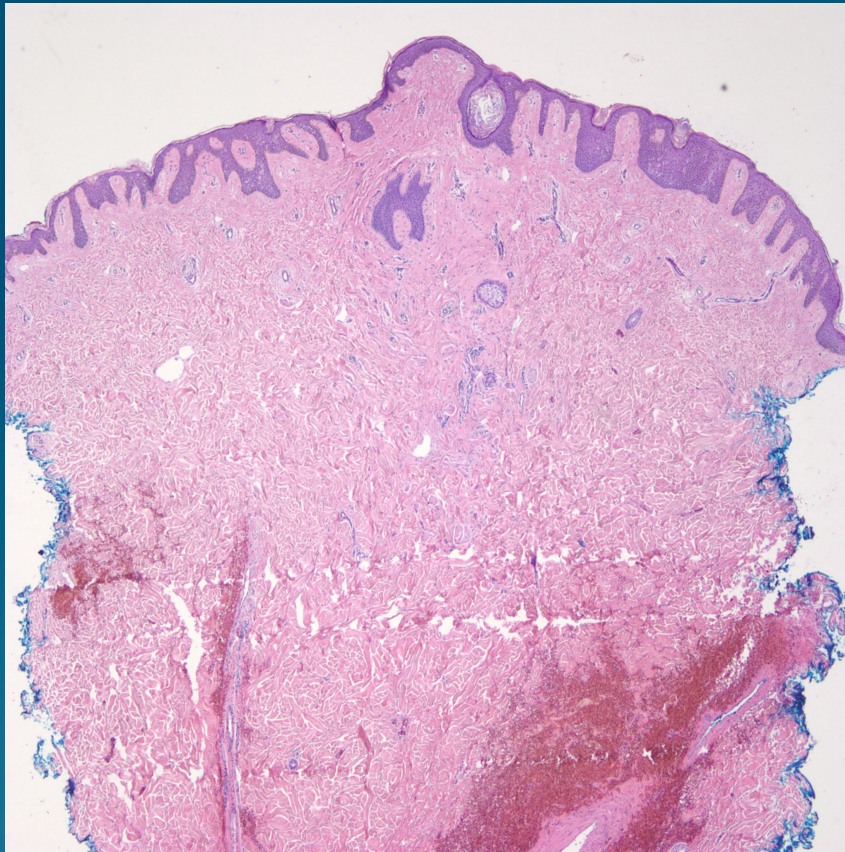


What is the best diagnosis?

- A. Accessory nipple
- B. Accessory tragus
- C. Accessory digit
- D. Syrginoma
- E. Eccrine sweat duct nevus

Accessory Nipple

Pearls



- Slightly polypoid dermal nodule with mixed collection of smooth muscle and variable apocrine ducts
- Look for apocrine snouting to distinguish from eccrine ducts
- Clinical correlation usually within the milk line