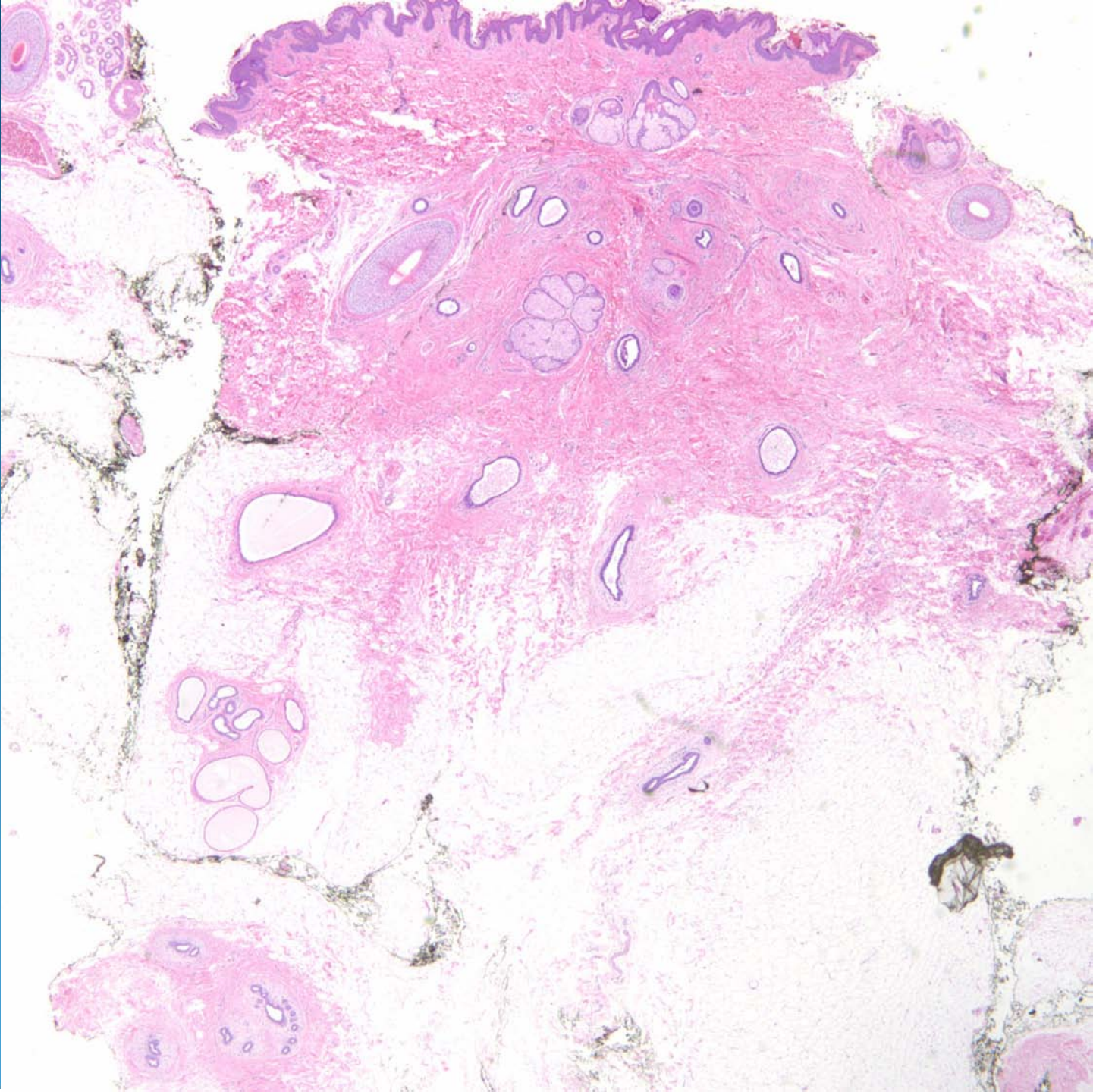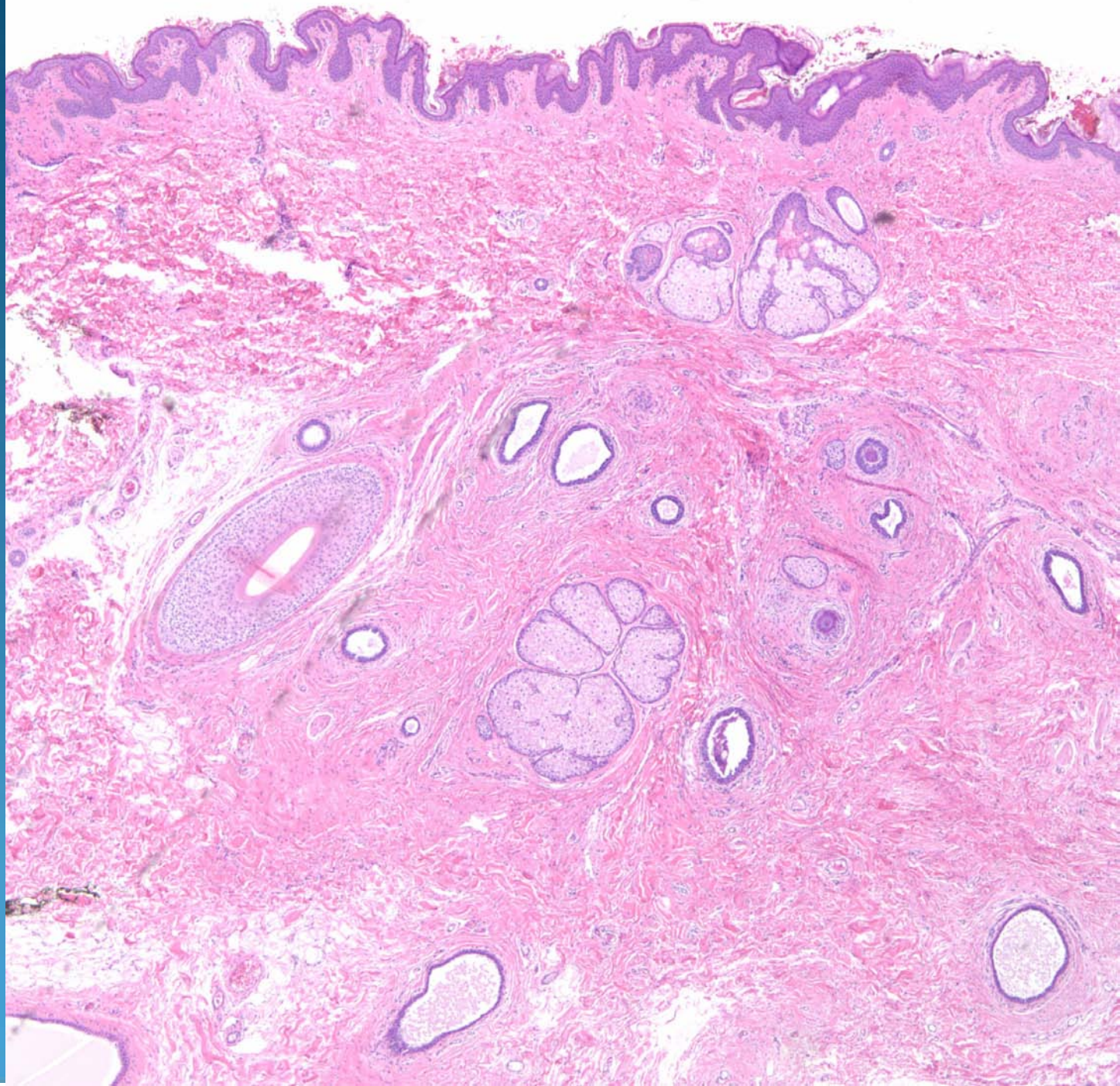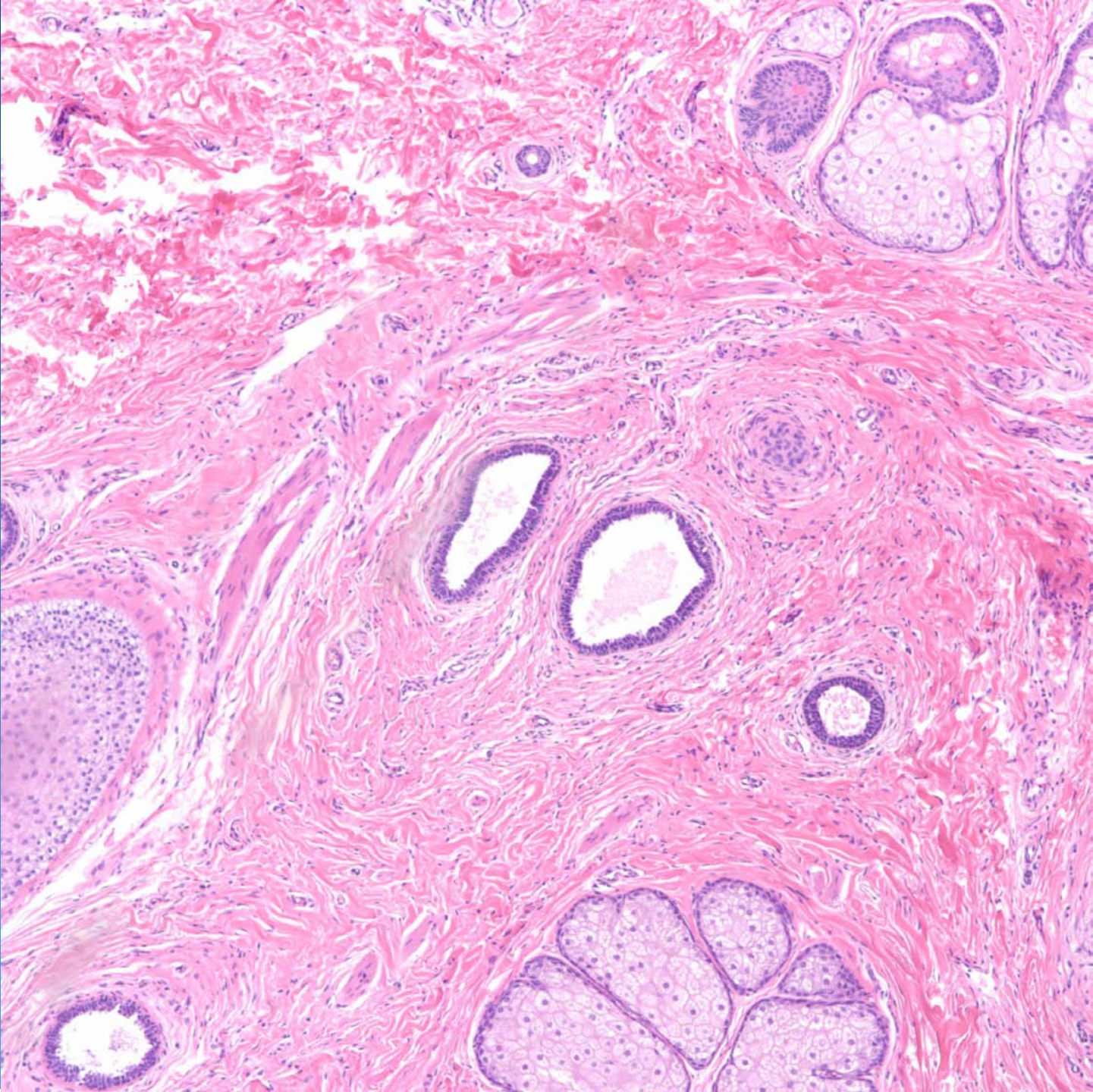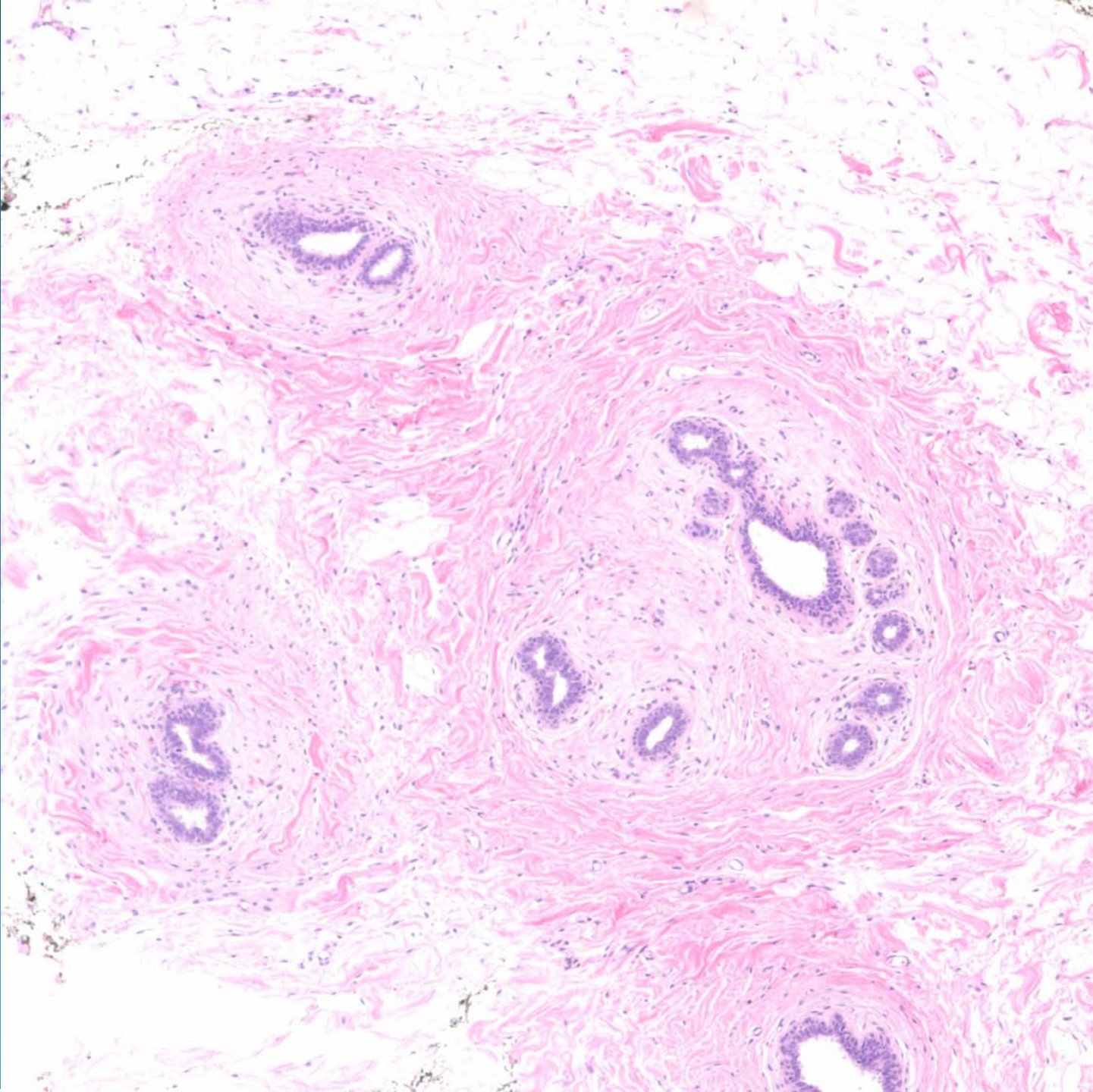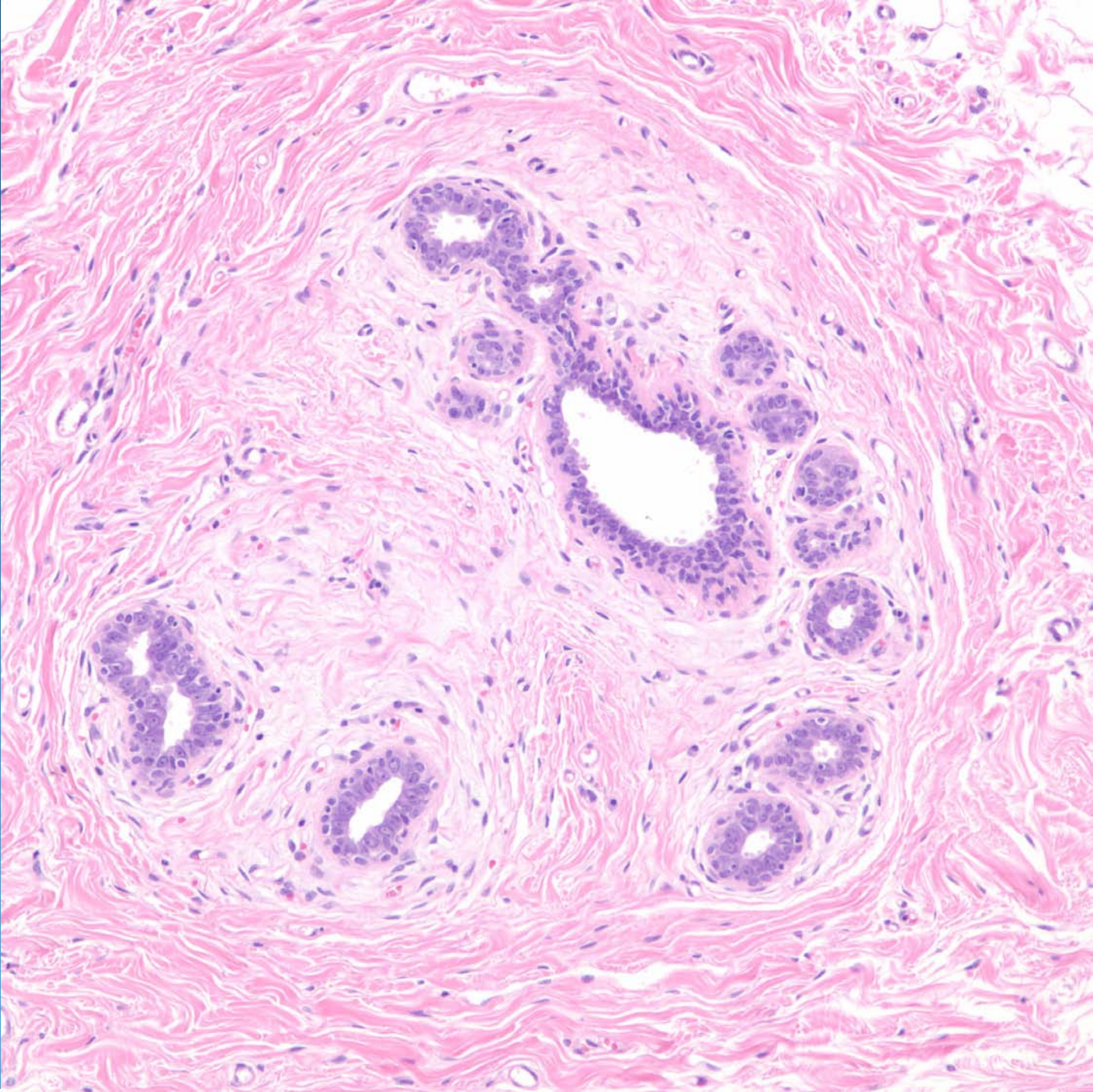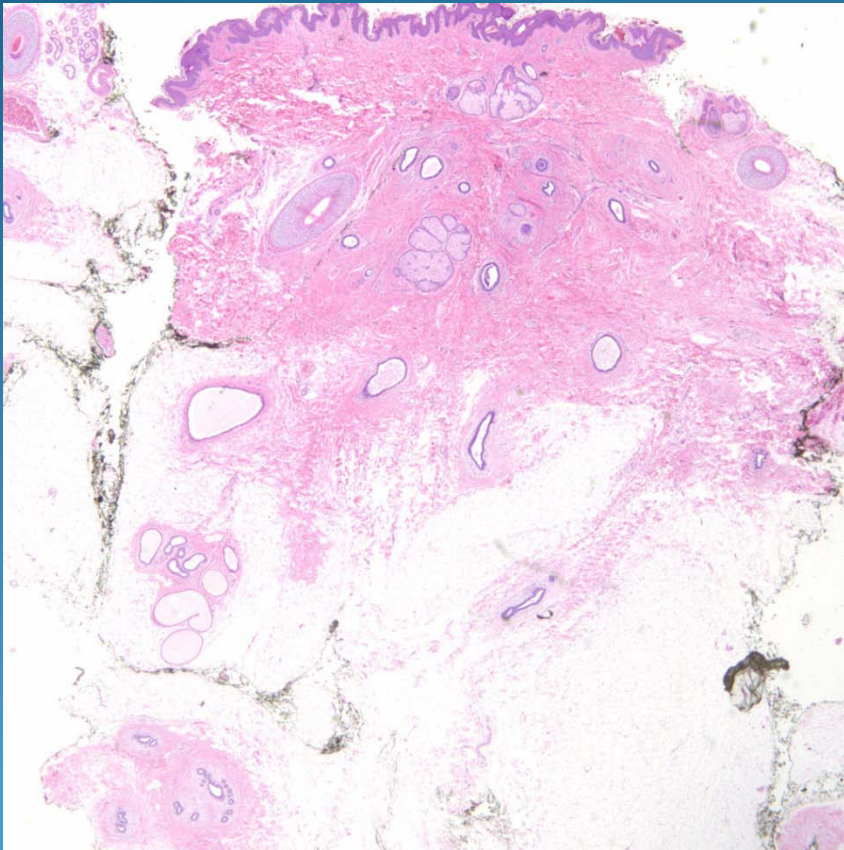


# Accessory Breast Tissue

# Pearls



- Benign breast glandular tissue extending into dermis
- If associated with smooth muscle bundles, consistent with accessory nipple