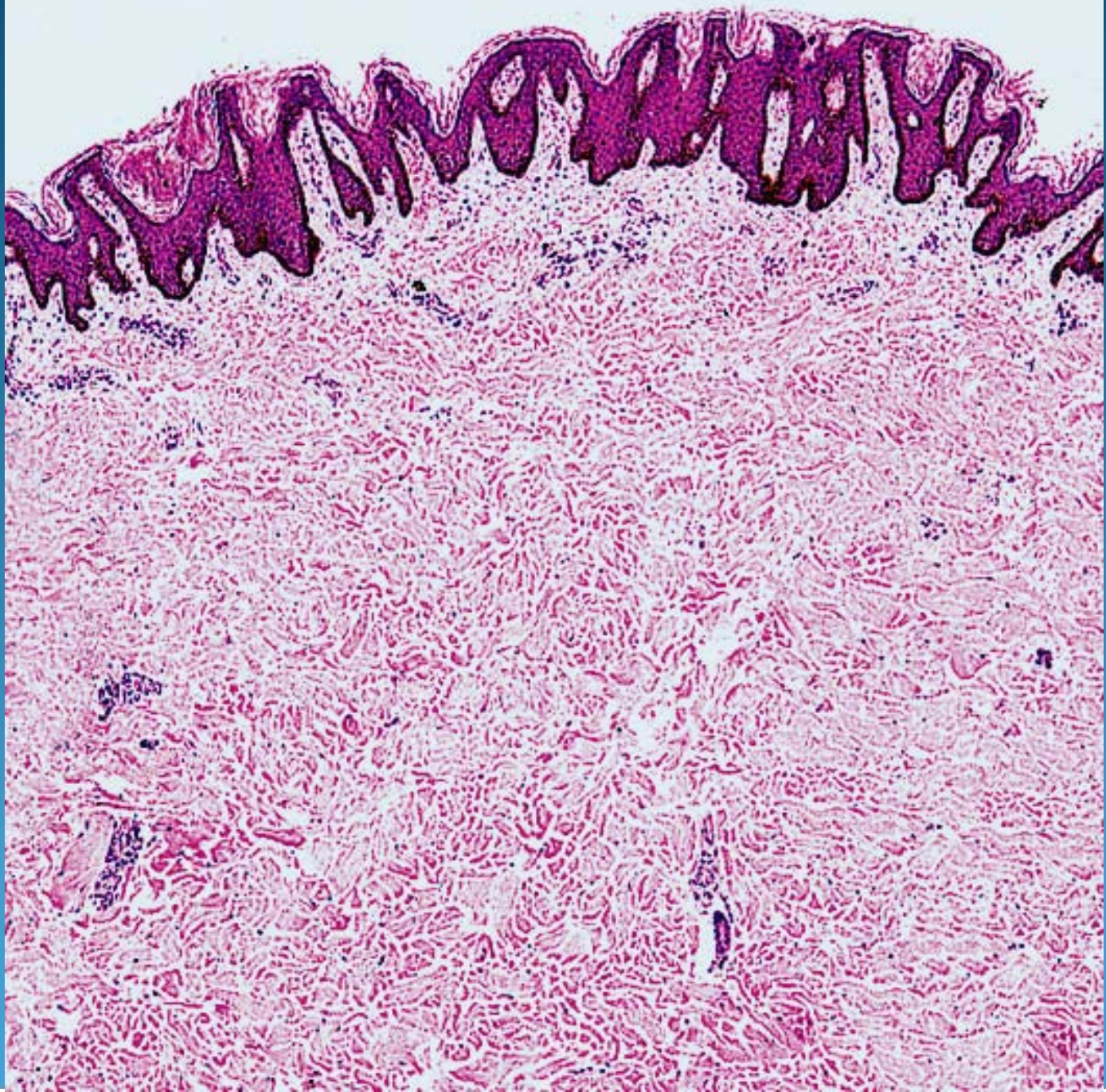
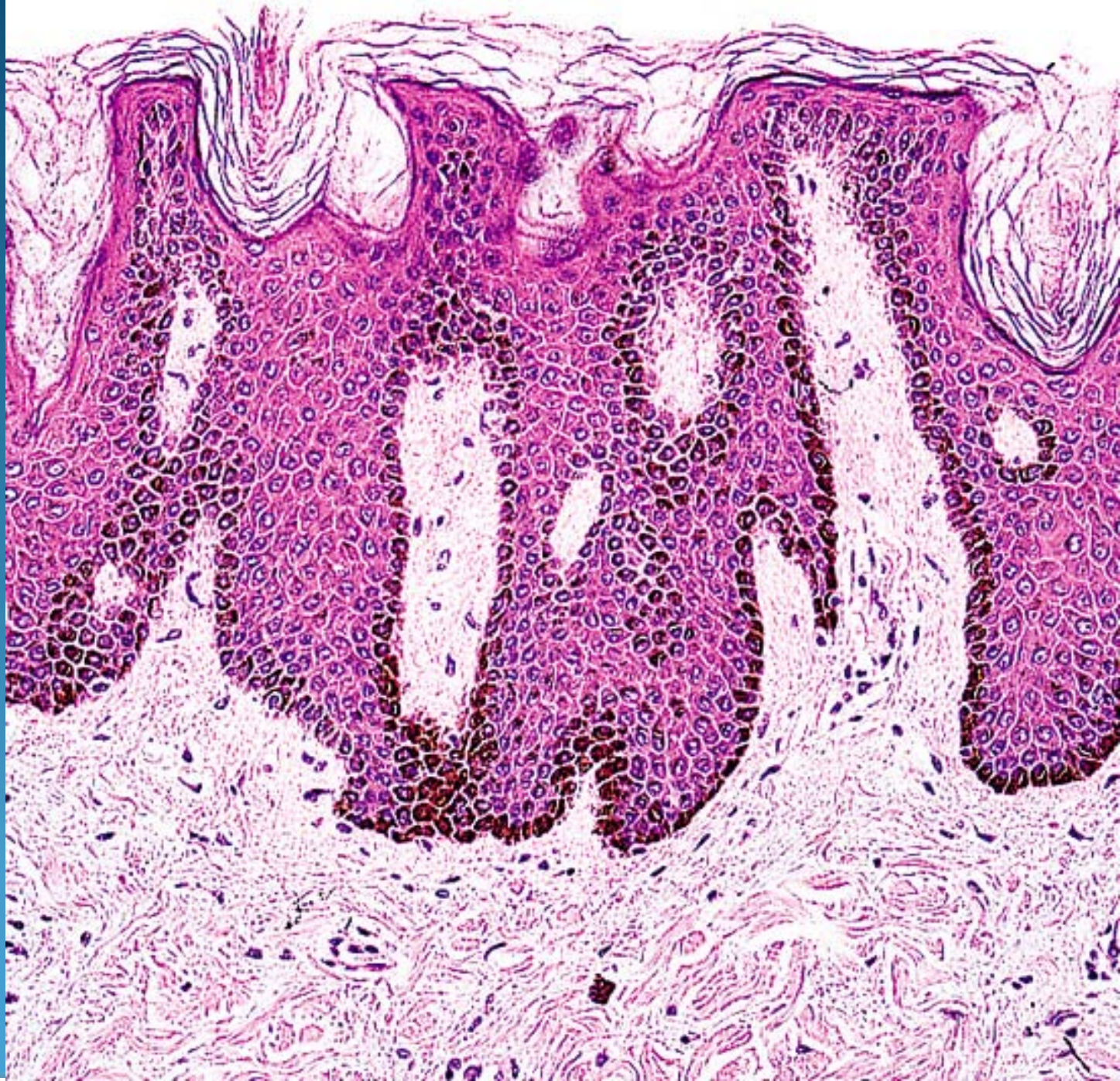
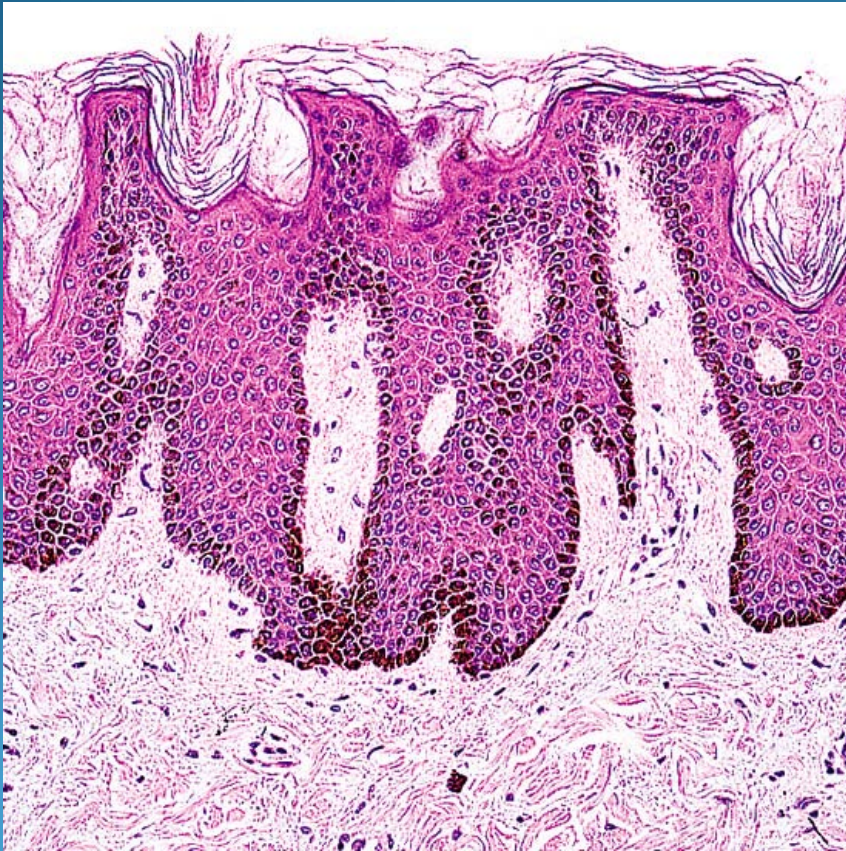




Acanthosis nigricans



# Pearls



- Epidermal hyperplasia with orthokeratosis
- Accentuated melanin pigment within the basal keratinocytes
- Resembles seborrheic keratosis or lentigo