

Noninfectious Vesiculobullous and Vesiculopustular Diseases

Paul K. Shitabata, M.D.
Director of Dermatopathology
Harbor-UCLA Dermatology

What is the location of the blister cavity?

| Disease | Intraepidermal | Subepidermal |
|--------------------|----------------|--------------|
| Friction blister | | |
| Second degree burn | | |
| Suction blister | | |
| Fogo selvagem | | |

Answers

| Disease | Intraepidermal | Subepidermal |
|--------------------|----------------|--------------|
| Friction blister | + | |
| Second degree burn | | Usually + |
| Suction blister | | + |
| Fogo selvagem | + Subcorneal | |

Histopathologic patterns associated with Grover's disease include all except:

- Bullous pemphigoid
- Hailey-Hailey disease
- Darier's disease
- Pemphigus vulgaris
- Pemphigus foliaceus

Answer

- Bullous pemphigoid

Pertinent histopathological differential diagnoses for graft versus host disease include all except:

- Eruption of lymphocyte recovery
- Erythema multiforme
- Lupus erythematosus
- Drug associated linear IgA disease
- Lichen planus

Answer

- Drug associated linear IgA disease

Location of inflammatory cells?

| Disease | DEJ | Intra-epidermal | Stratum corneum |
|----------------------|-----|-----------------|-----------------|
| Miliaria rubra | | | |
| Miliaria profunda | | | |
| Miliaria crystallina | | | |

Answers

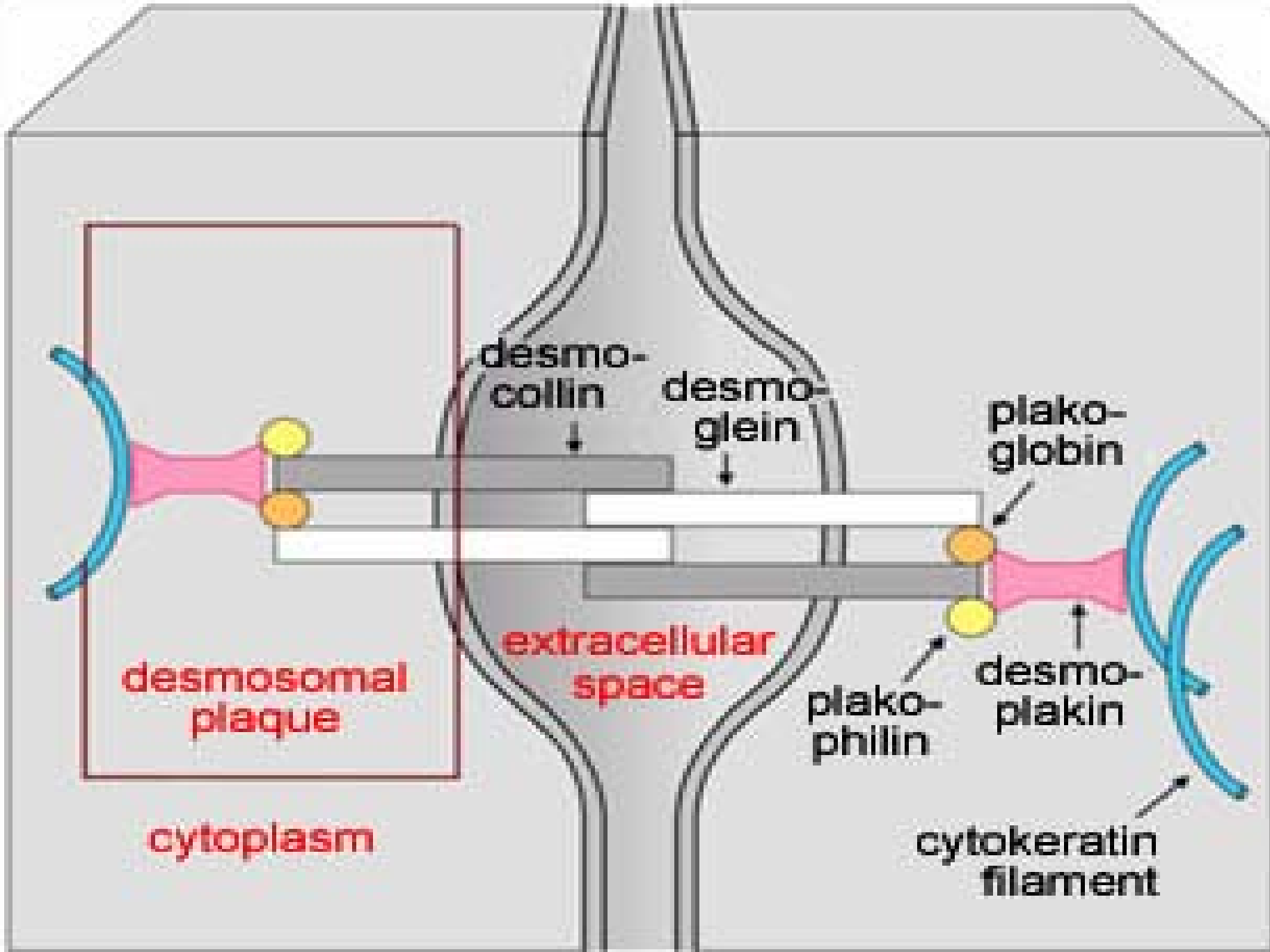
| Disease | DEJ | Intra-epidermal | Stratum corneum |
|----------------------|-----|-----------------|-----------------|
| Miliaria rubra | | + | |
| Miliaria profunda | + | | |
| Miliaria crystallina | | | + |

Target Antigen in Pemphigus

| Disease | Desmoglein 1 | Desmoglein 3 |
|--------------------------|--------------|--------------|
| Pemphigus vulgaris | | |
| Pemphigus foliaceus | | |
| Paraneoplastic pemphigus | | |
| Drug-induced pemphigus | | |
| IgA Pemphigus | | |

Answers

| Disease | Desmoglein 1 | Desmoglein 3 |
|--------------------------|--------------|--------------|
| Pemphigus vulgaris | | + |
| Pemphigus foliaceus | + | |
| Paraneoplastic pemphigus | + | + |
| Drug-induced pemphigus | + | + |
| IgA Pemphigus | + | + |



desmo-
collin

desmo-
glein

plako-
globin

desmosomal
plaque

extracellular
space

plako-
philin

desmo-
plakin

cytoplasm

cyokeratin
filament

Target Antigens in Subepidermal Bullous Diseases

| Disease | BPAG1 (BP230) | BPAG2 (BP180) | S6beta4 integrin | Laminin 5 | Type VII collagen |
|---------|------------------|------------------|---------------------|--------------|-------------------------|
| BP | | | | | |
| CP | | | | | |
| EBA | | | | | |
| PG | | | | | |
| LABD | | | | | |

Answers

| Disease | BPAG1 (BP230) | BPAG2 (BP180) | S6beta4 integrin | Laminin 5 | Type VII collagen |
|----------------|--------------------------|--------------------------|-----------------------------|----------------------|------------------------------|
| BP | + | + | | | |
| CP | | + | +(ocular) | +(anti-epi) | |
| EBA | | | | | + |
| PG | | + | | | |
| LABD | | + | | | |

