Dermatopathology Slide Review Part 89

Paul K. Shitabata, M.D.
Dermatopathology Institute

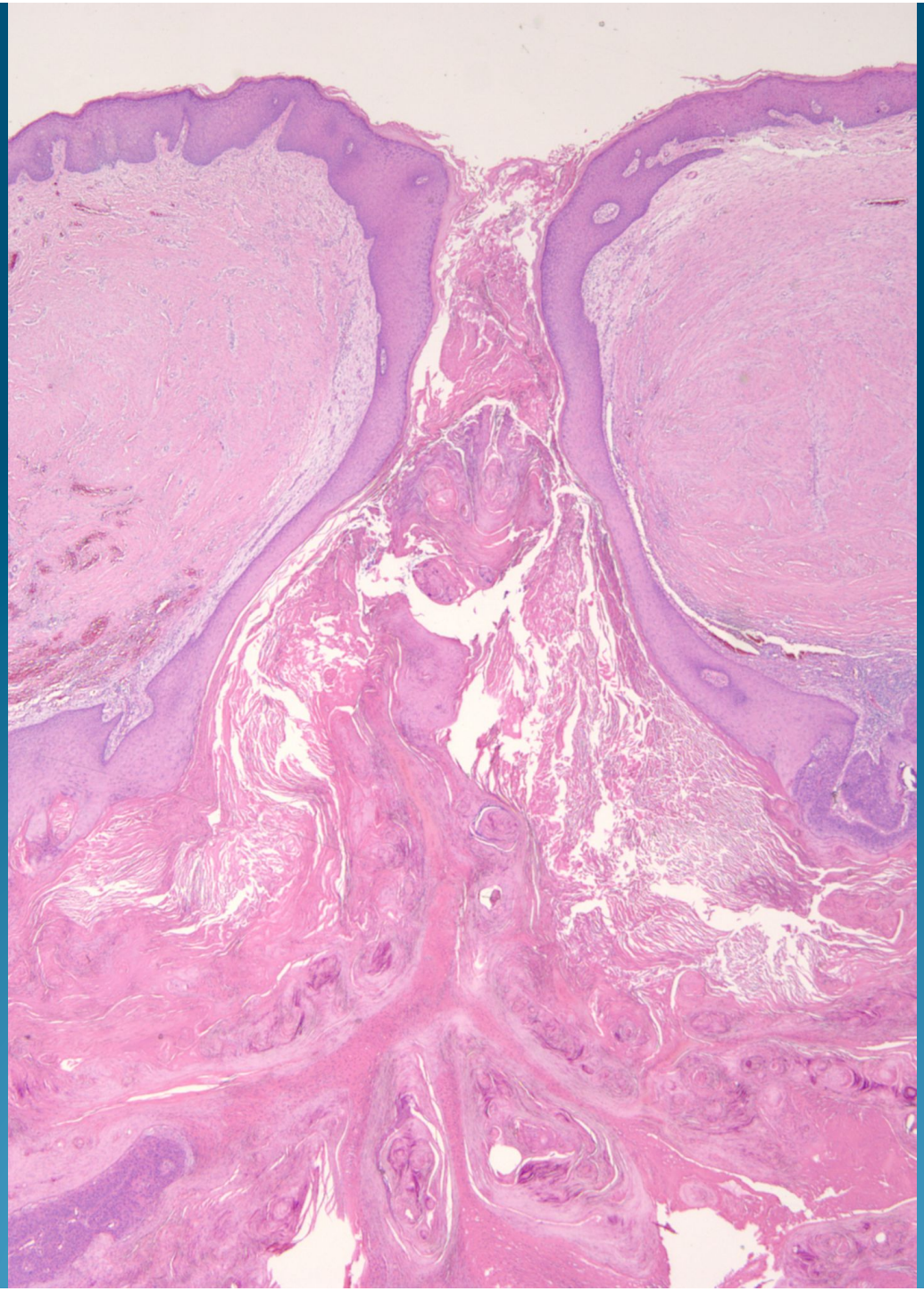

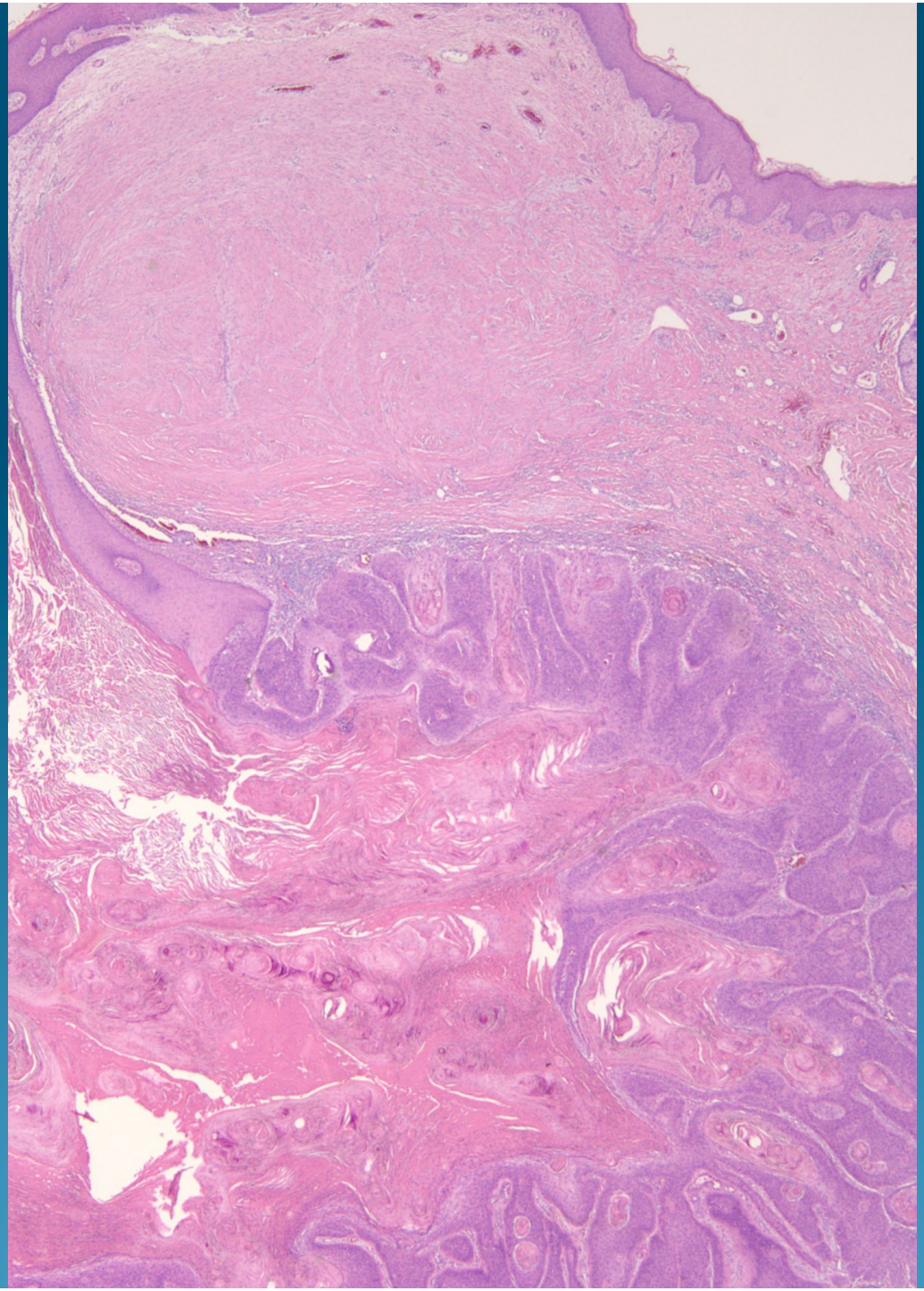

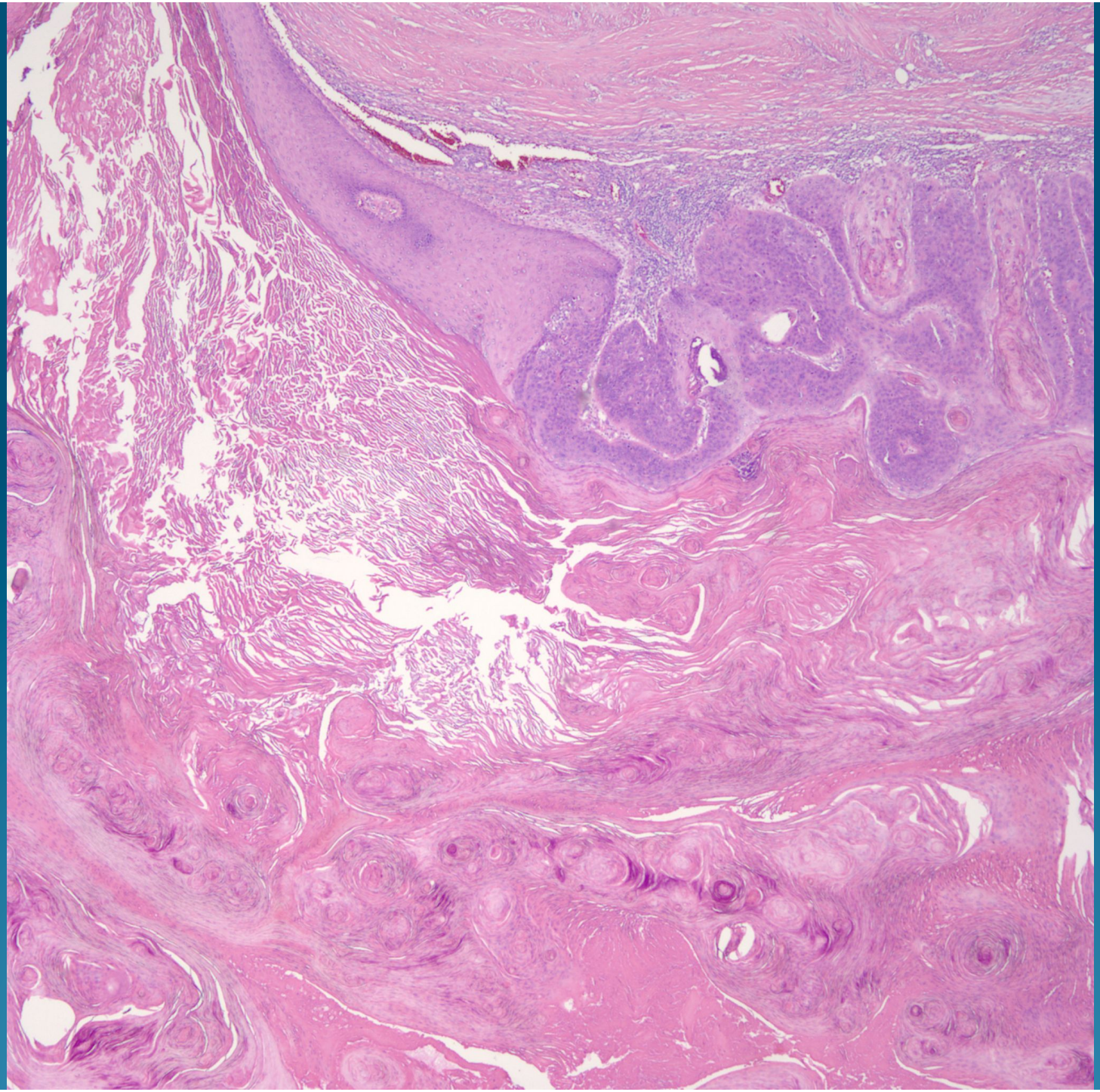

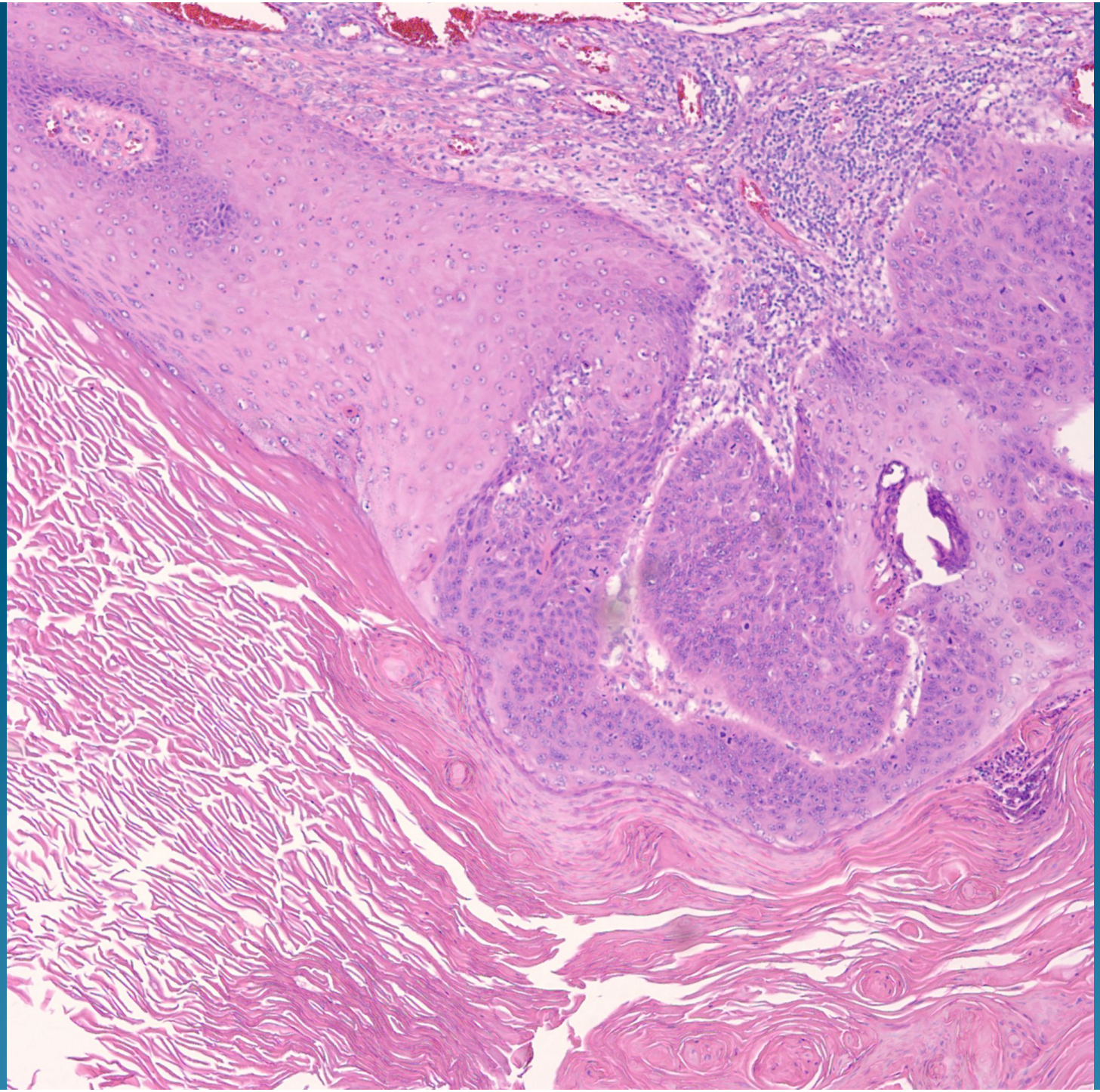

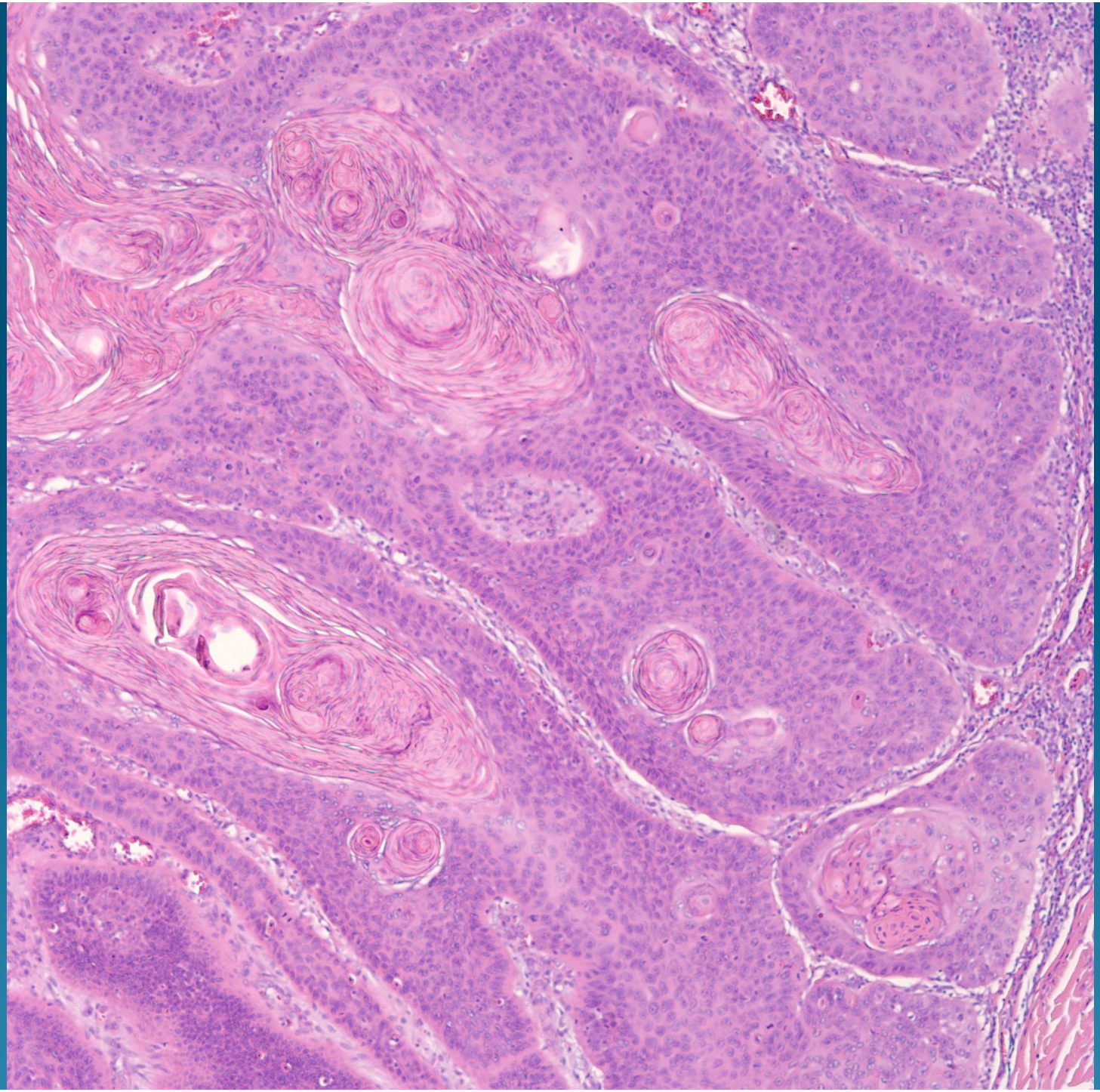

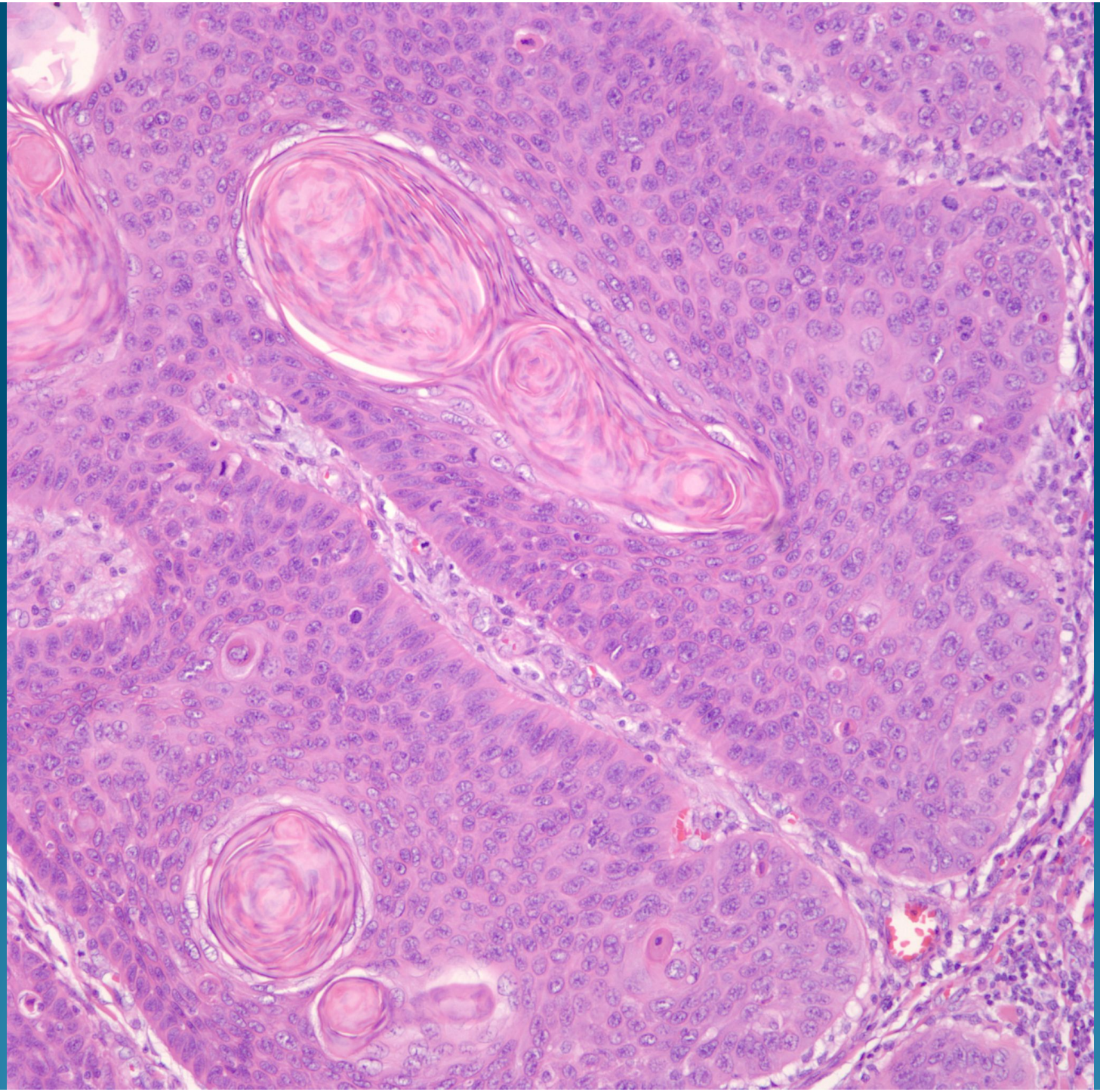

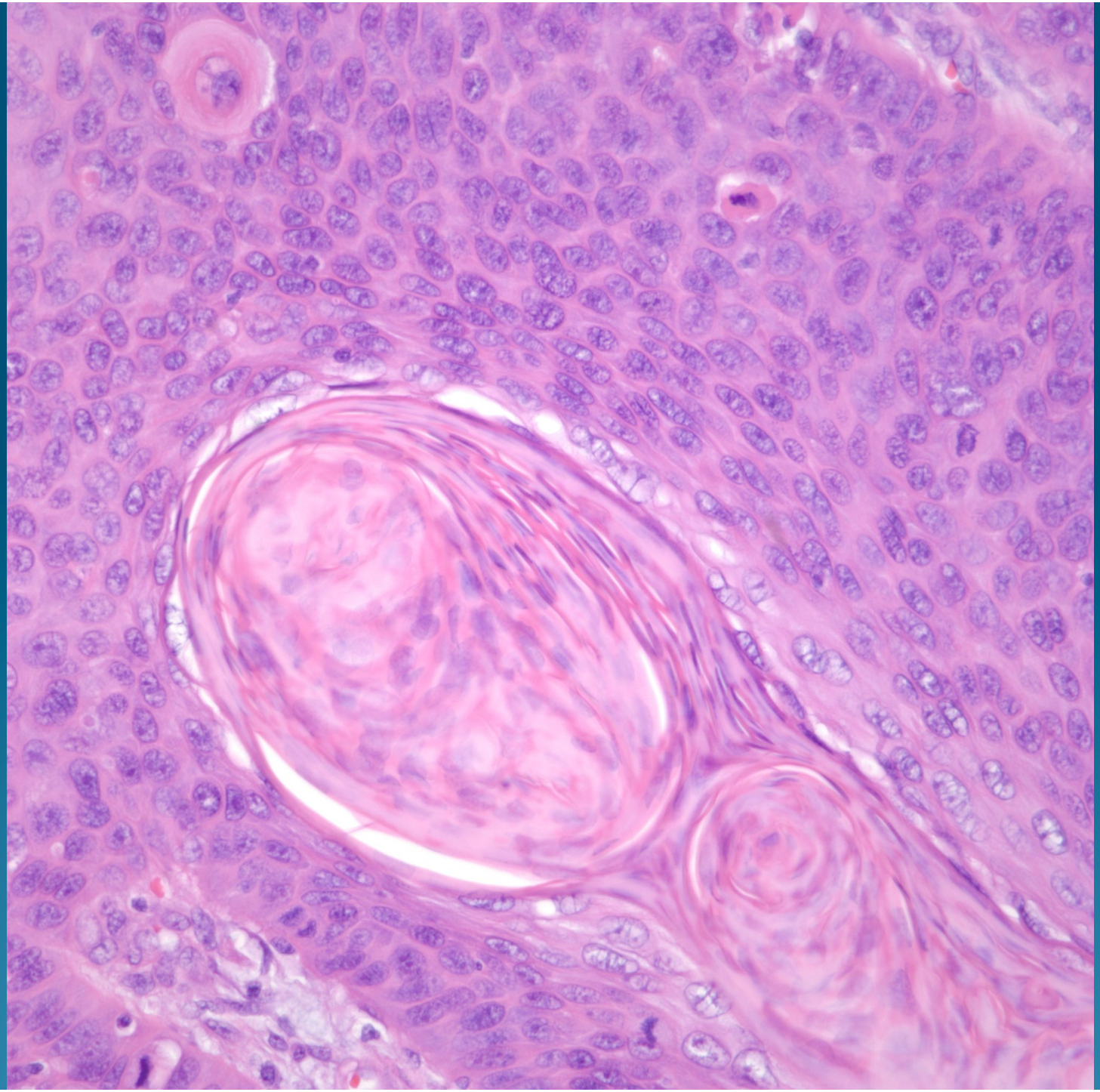

What is the best diagnosis?

A. Folliculocentric basal cell carcinoma
B. Nodular hidradenocarcinoma
C. Invasive squamous cell carcinoma
D. Pilomatrical carcinoma
E. Sebaceous carcinoma

Invasive Squamous Cell Carcinoma arising with an epidermal cyst

Pearls

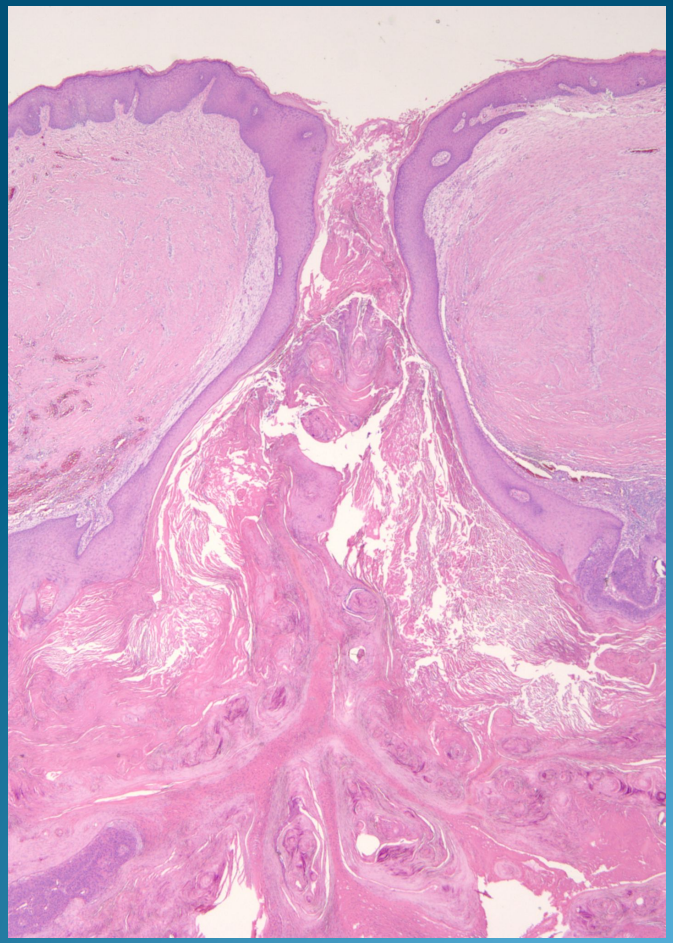

- Rare presentation of cutaneous squamous cell carcinoma
- Superficial shave biopsy may miss deeper carcinoma
- Conventional histopathology of SCCA

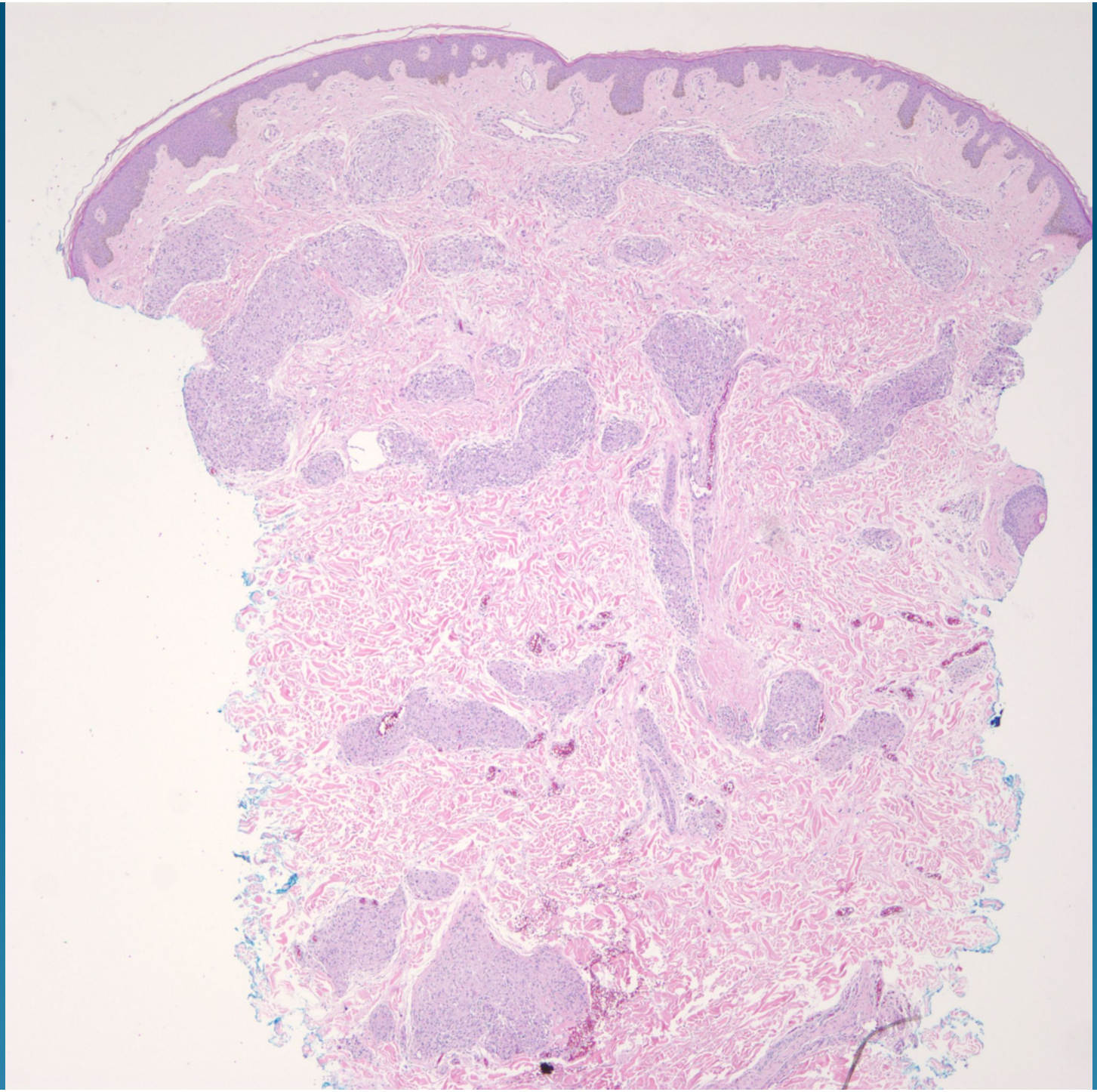

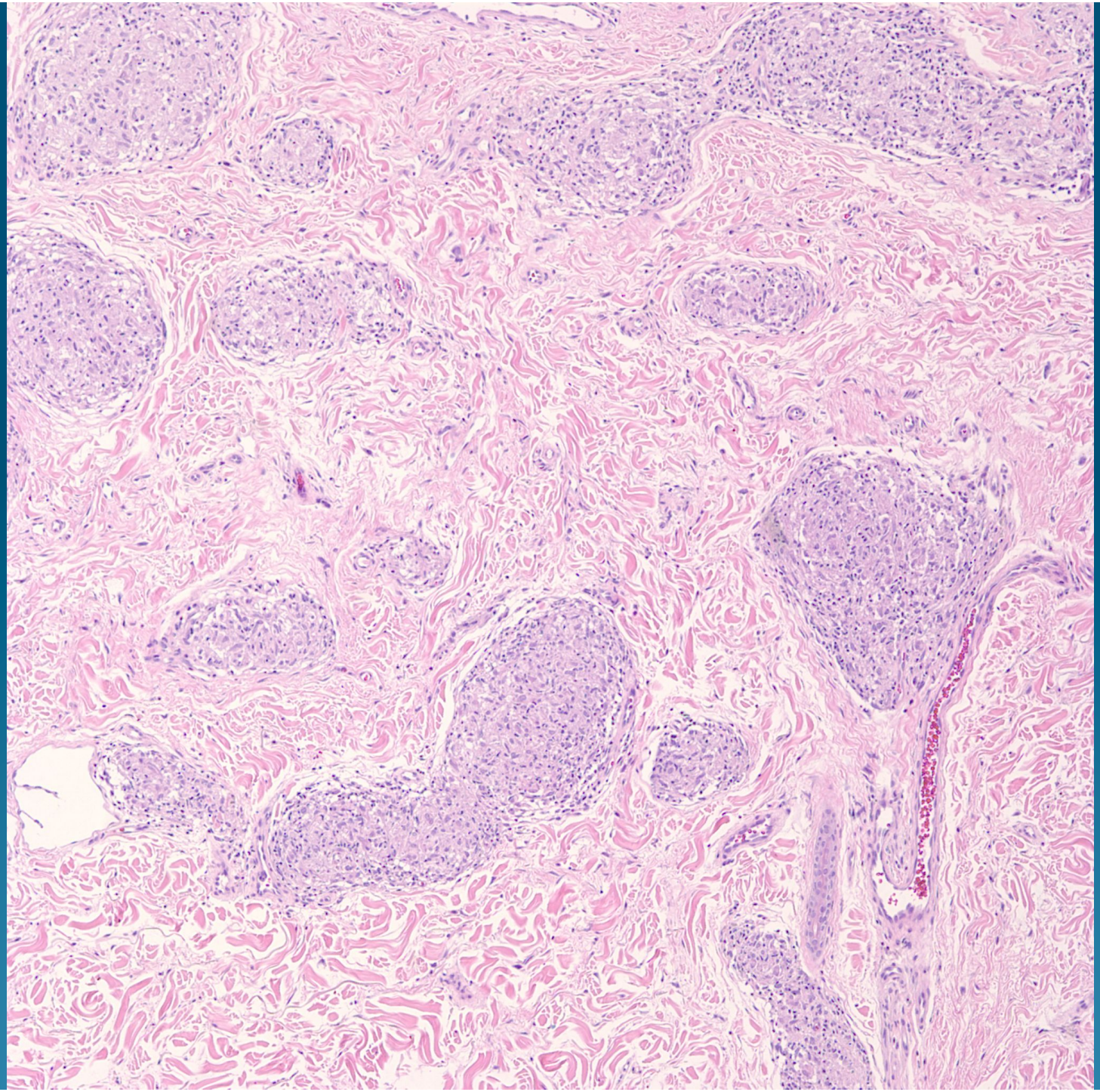

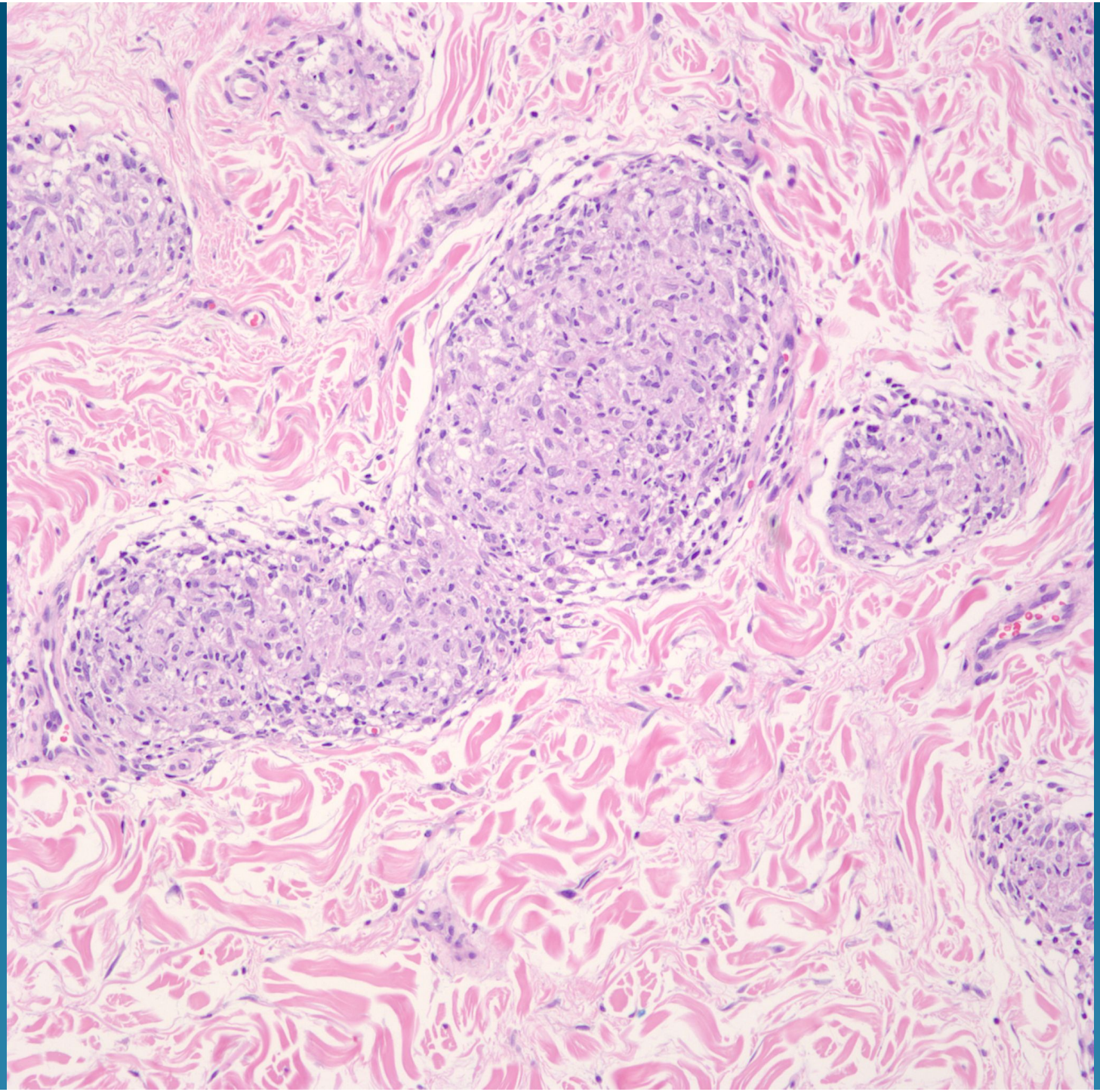

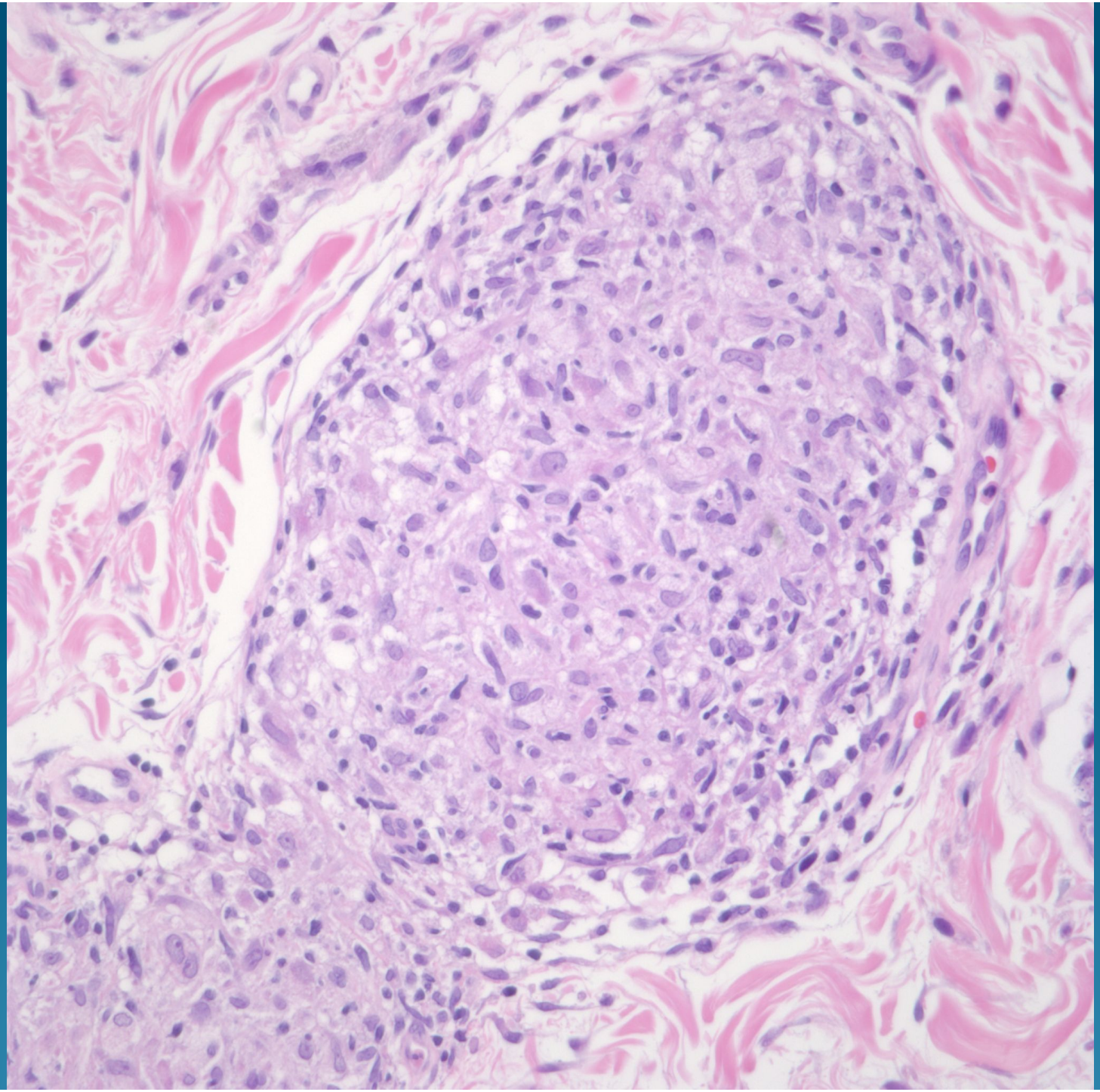

What is the best diagnosis?

A. Sarcoidosis
B. Langherans cell histiocytosis
C. Granulomatous slack skin disease
D. Granuloma annulare
E. Necrobiosis xanthogranuloma

Sarcoidosis

Pearls

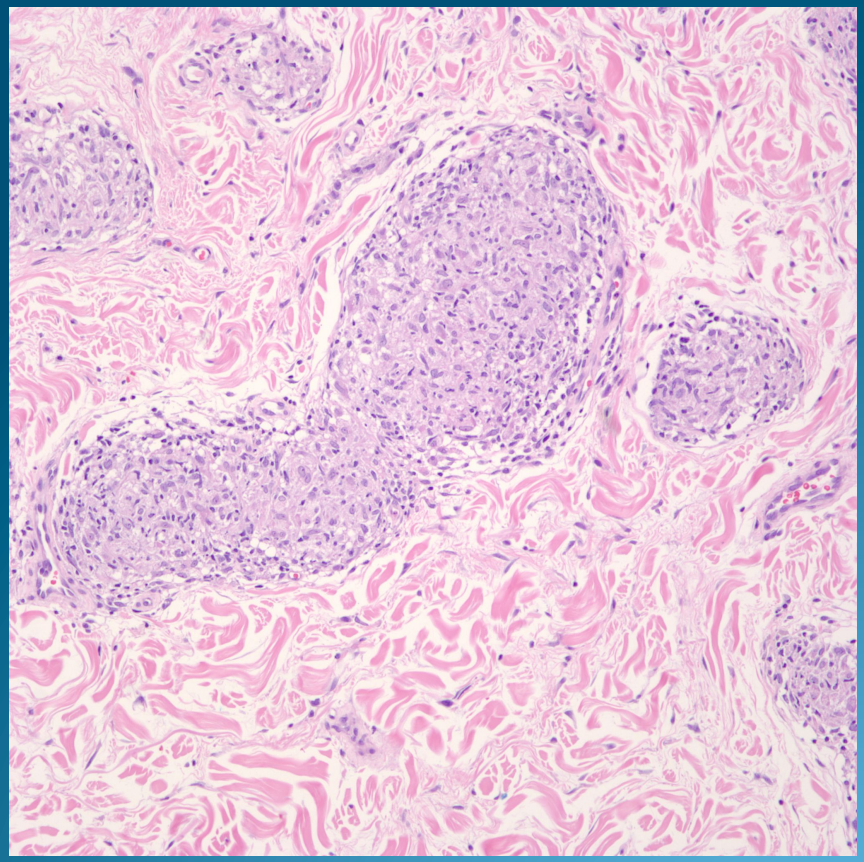

- Non caseating granulomas with minimal surrounding inflammatory cell infiltrate ("naked granulomas")
- Always polarize to rule out sarcoidal foreign body reaction-However, if found, it does not exclude an underlying systemic sarcoidosis
- Rule out infection, need Acid fast, FITE, PAS/GMS

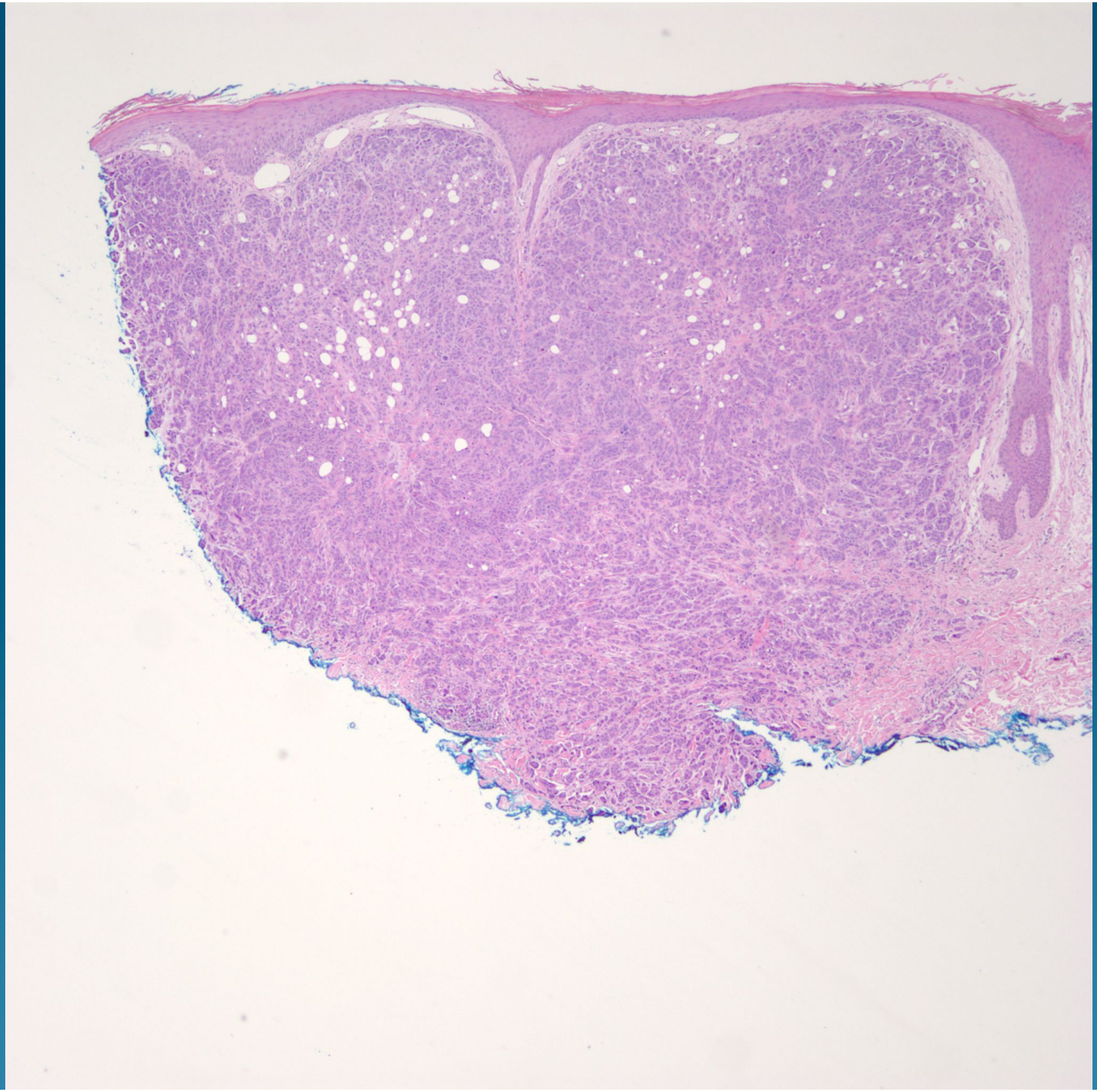

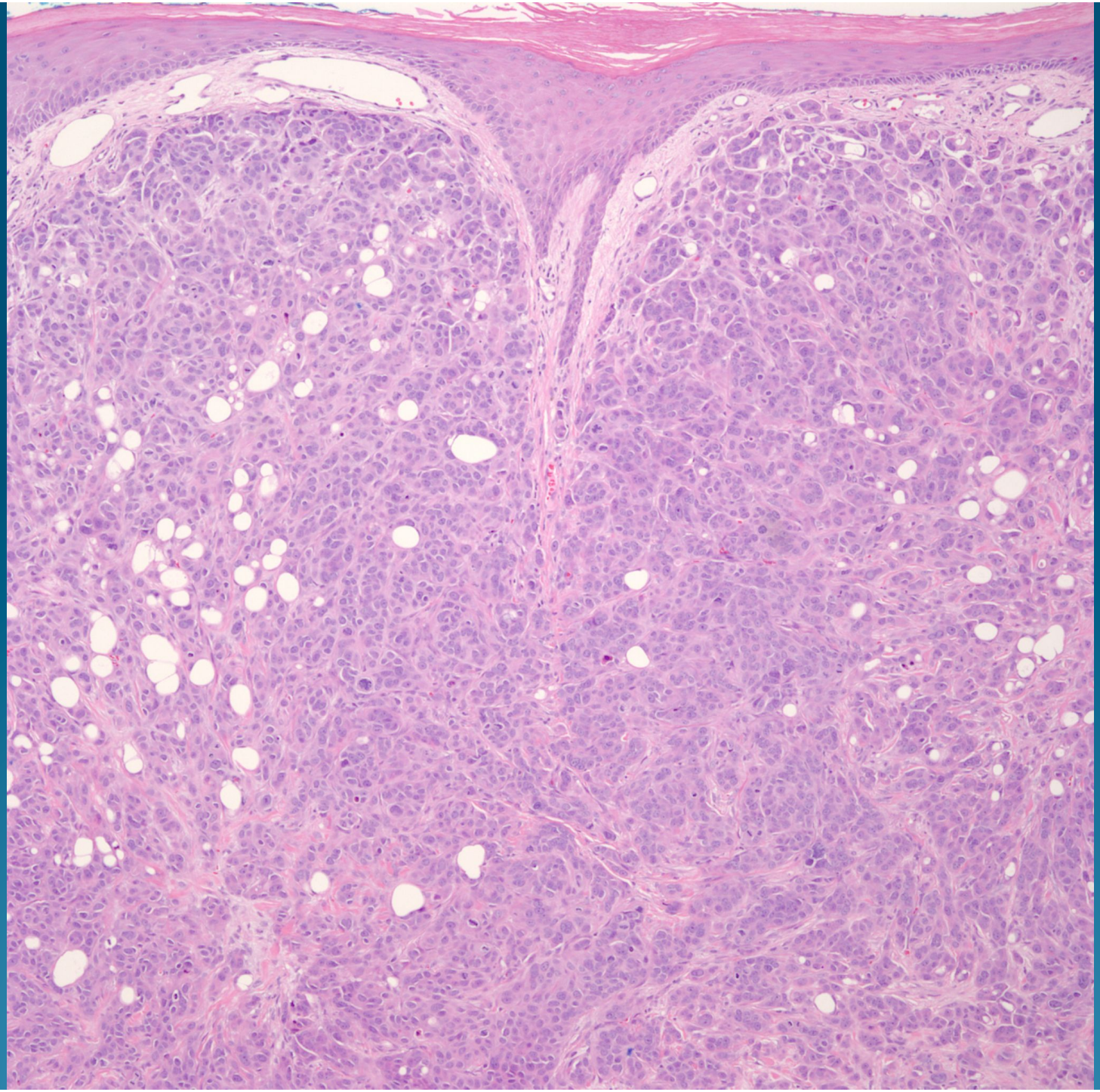

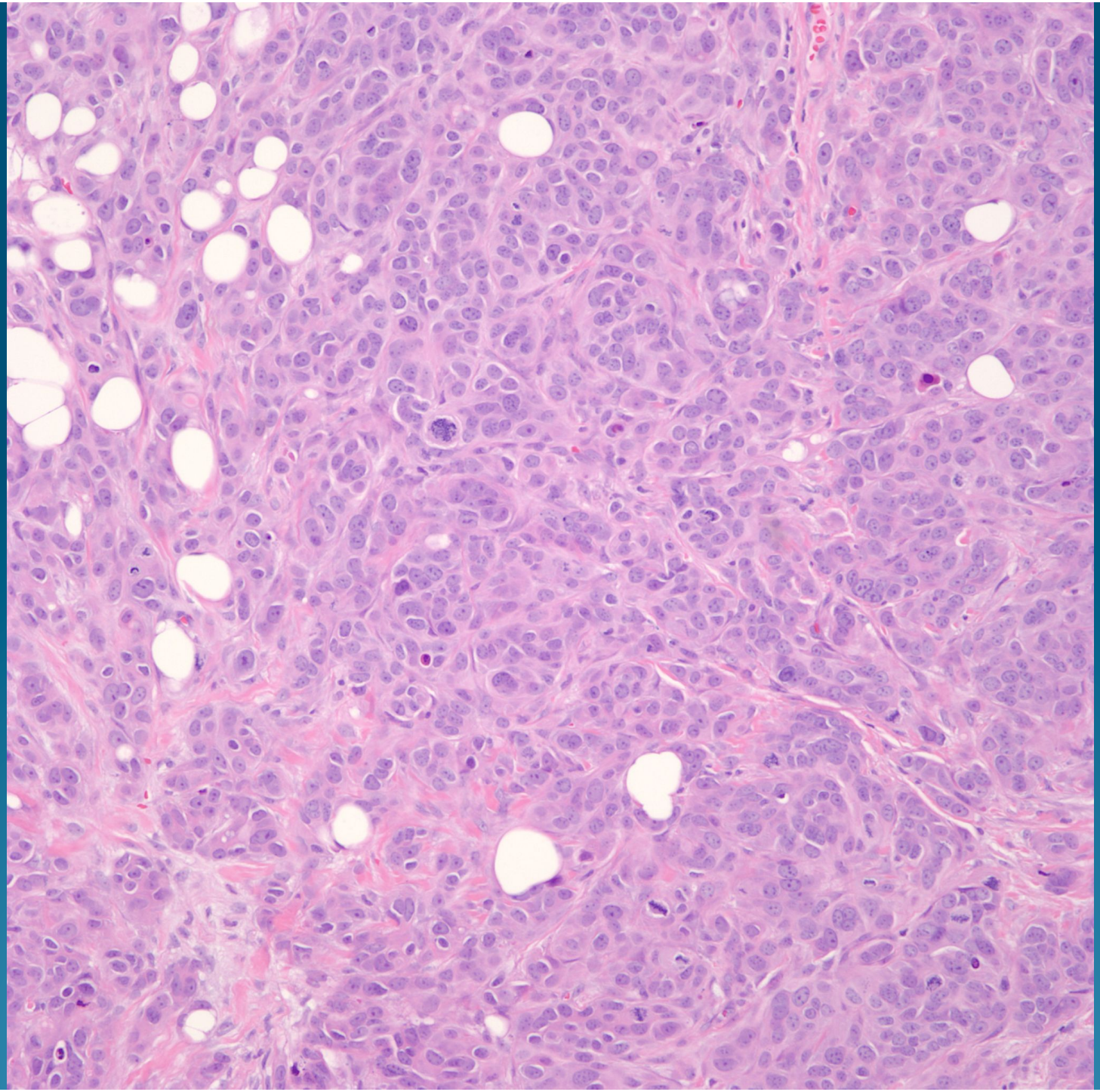

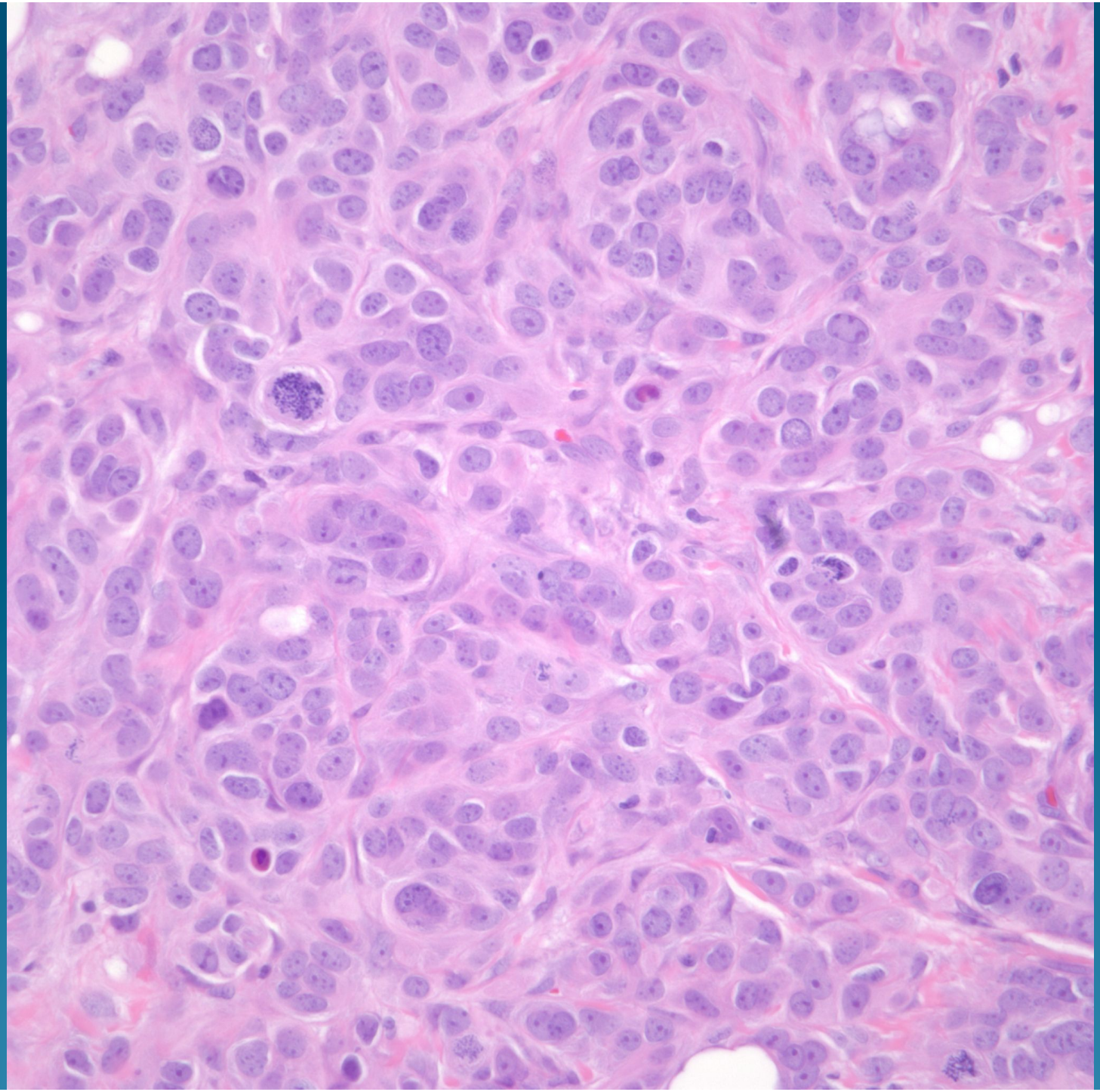

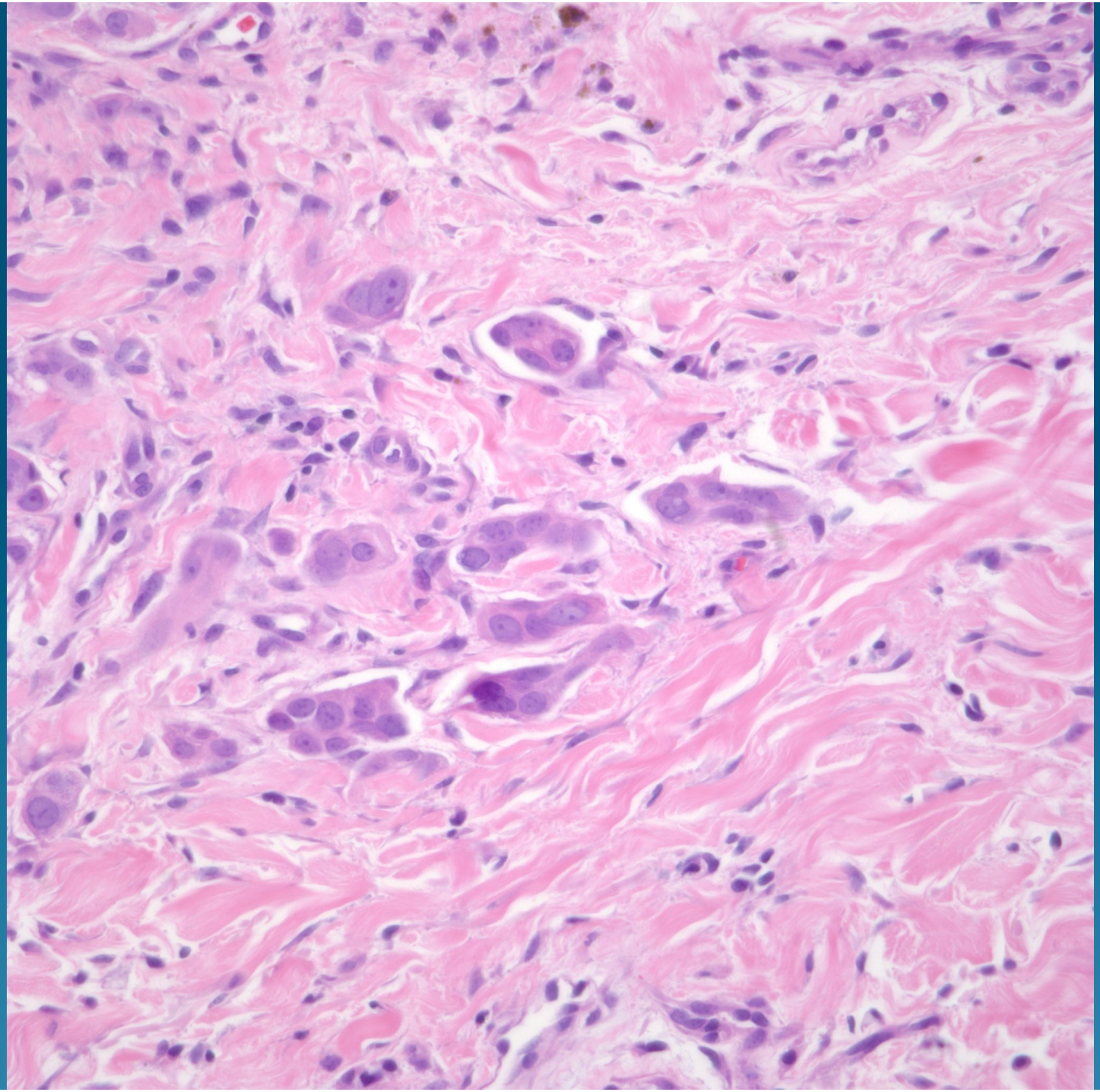

What is the best diagnosis?

A. Malignant melanoma
B. Microcystic adnexal carcinoma
C. Metastatic adenocarcinoma
D. Sebaceous carcinoma
E. Morpheaform basal cell carcinoma

Metastatic adenocarcinoma, consistent with breast primary

Pearls

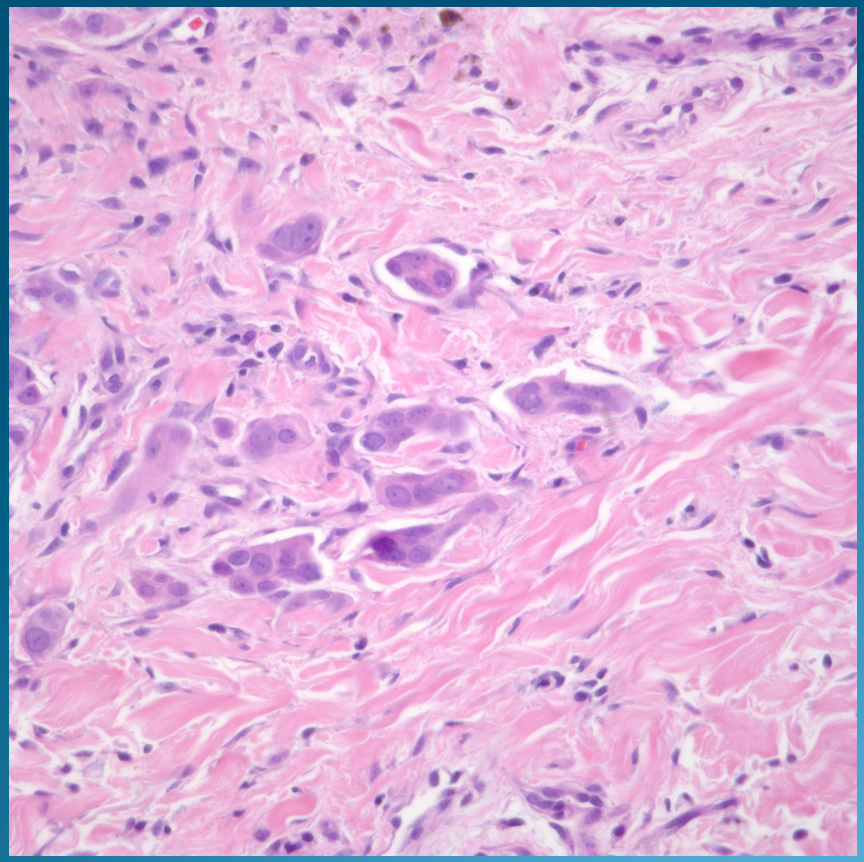

- Diffuse replacement of dermis by pleomorphic epithelial cells with focal glandular differentiation
- Usually entirely dermal based but may rarely have epidermal involvement
- Look for lymphovascular invasion
- Need clinical history and additional immunohistochemical markers for confirmation

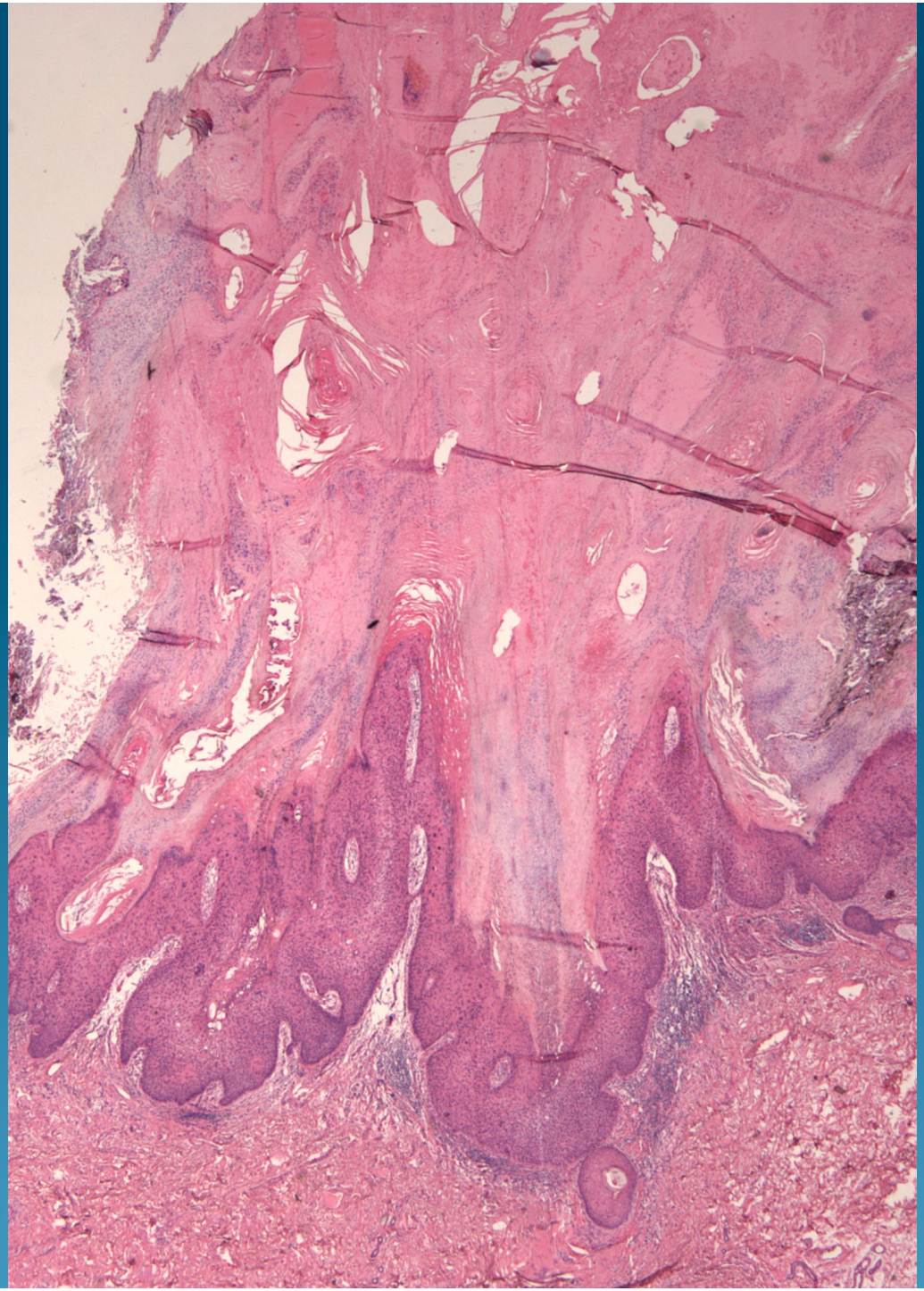

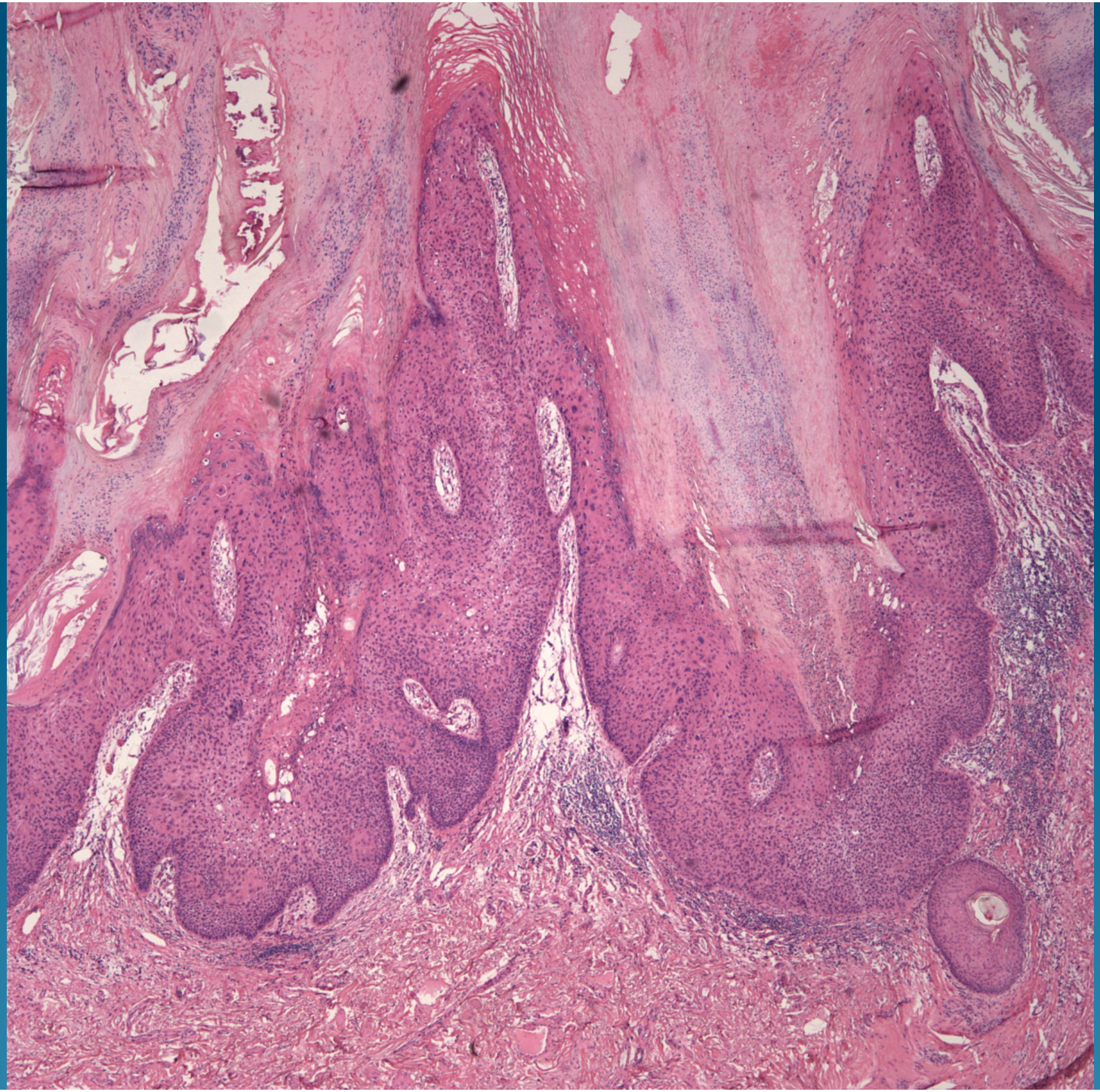

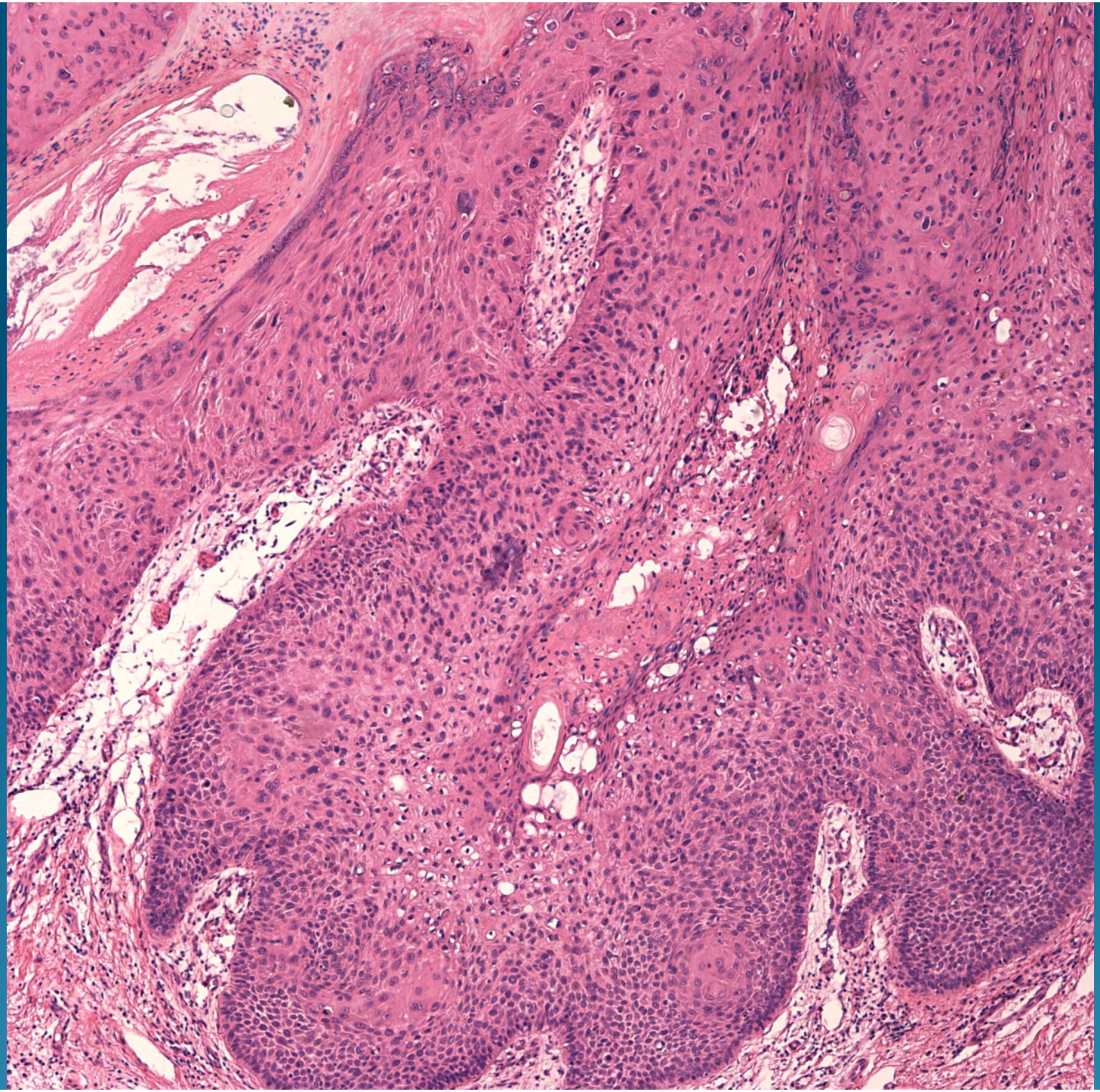

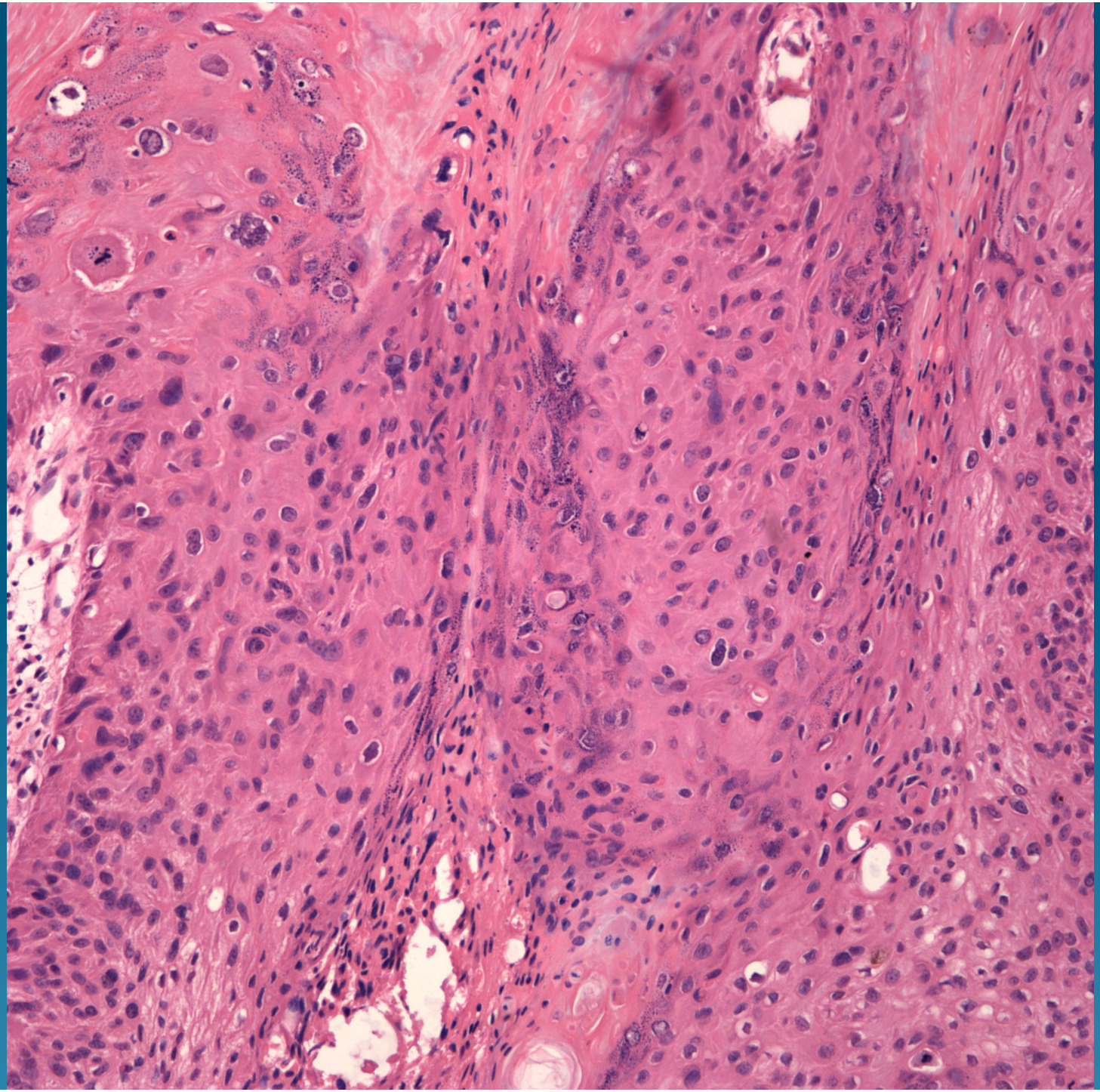

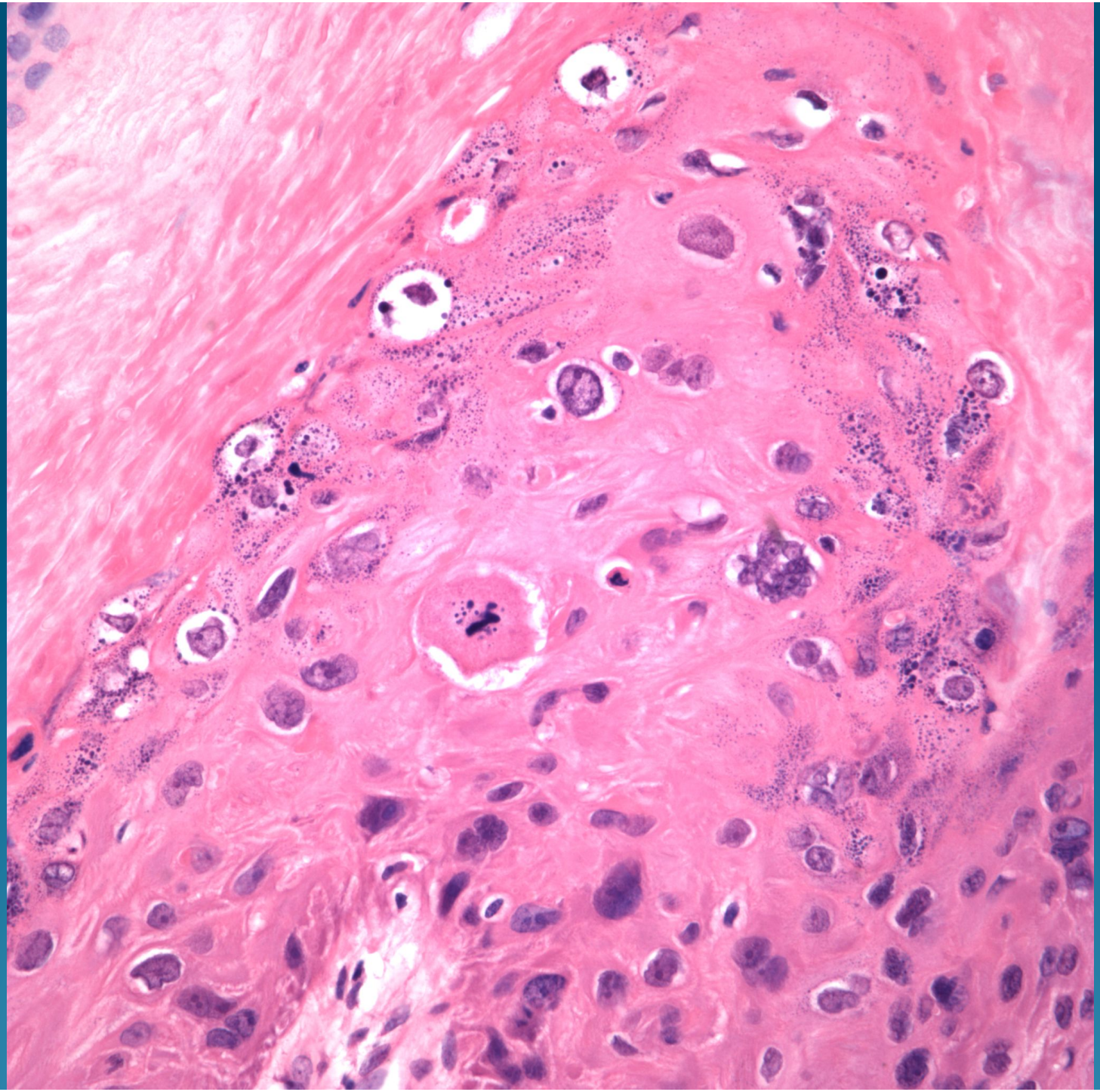

What is the best diagnosis?

A. Verruca vulgaris
B. Squamous cell carcinoma
C. Basaloid squamous cell carcinoma
D. Darier's disease
E. Hypertrophic discoid lupus erythematosus

Penile Intraepithelial Neoplasia (PeIN) , Differentiated Type (Squamous Cell Carcinoma of Penis)

Pearls

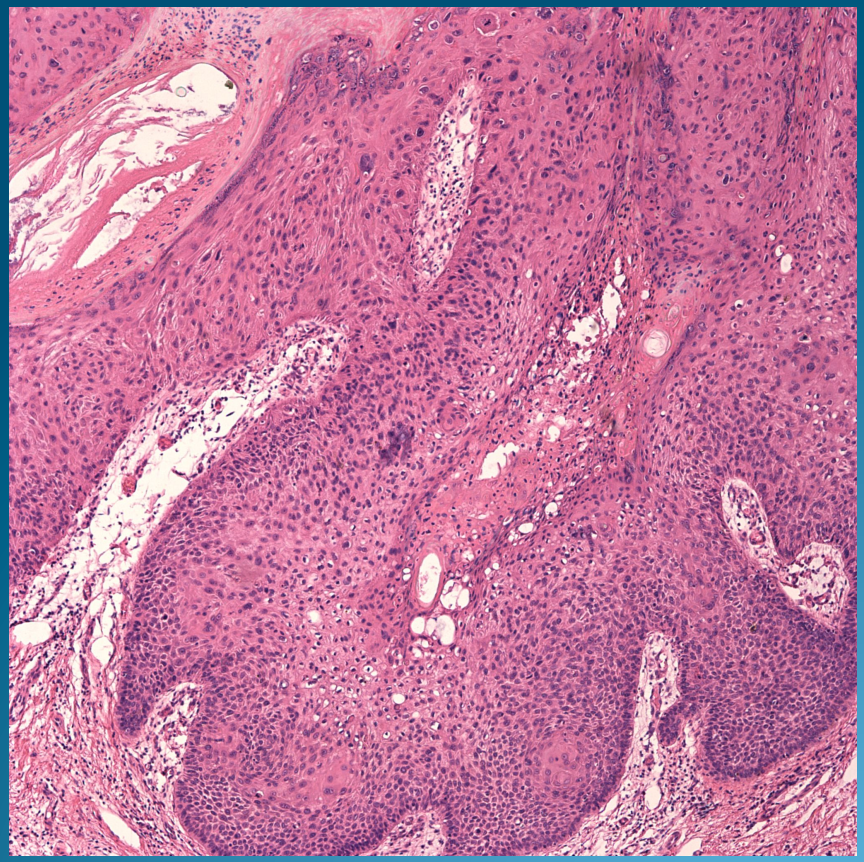

- New diagnostic classification for squamous epithelial tumors (previously included erythroplasia of Queyrat)
- Full thickness replacement of squamous mucosa, akin to Bowen's disease
- If well differentiated keratinocytes, designate differentiated type. Basaloid or crowded cells have designated undifferentiated type

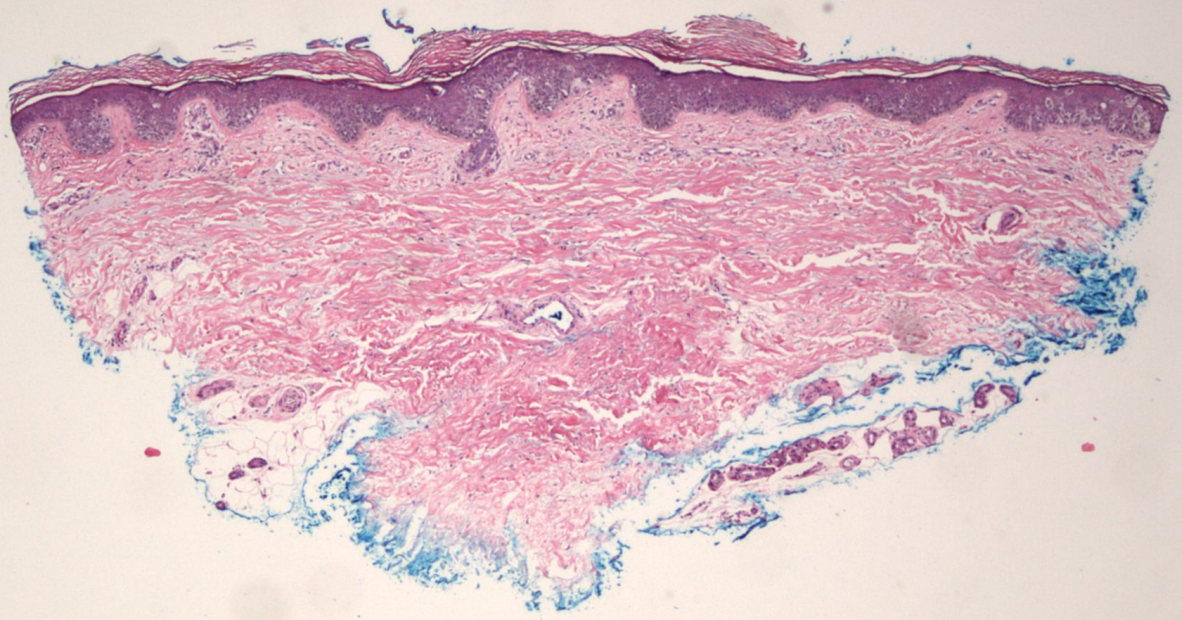

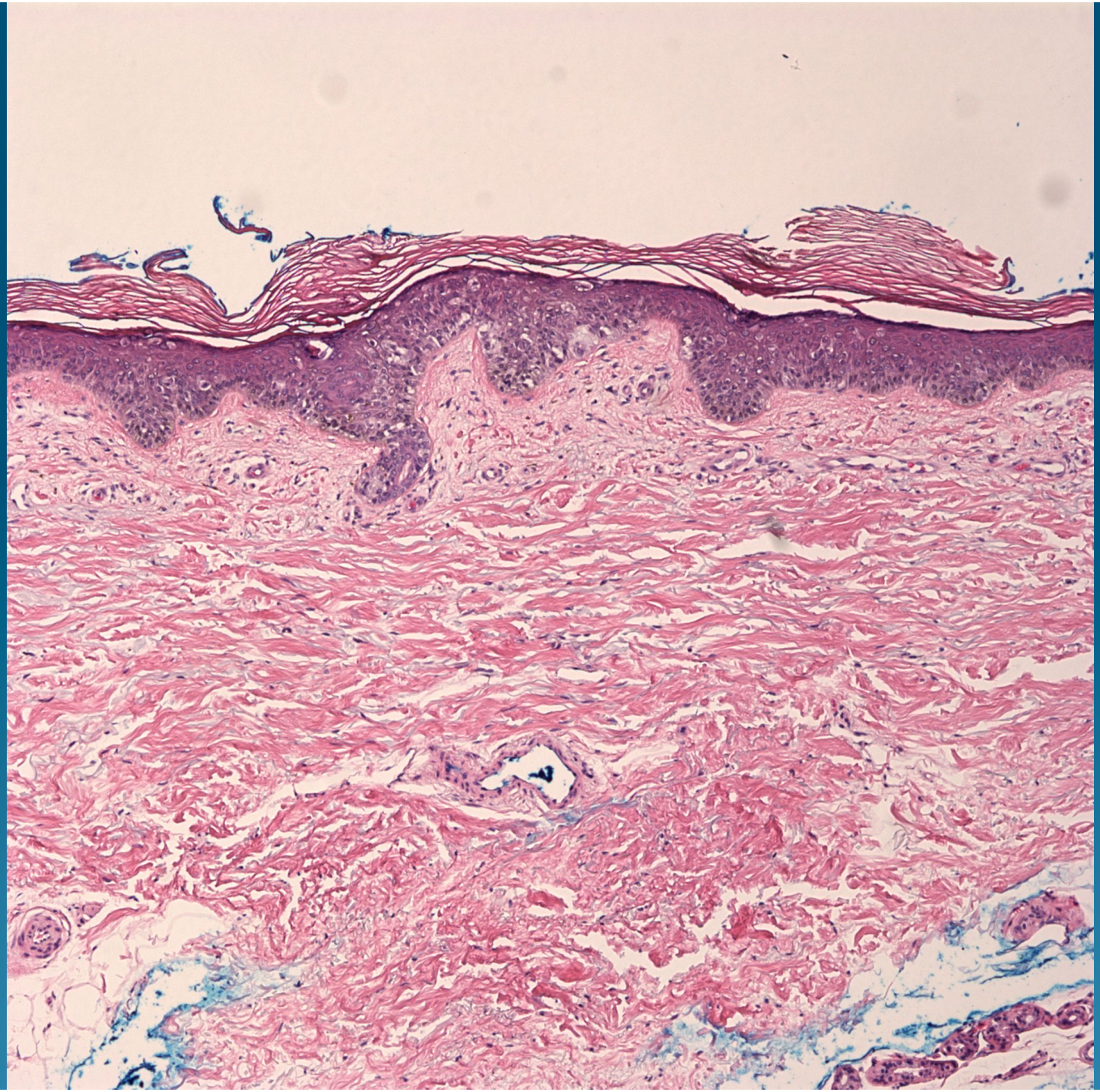

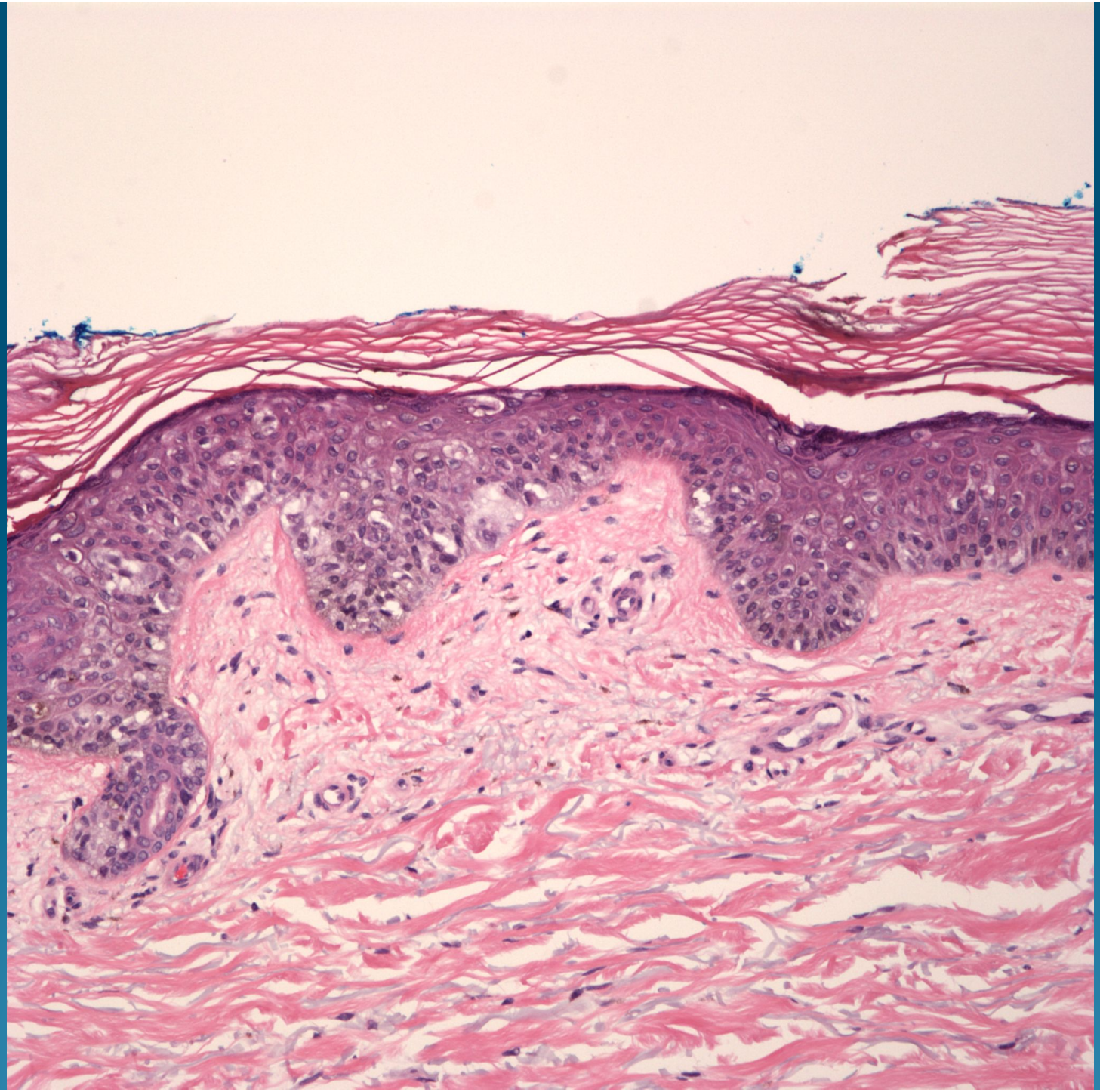

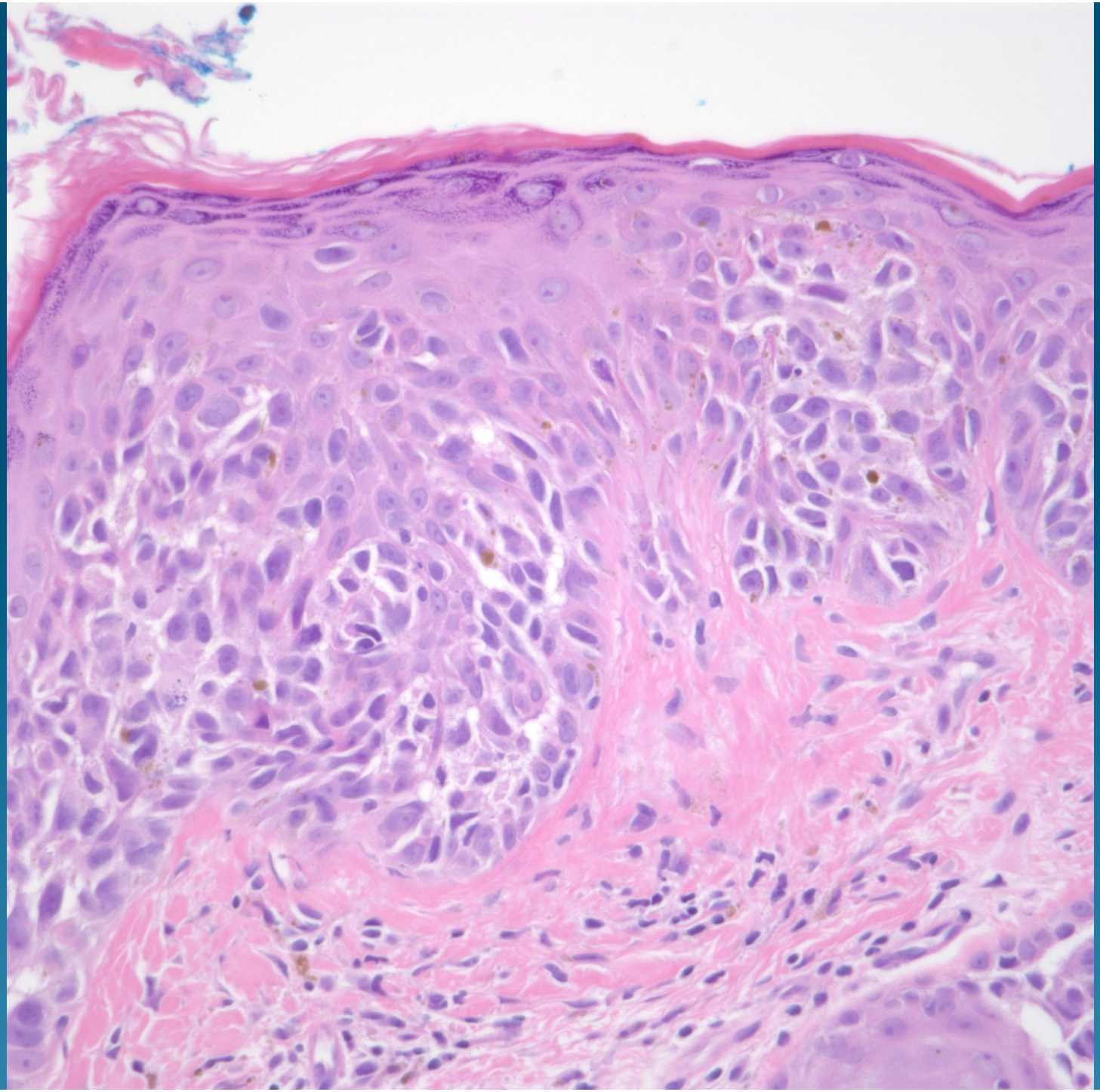

What is the best diagnosis?

A. Hidroacanthoma simplex
B. Superficial basal cell carcinoma
C. Actinic keratosis
D. Mycosis fungoides
E. Malignant melanoma in situ

Malignant Melanoma in Situ, Superficial Spreading Type

Pearls

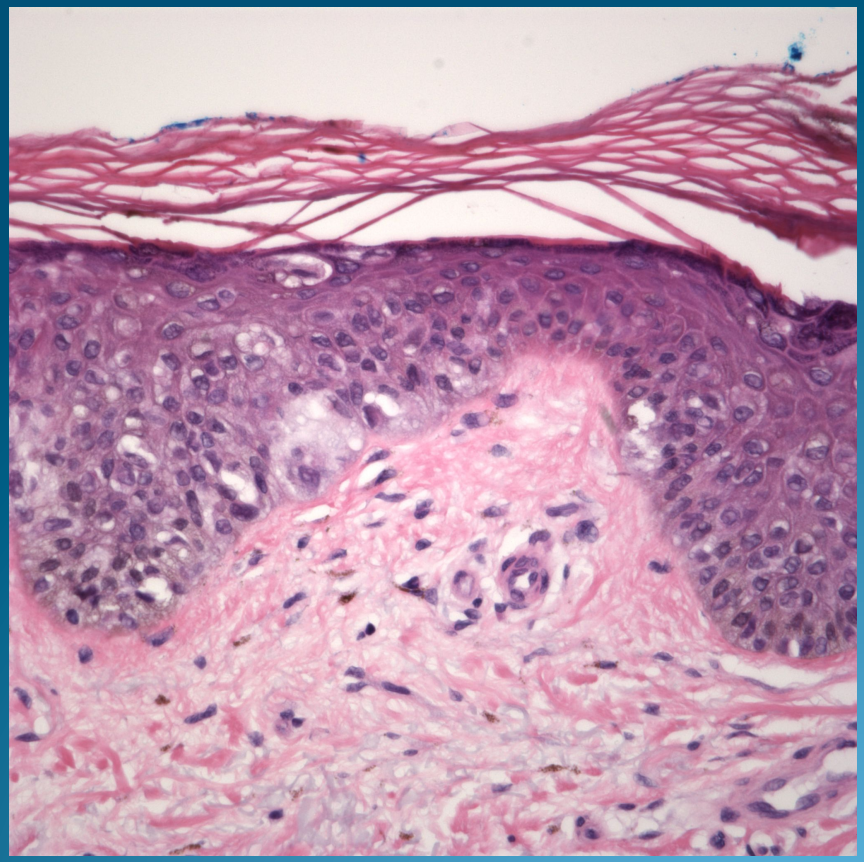

- Haphazard proliferation of atypical melanocytes (Pagetoid spread)
- Variable melanin pigmentation
- Usually solar elastosis
- May need to confirm with IHC to differentiate from SCCIS and Paget's.