Dermatopathology Slide Review Part 127

Paul K. Shitabata, M.D.
Dermatopathology Institute
Torrance, CA

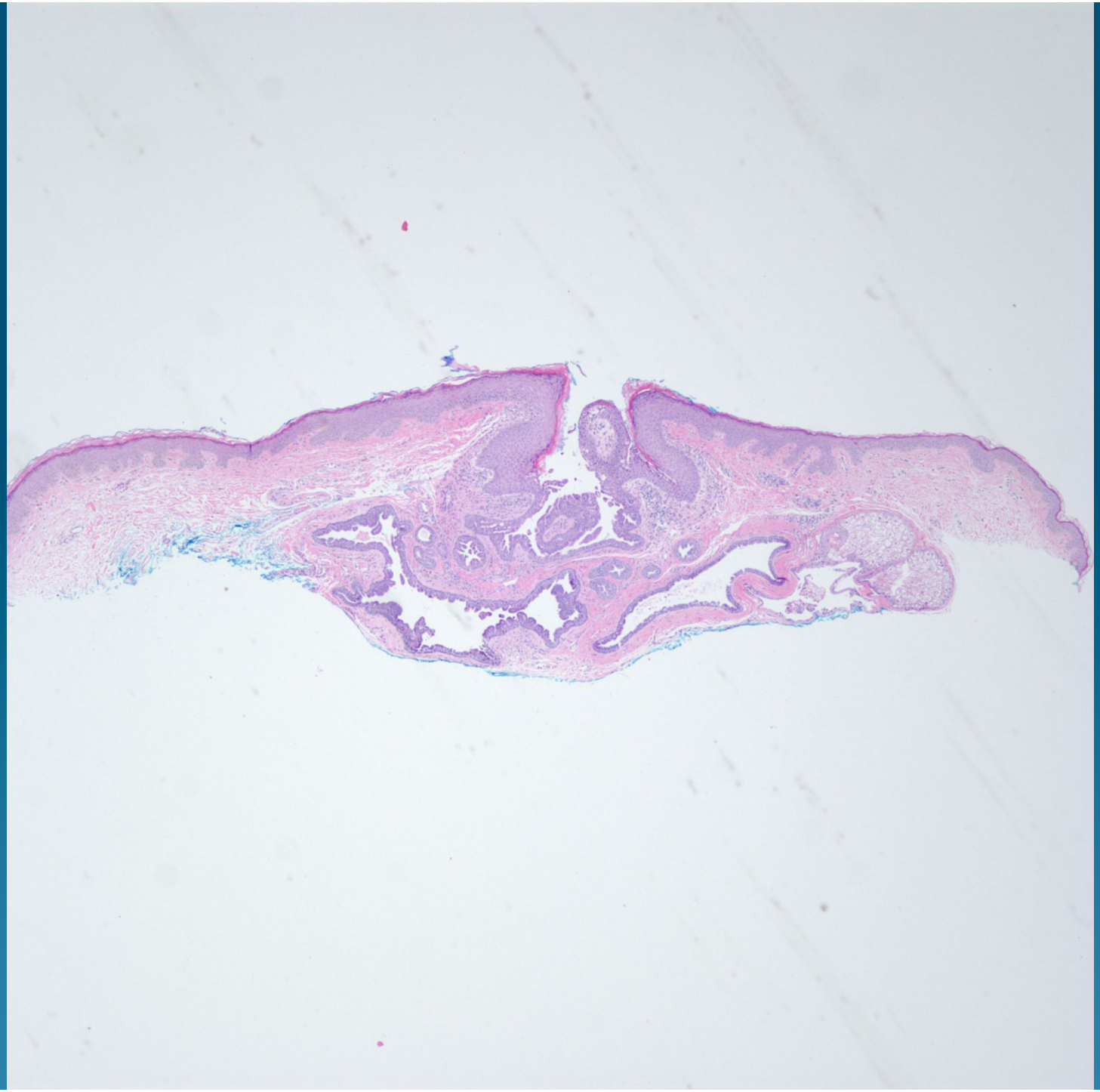

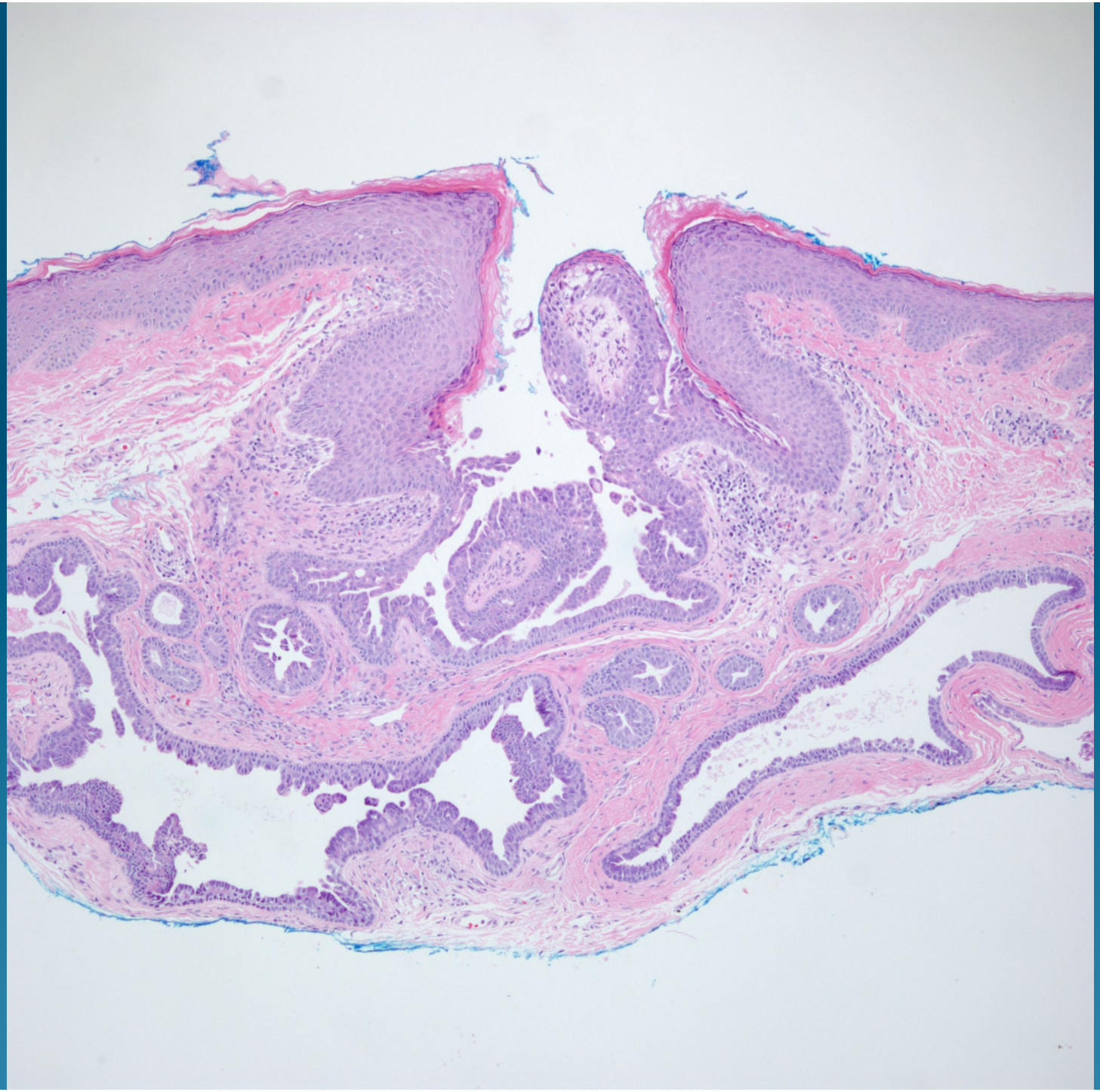

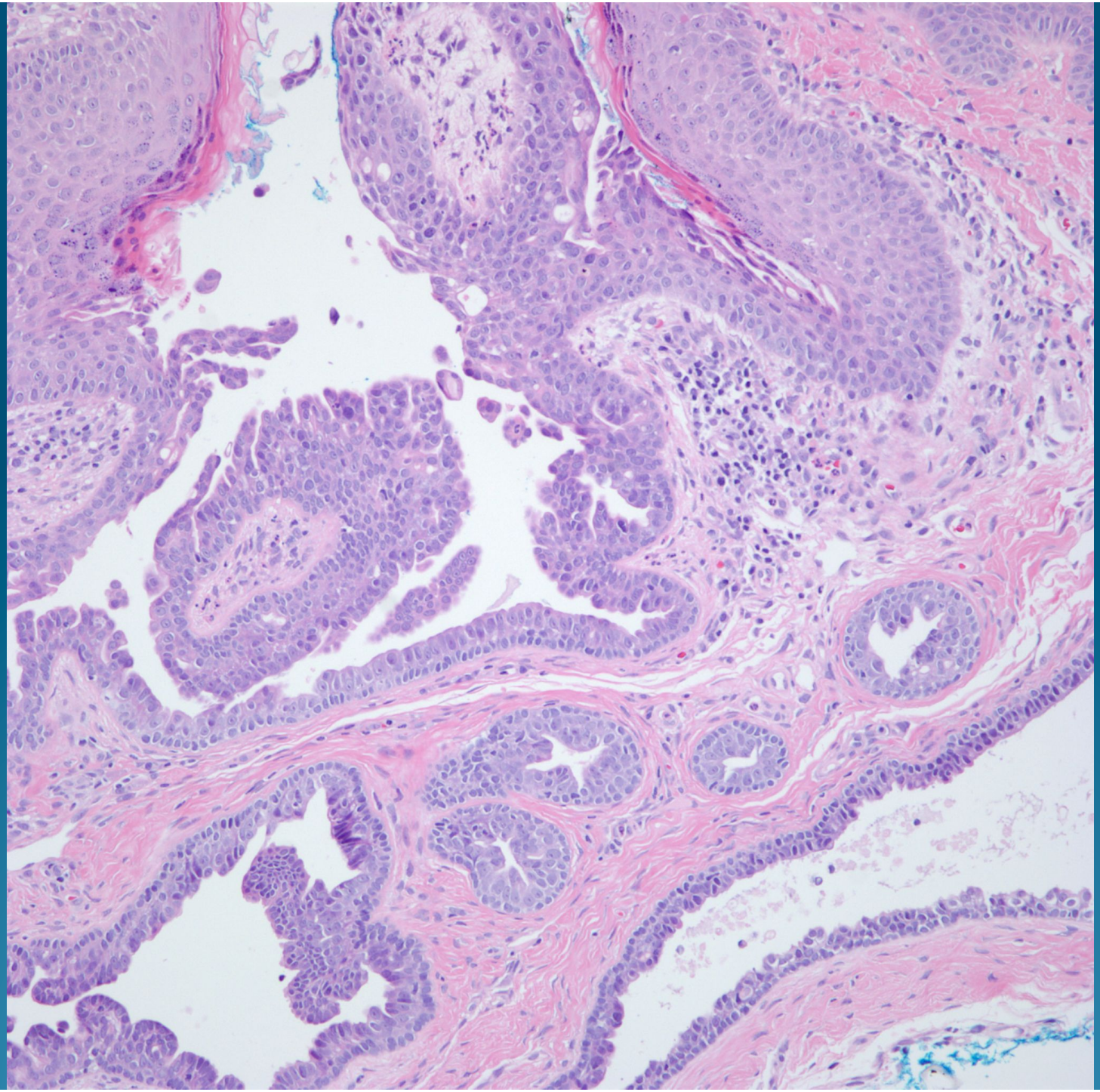

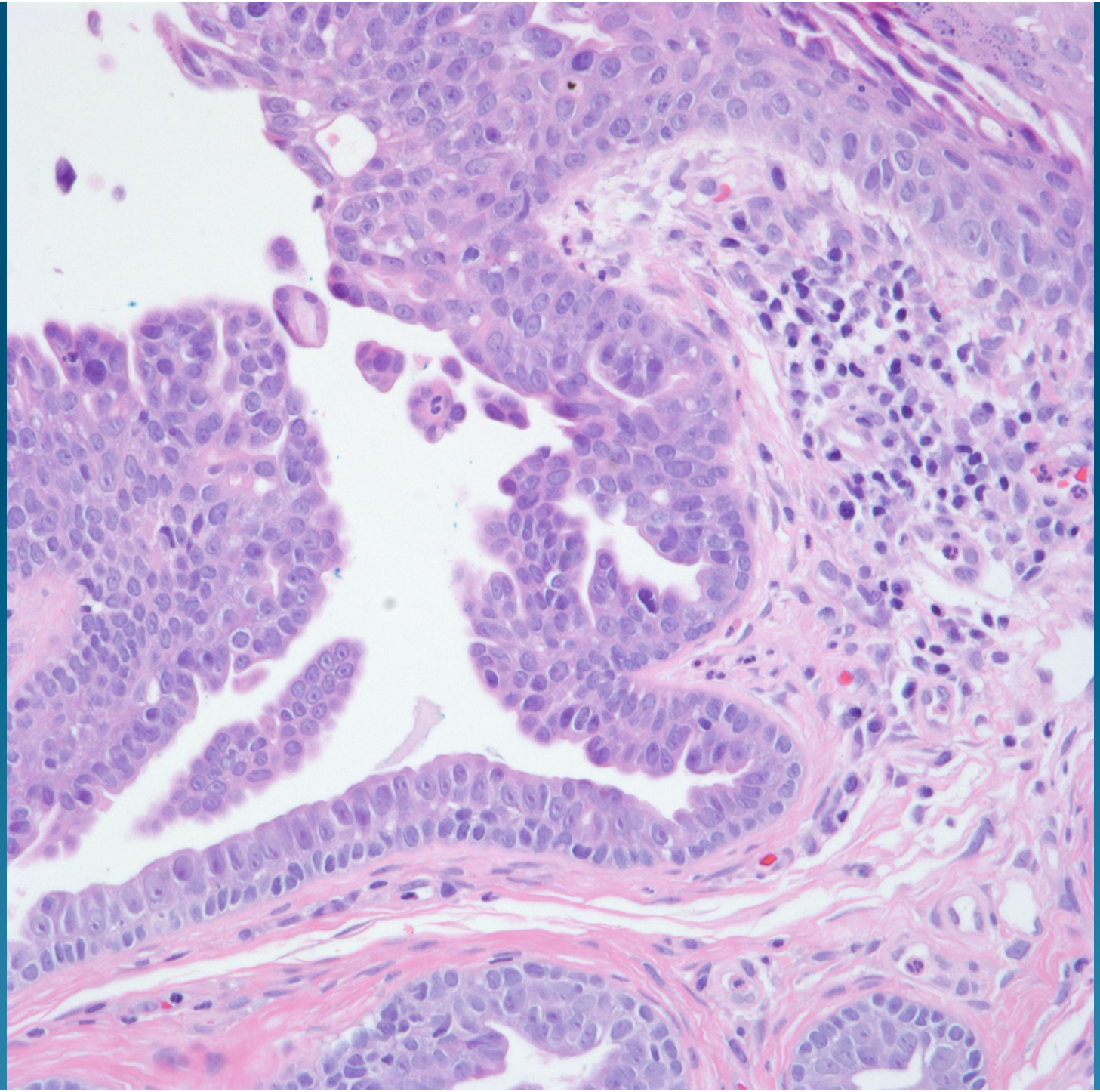

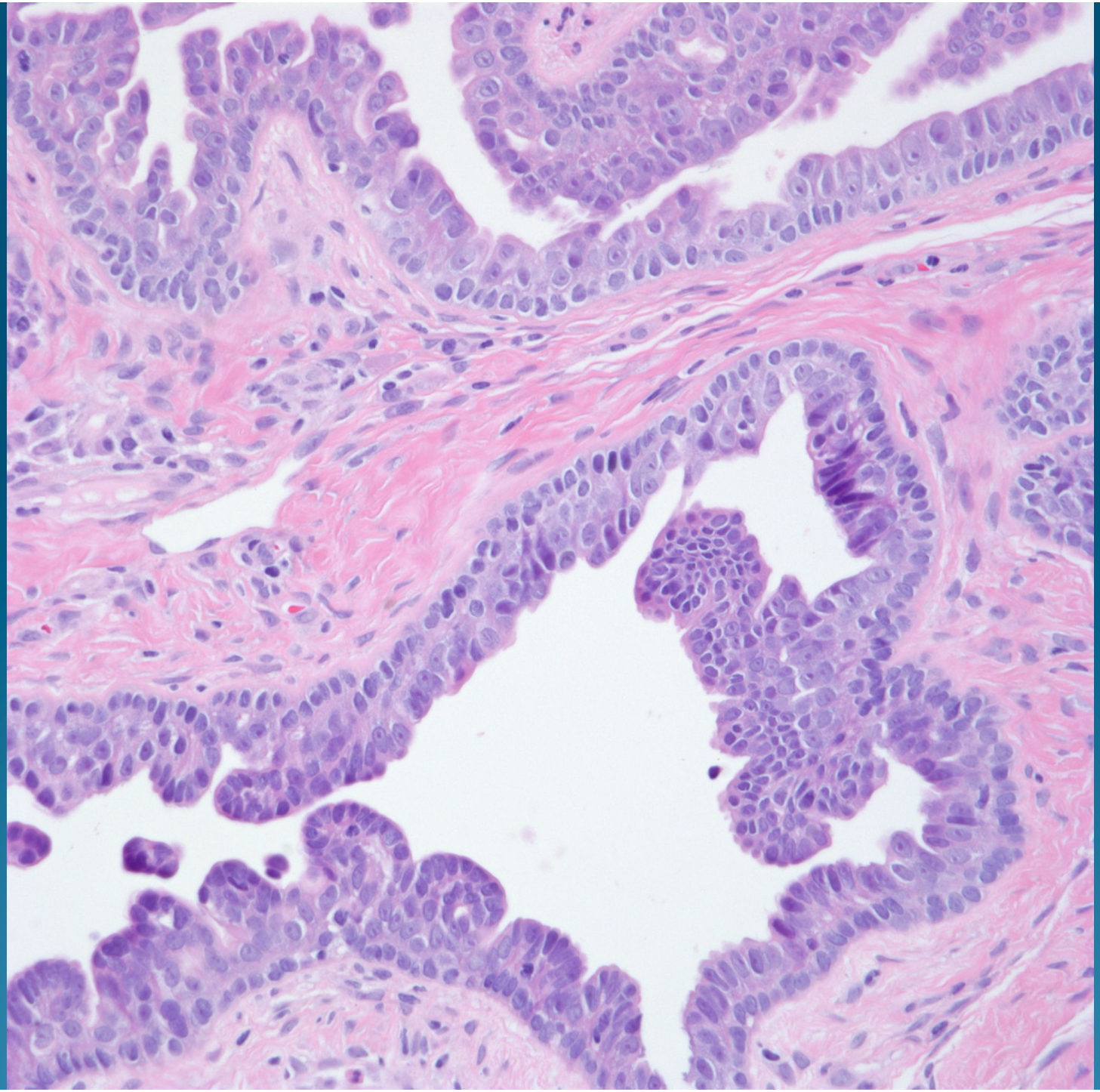

What is the best diagnosis?

A. Tubular adenoma
B. Metastatic adenocarcinoma
C. Hidradenoma papilliferum
D. Adenoid basal cell carcinoma
E. Syringocystadenoma papilliferum

Syringocystadenoma papilliferum

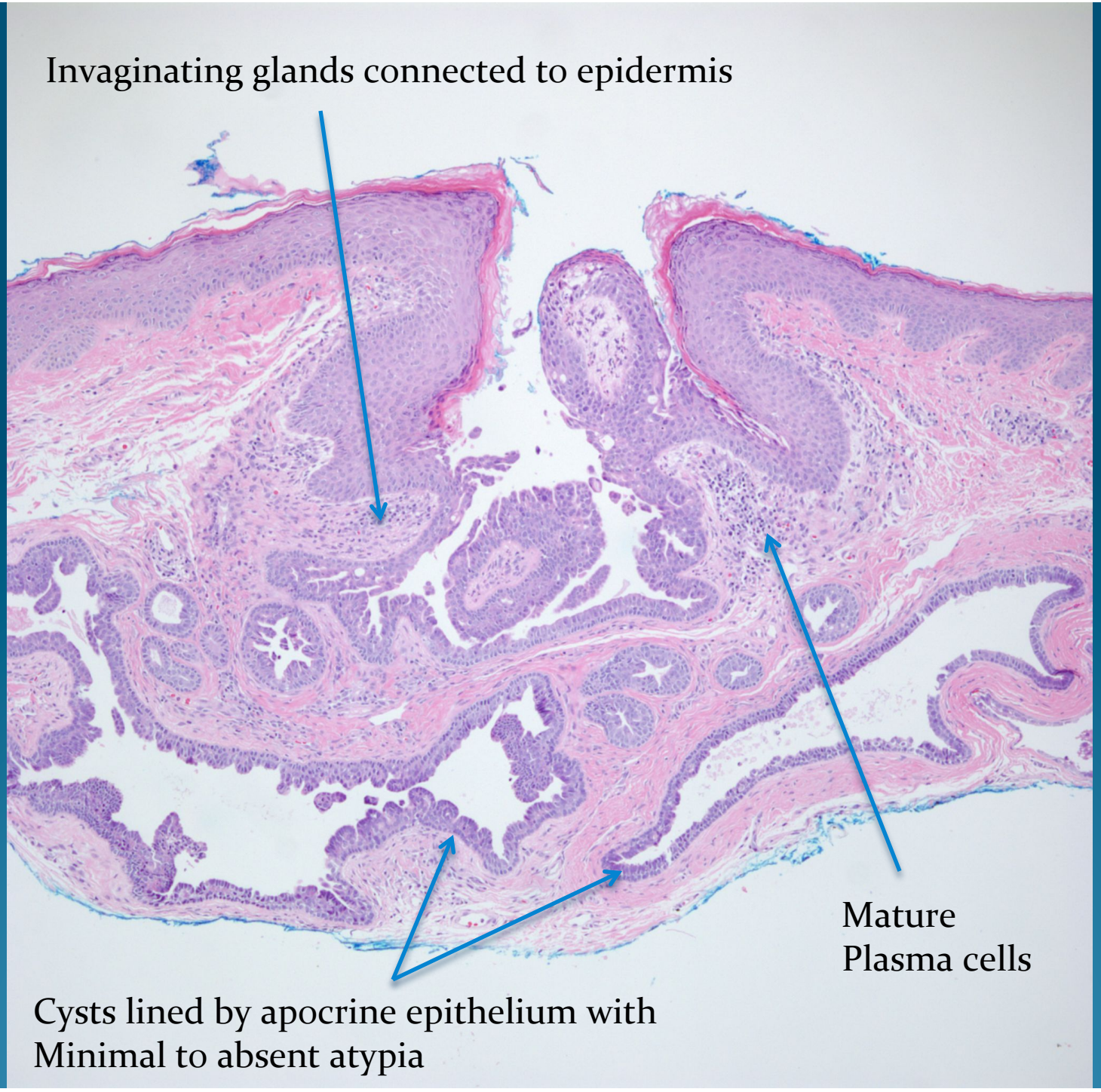
Invaginating glands connected to epidermis
Mature
Plasma cells
Cysts lined by apocrine epithelium with
Minimal to absent atypia

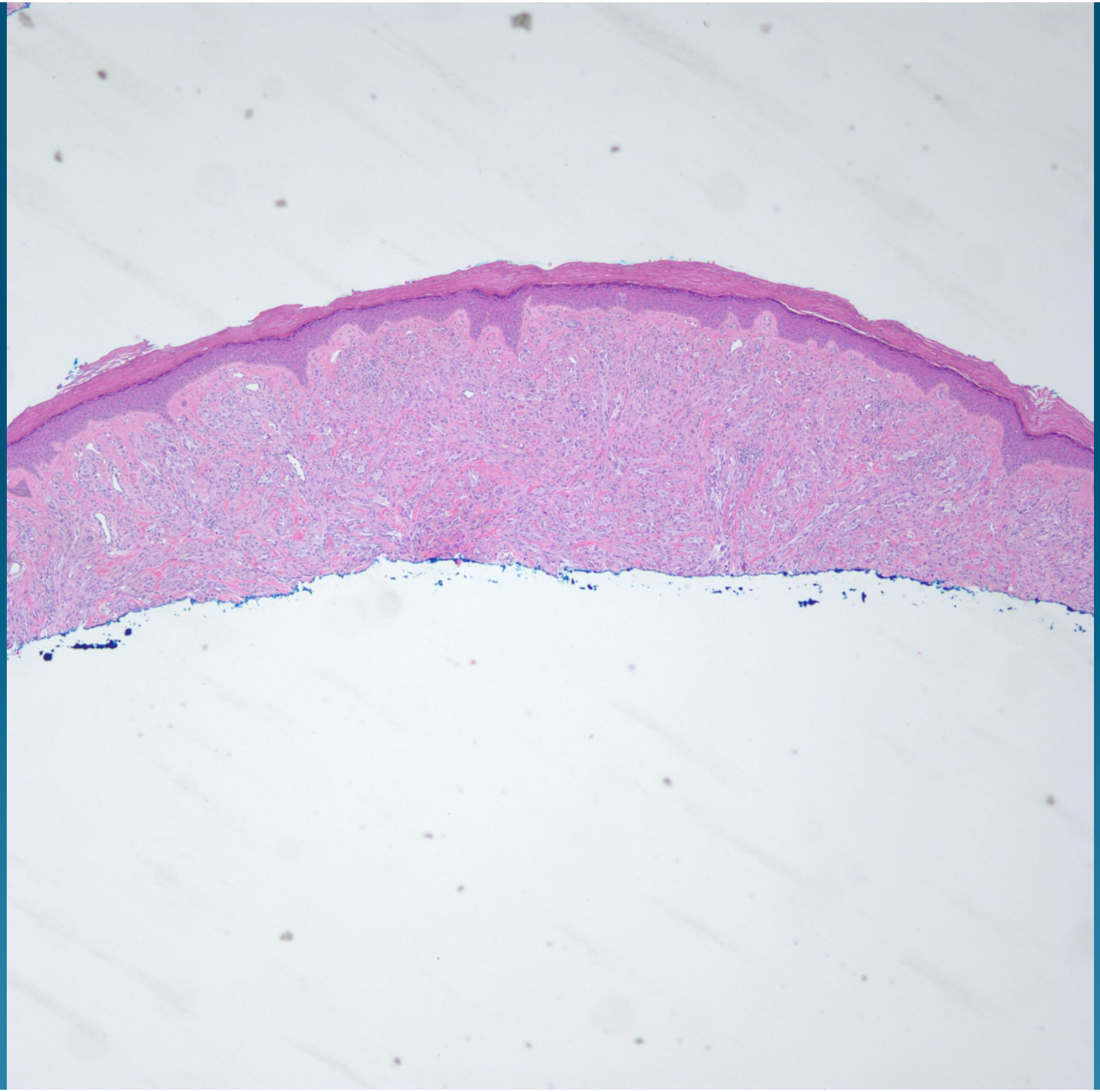

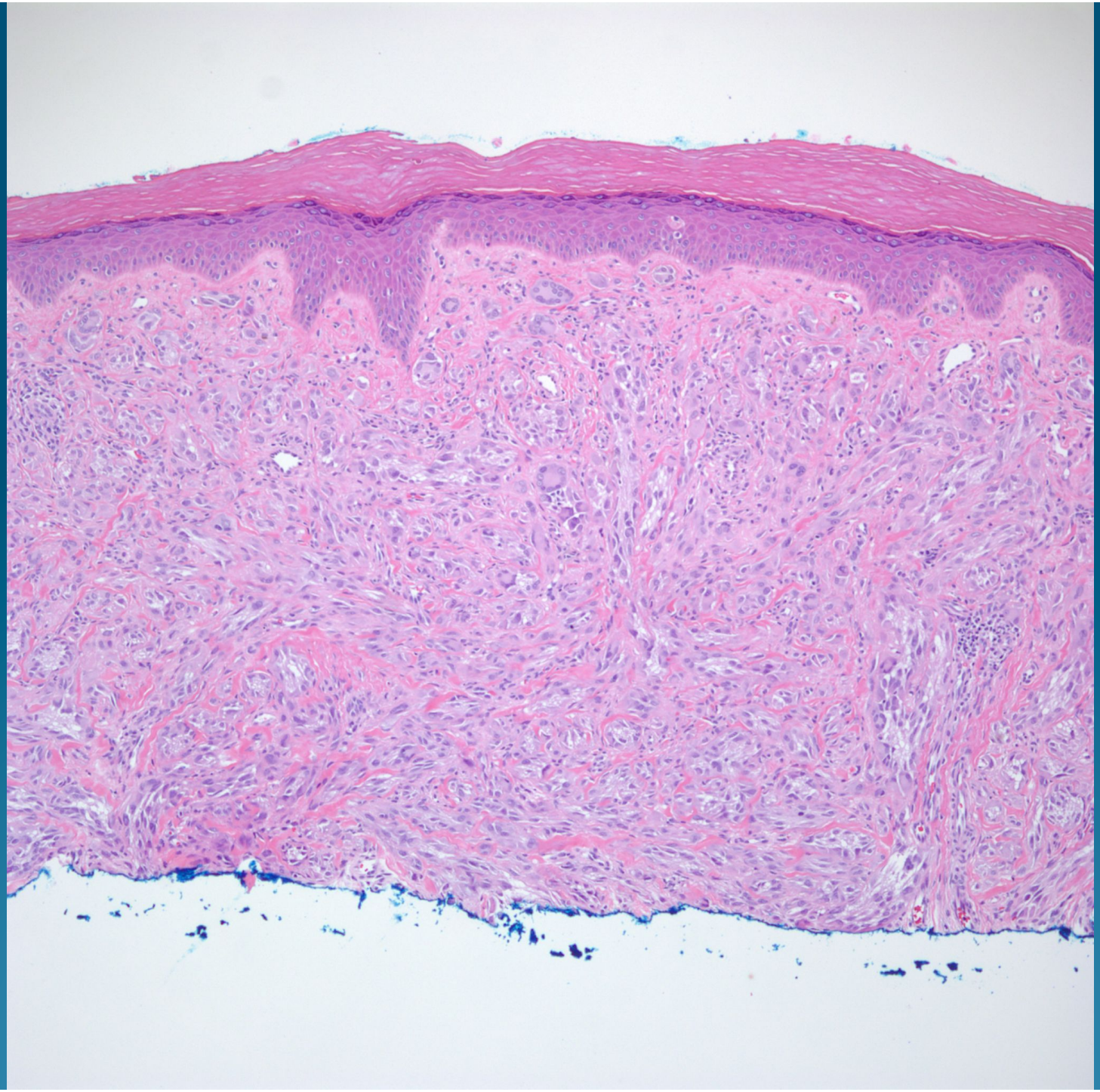

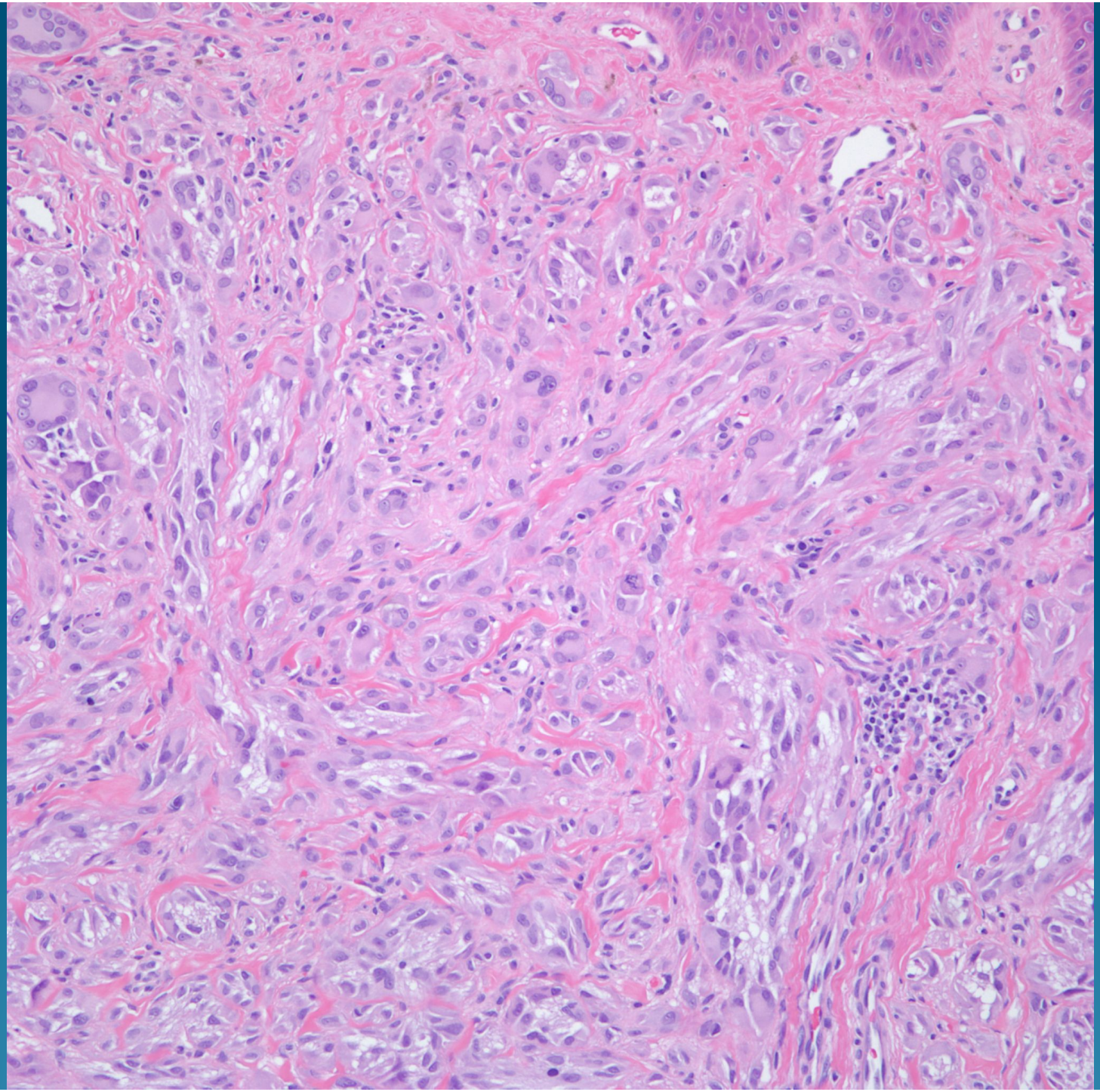

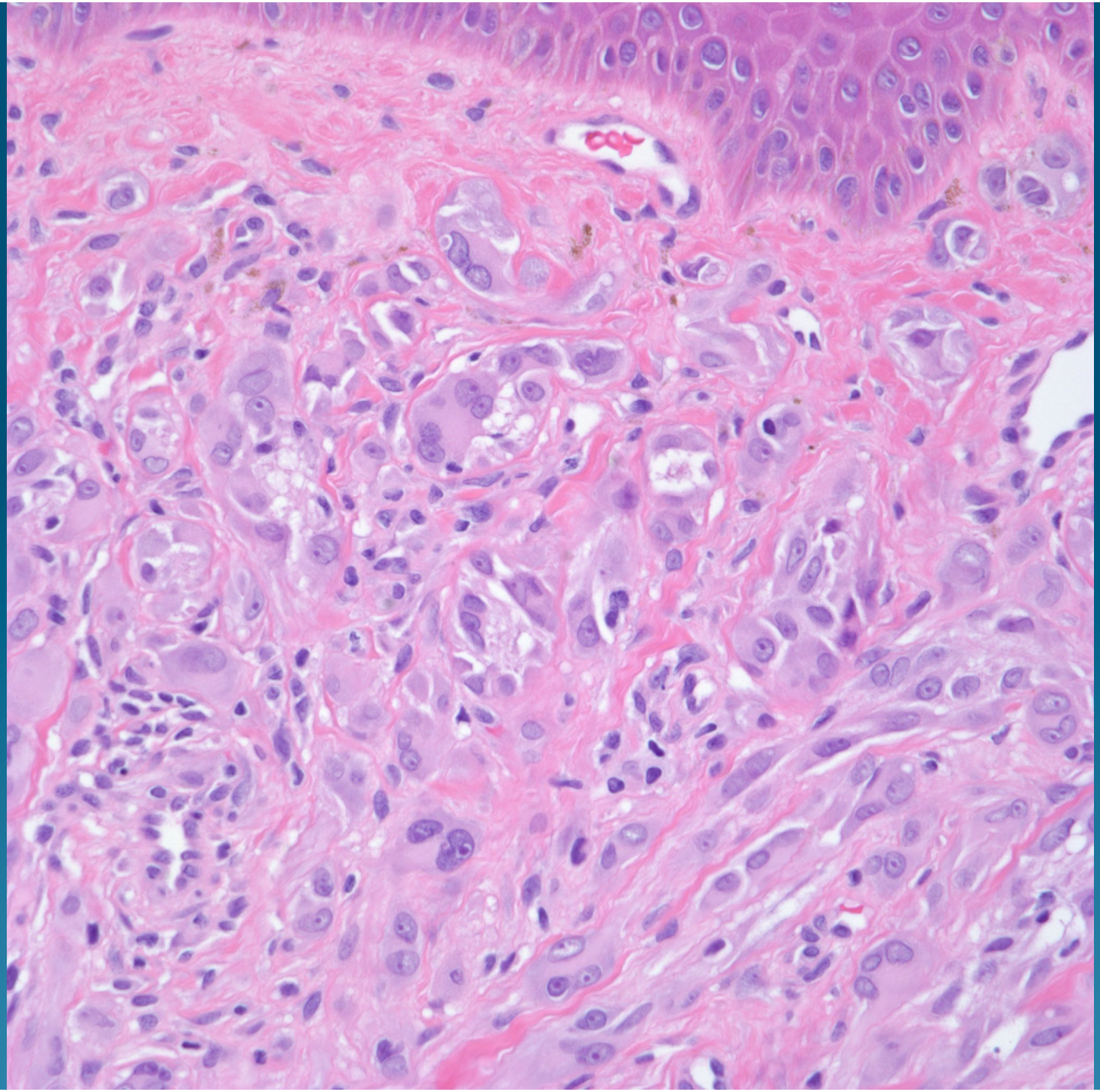

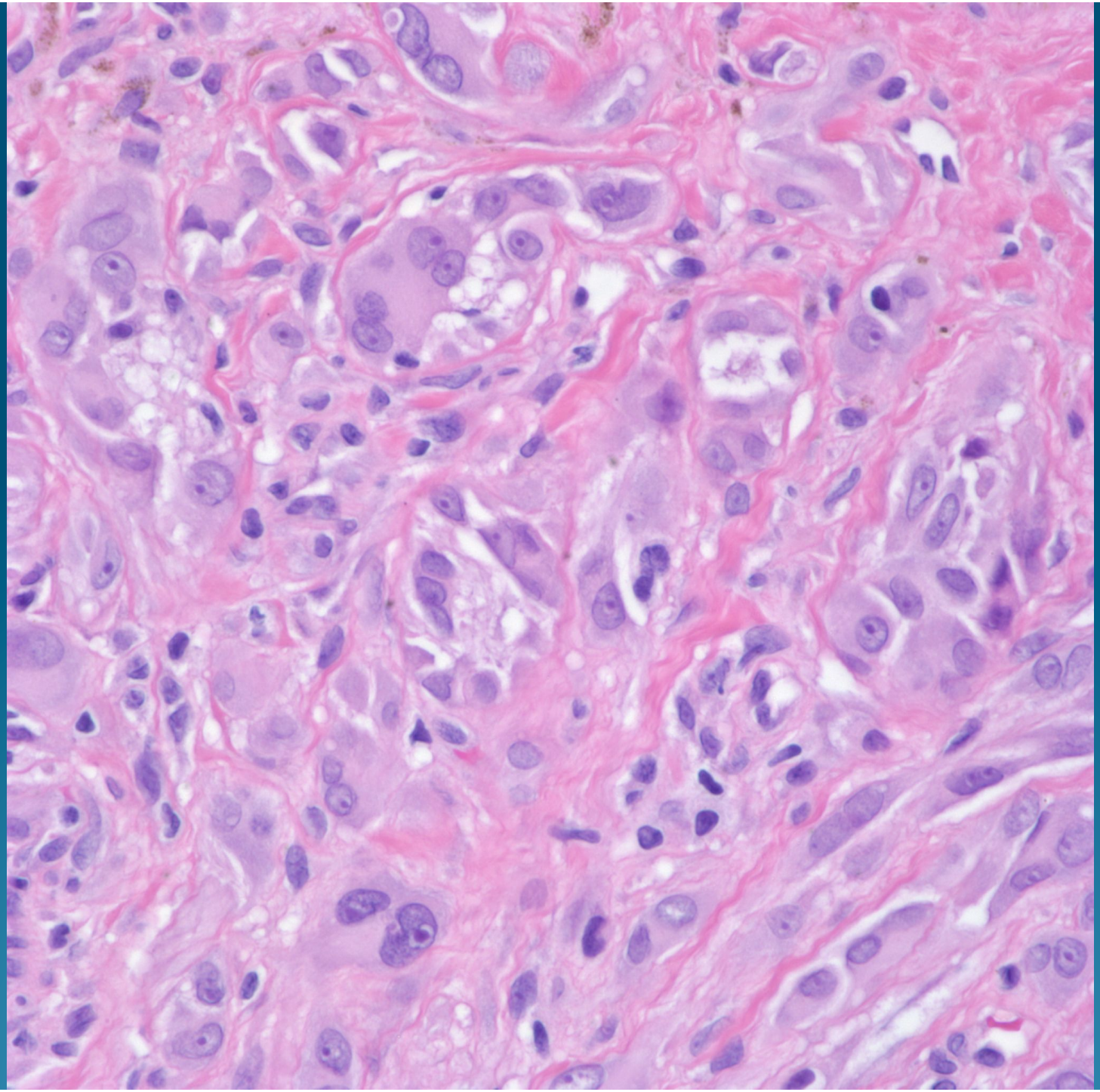

Spitz Nevus

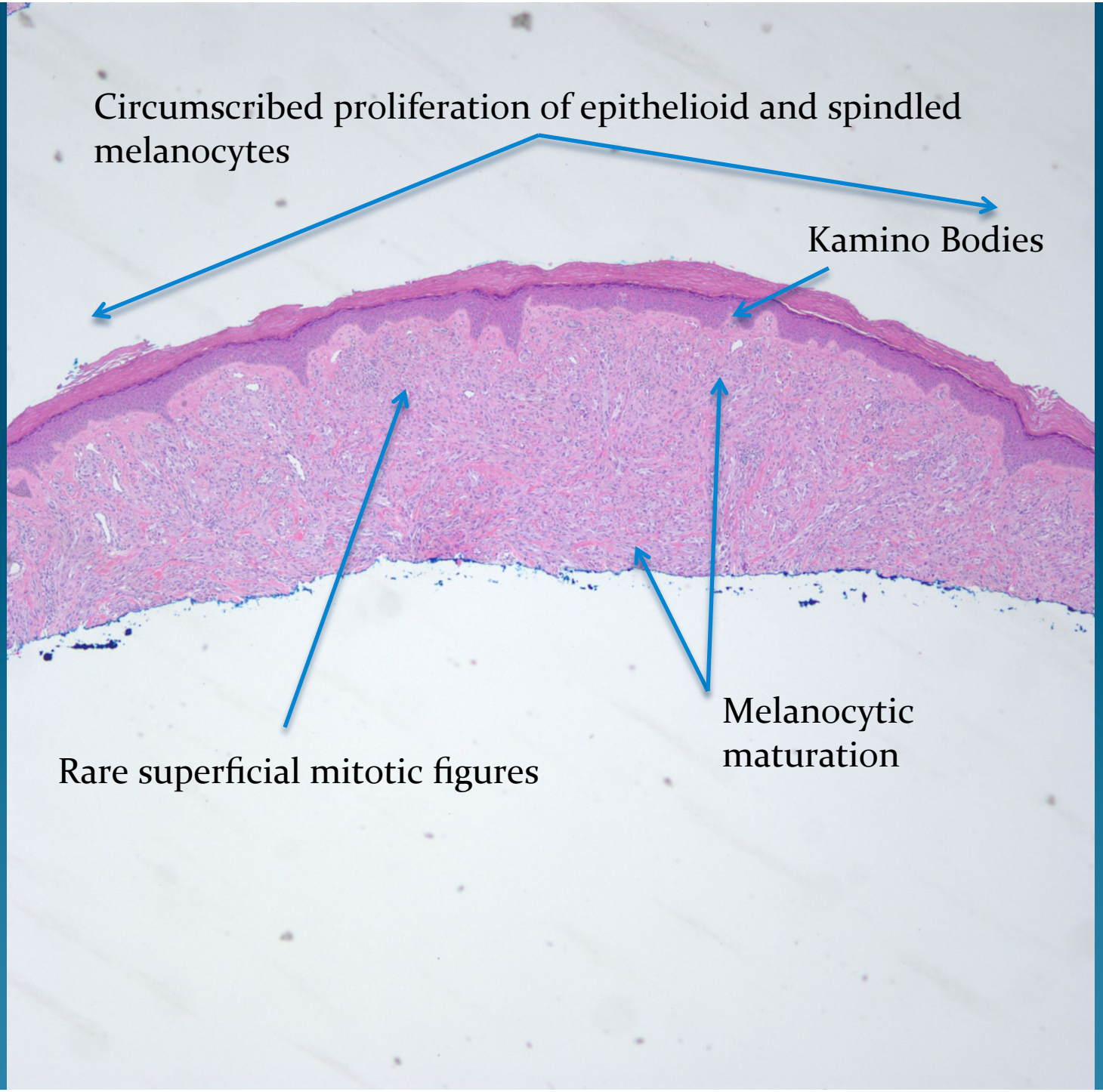
Circumscribed proliferation of epithelioid and spindled melanocytes
Kamino Bodies
Rare superficial mitotic figures
Melanocytic maturation

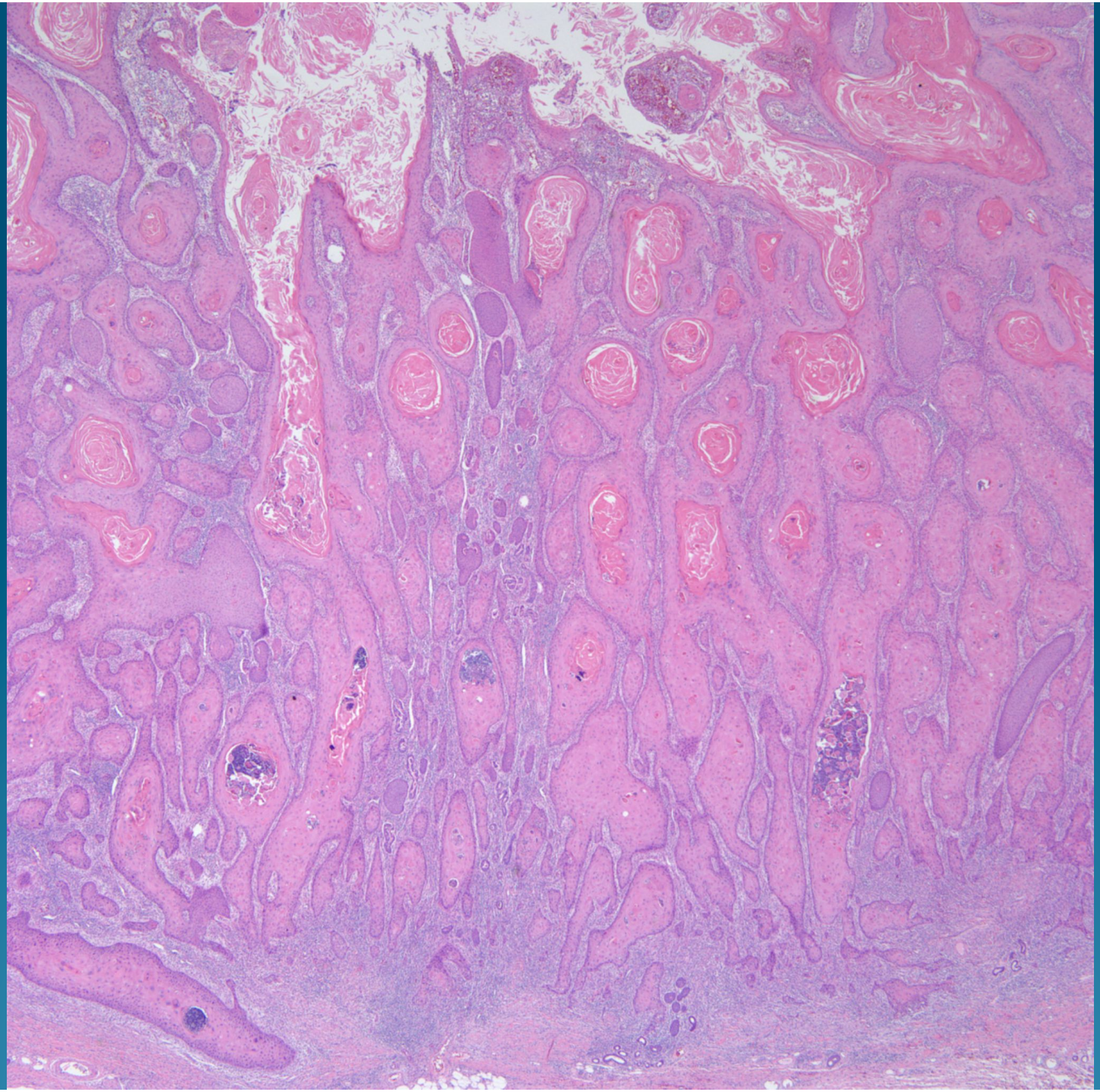

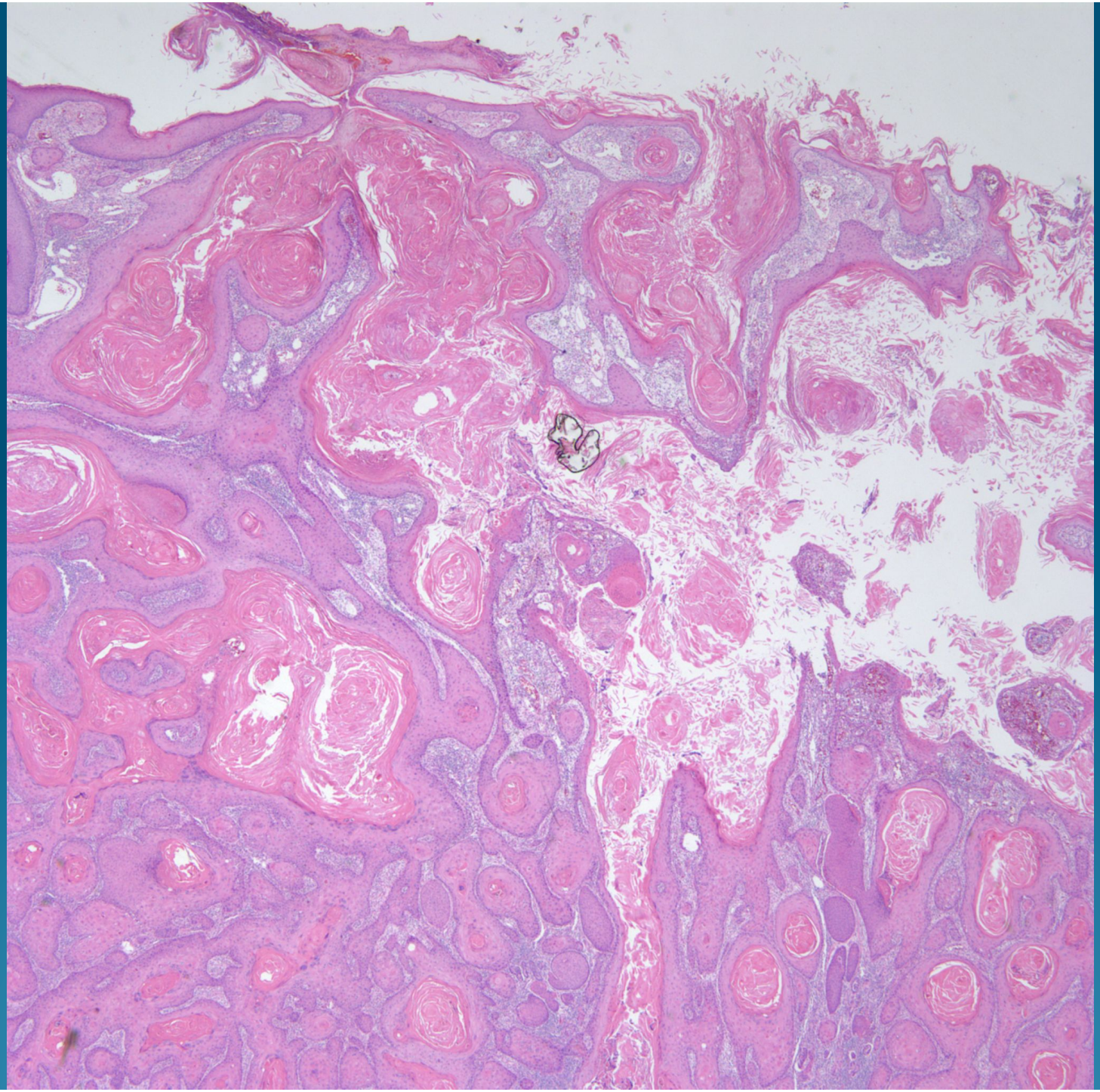

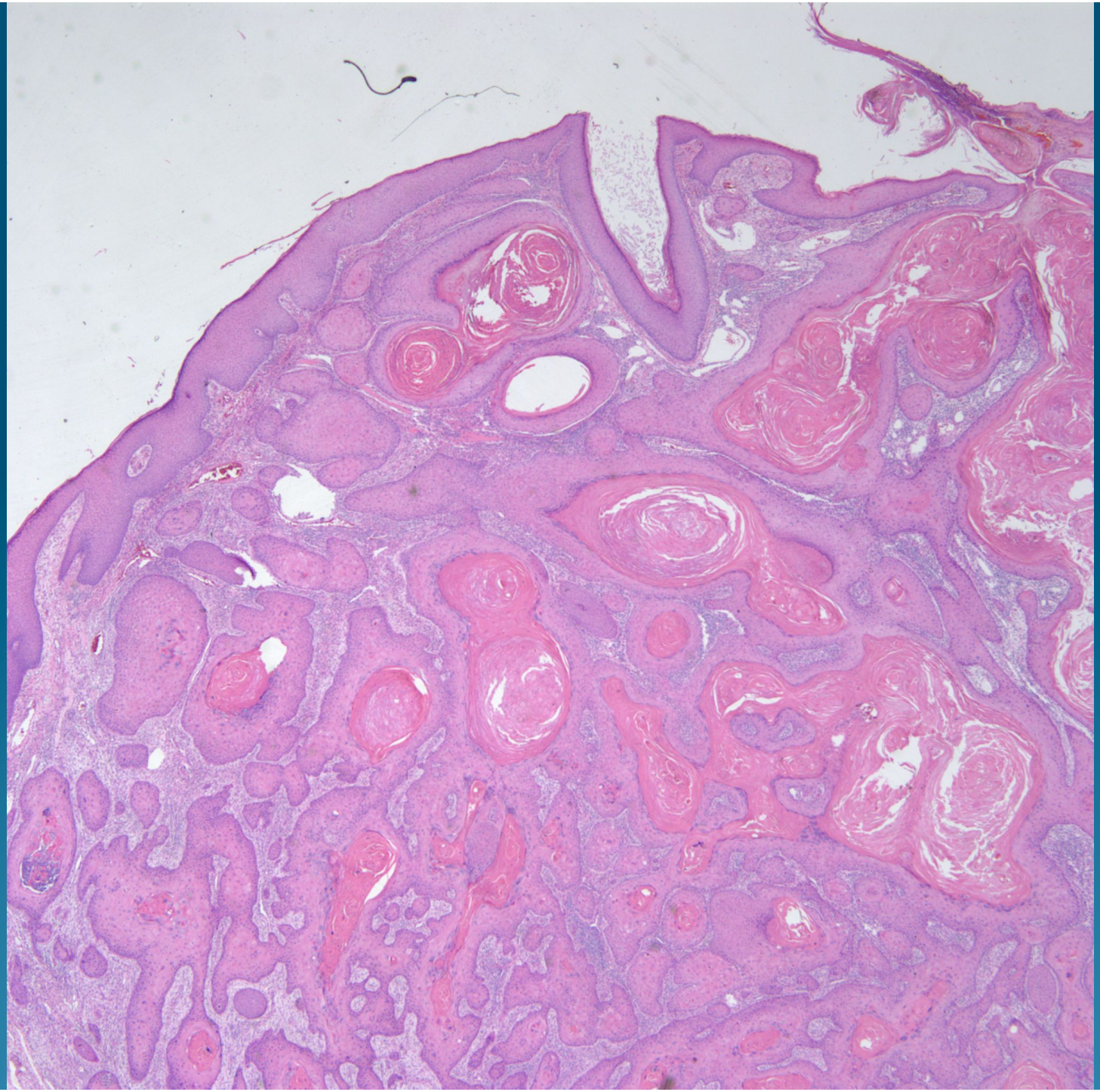

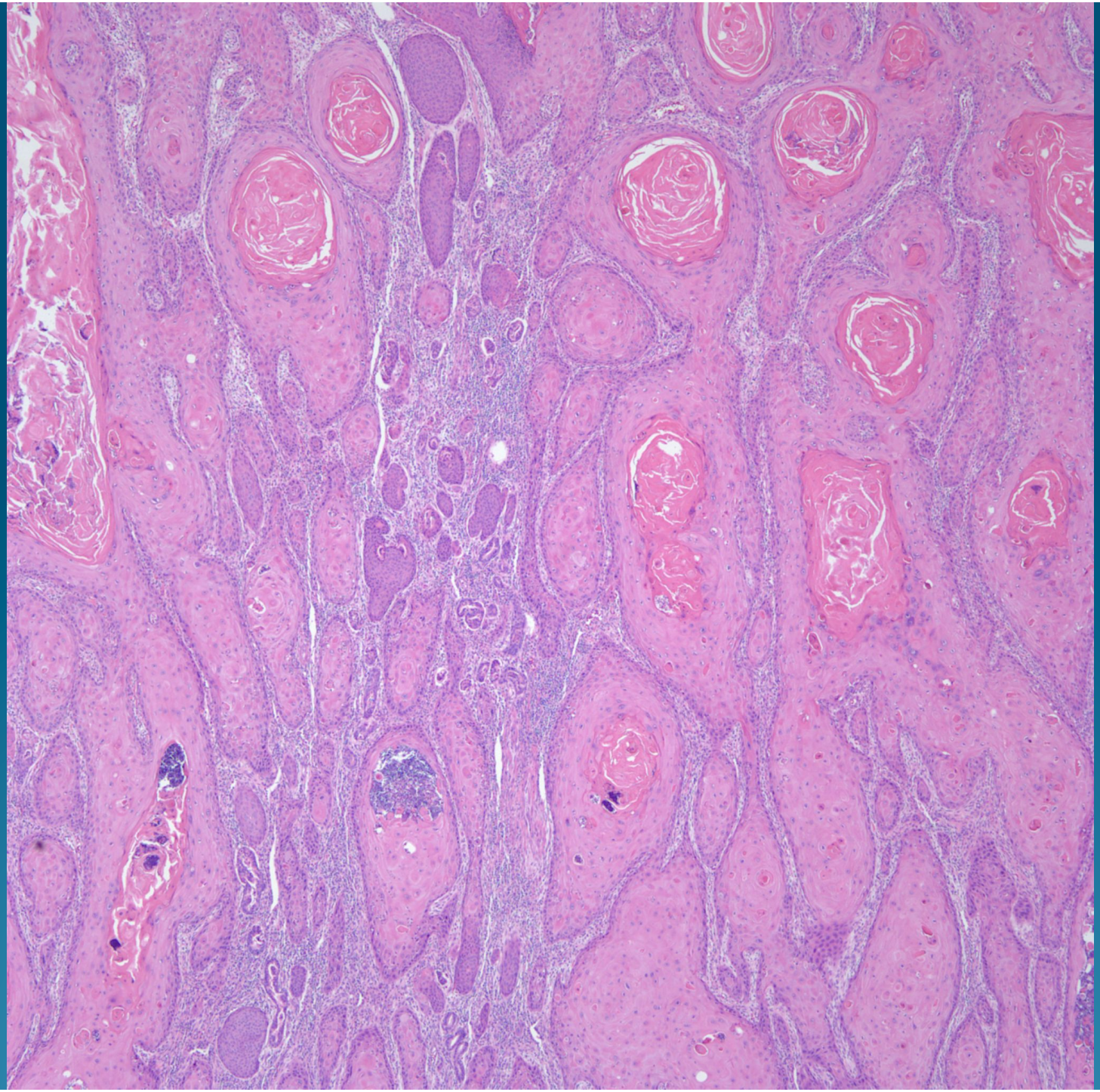

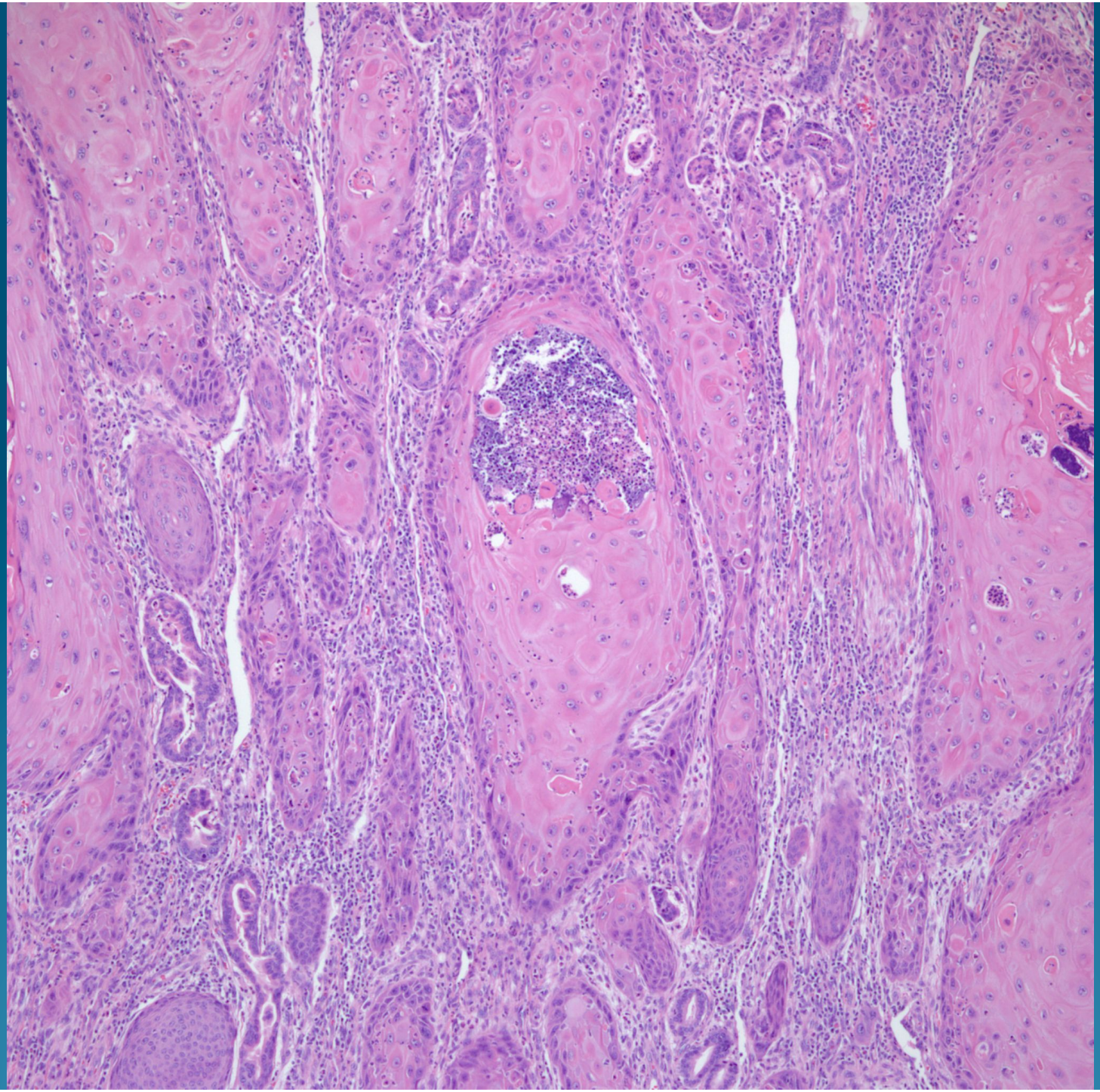

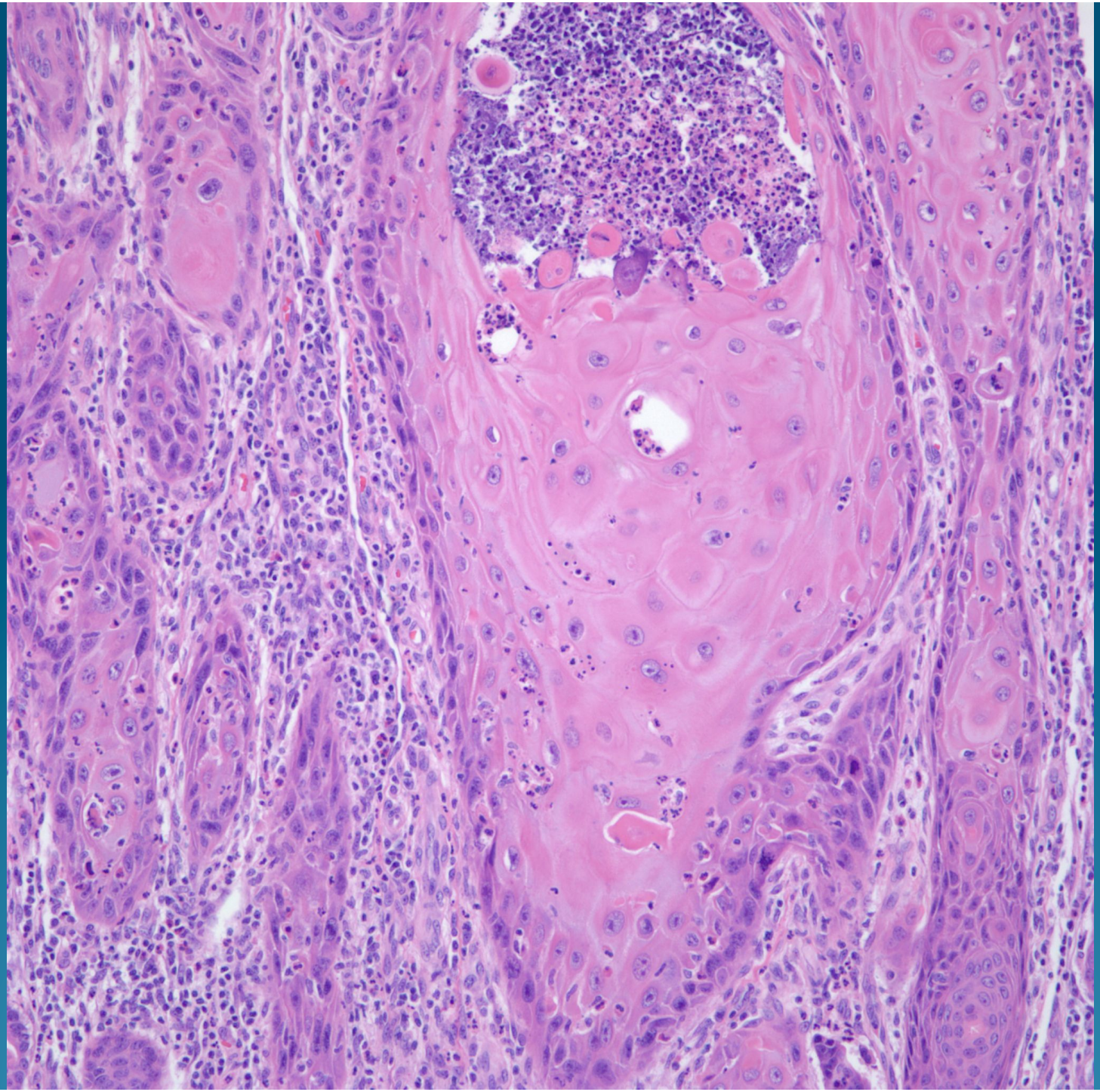

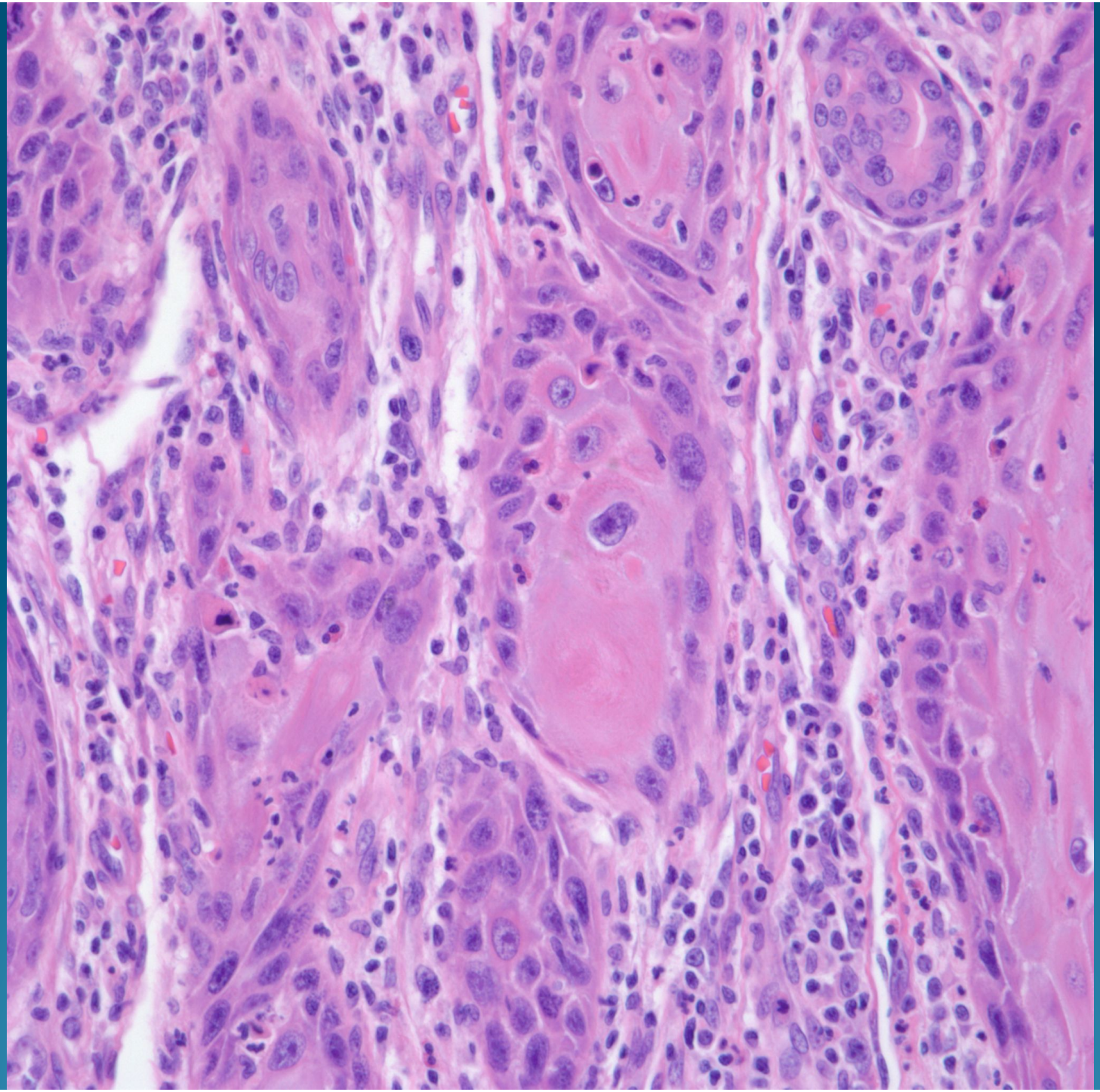

What is the best diagnosis?

A. Trichilemmal Carcinoma
B. Keratoacanthoma
C. Porocarcinoma
D. Hidradenocarcinoma
E. Halogenoderma

Keratoacanthoma

Crateri-
Form
surface

Intraepi-
Dermal
abscess

Glassy
Keratino-
cytes

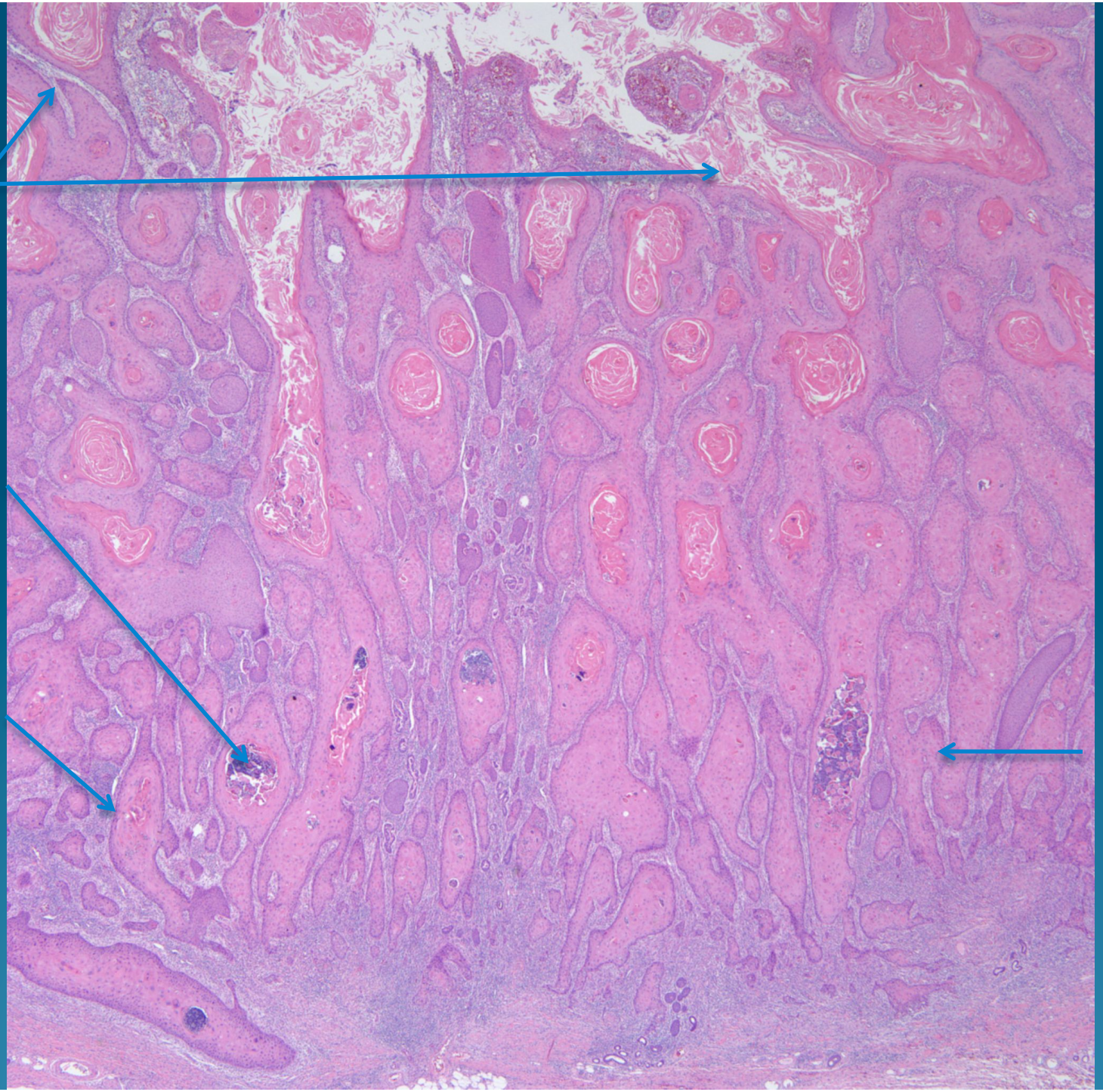

Minimal
Cytologic
atypia

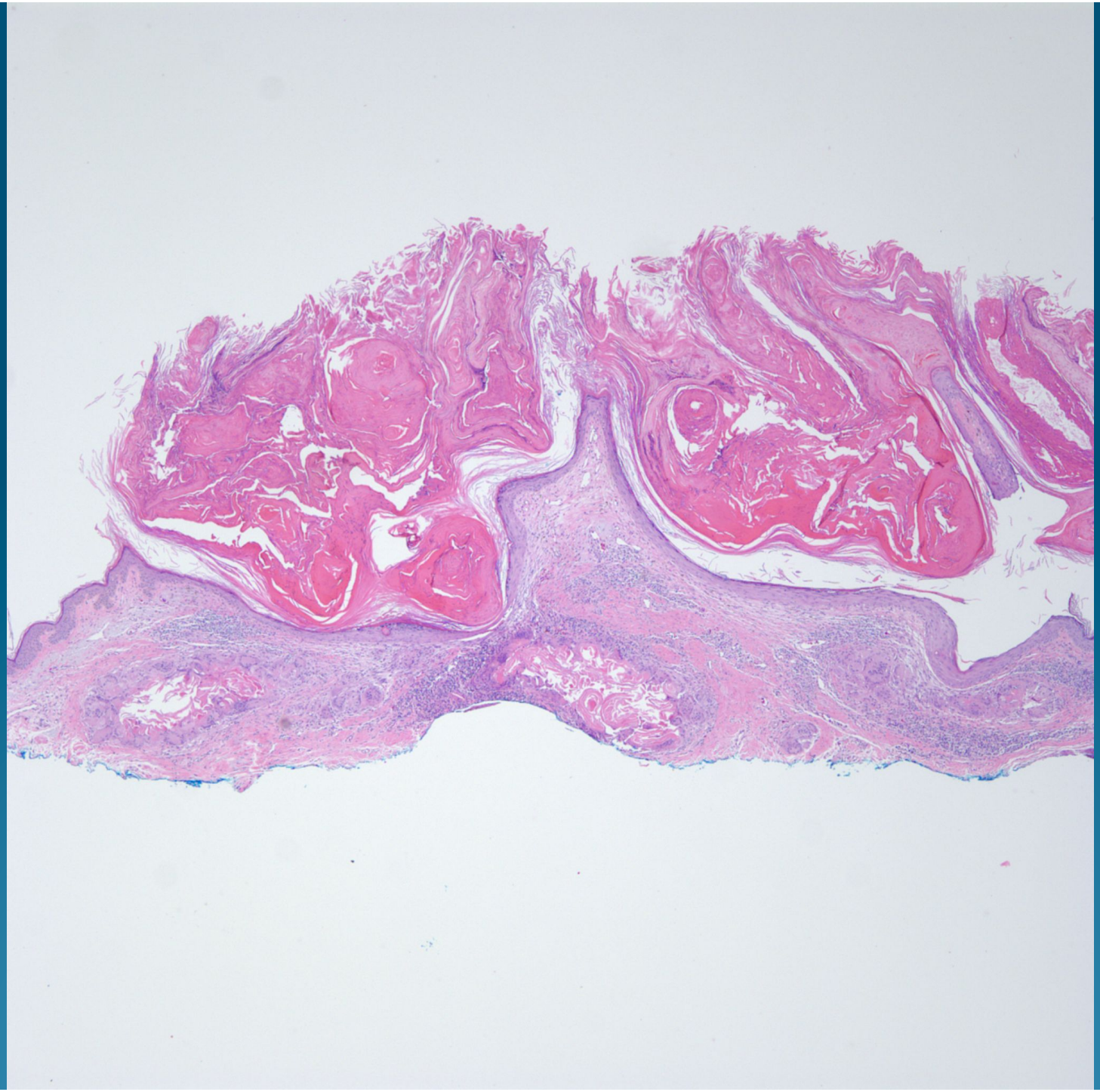

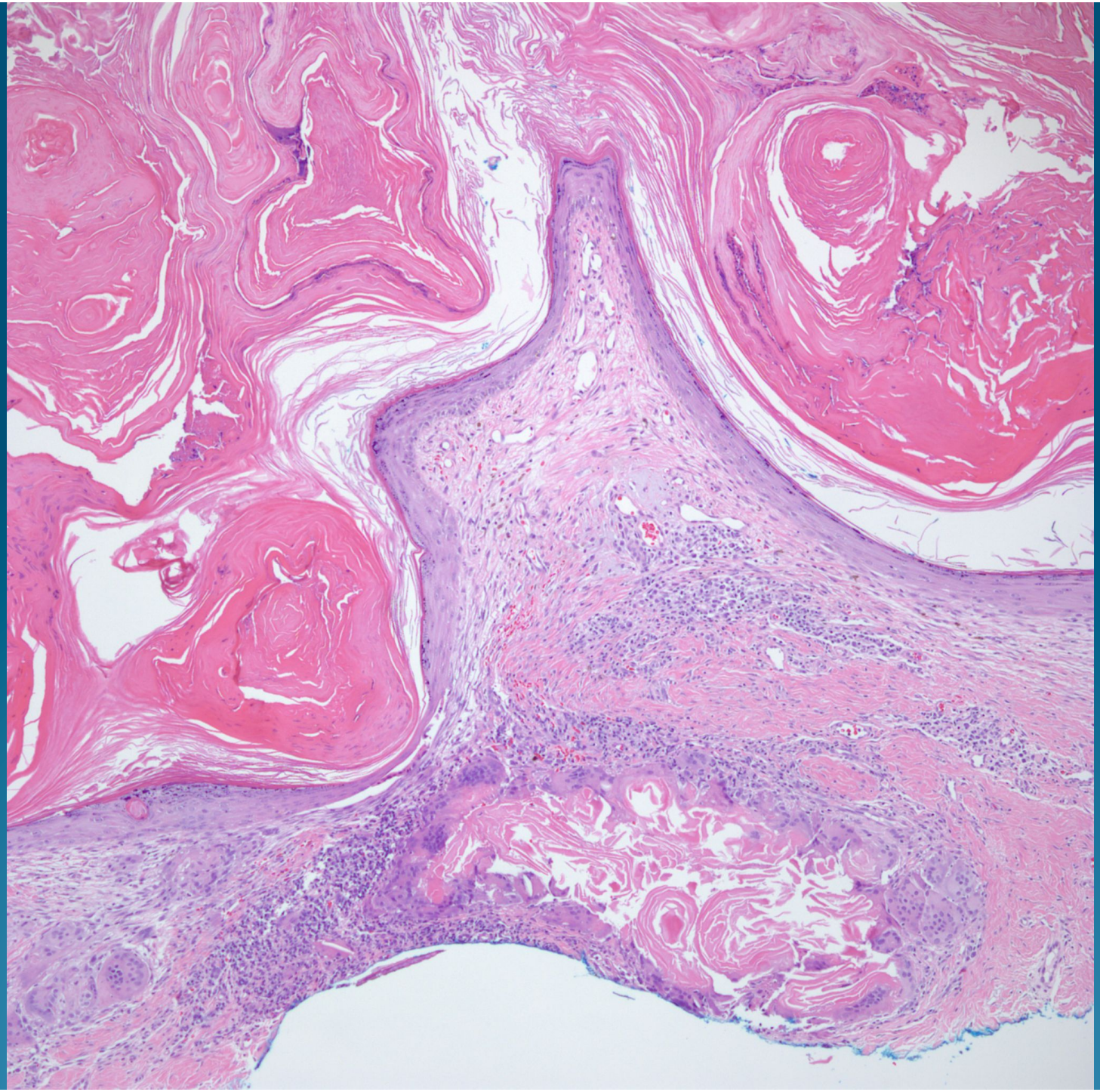

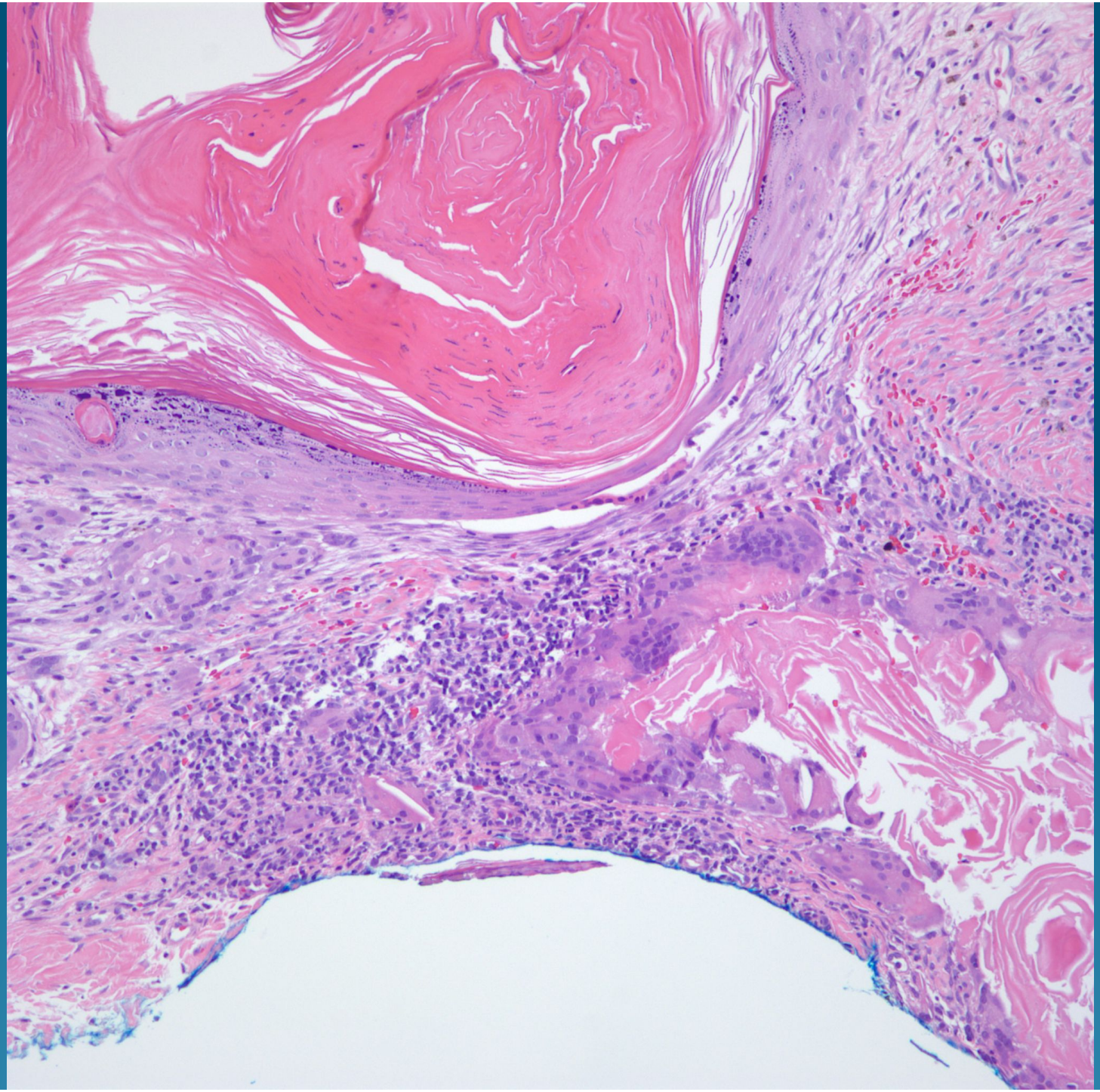

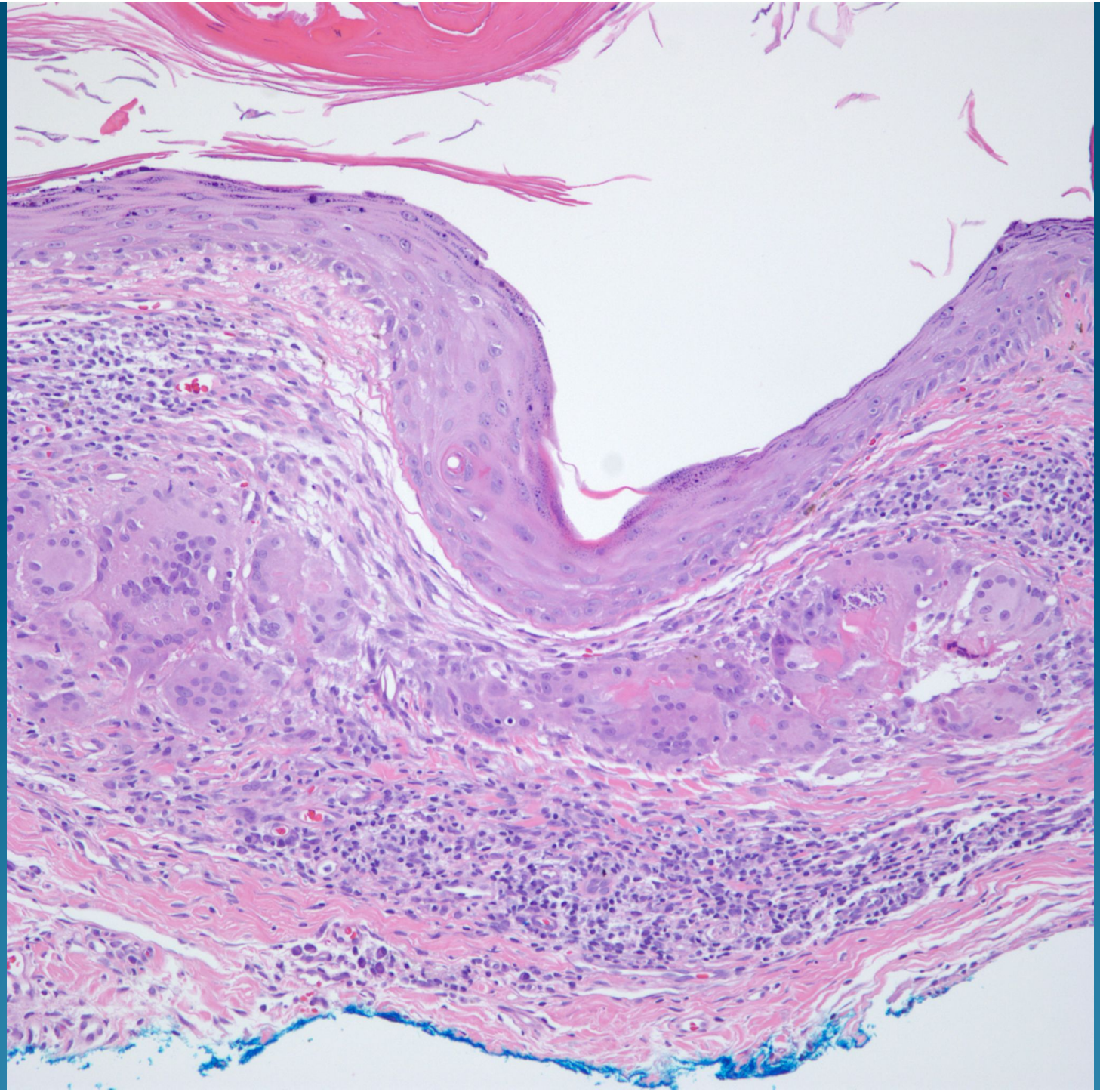

Regressed Keratoacanthoma

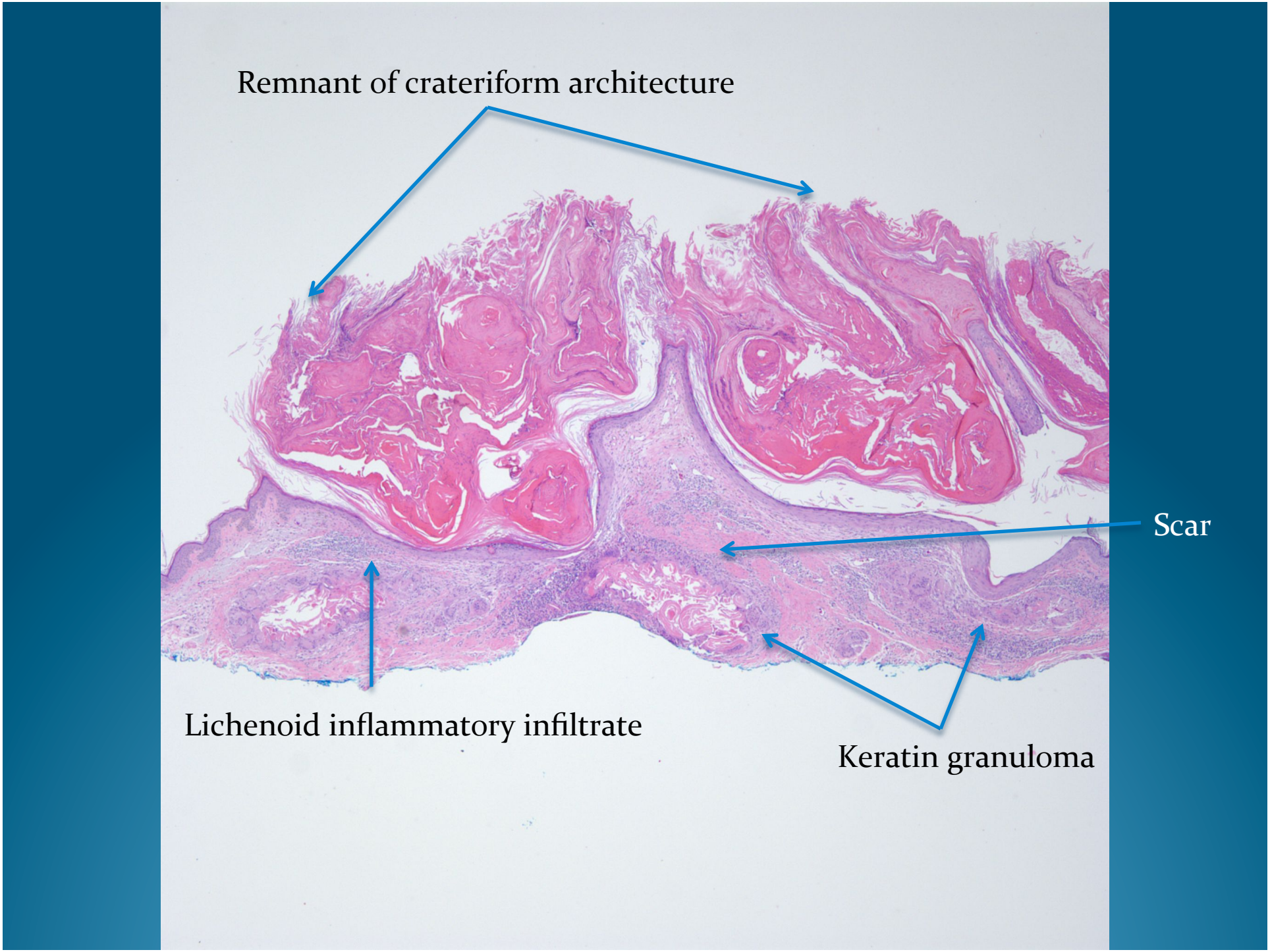
Remnant of crateriform architecture
Scar
Lichenoid inflammatory infiltrate
Keratin granuloma

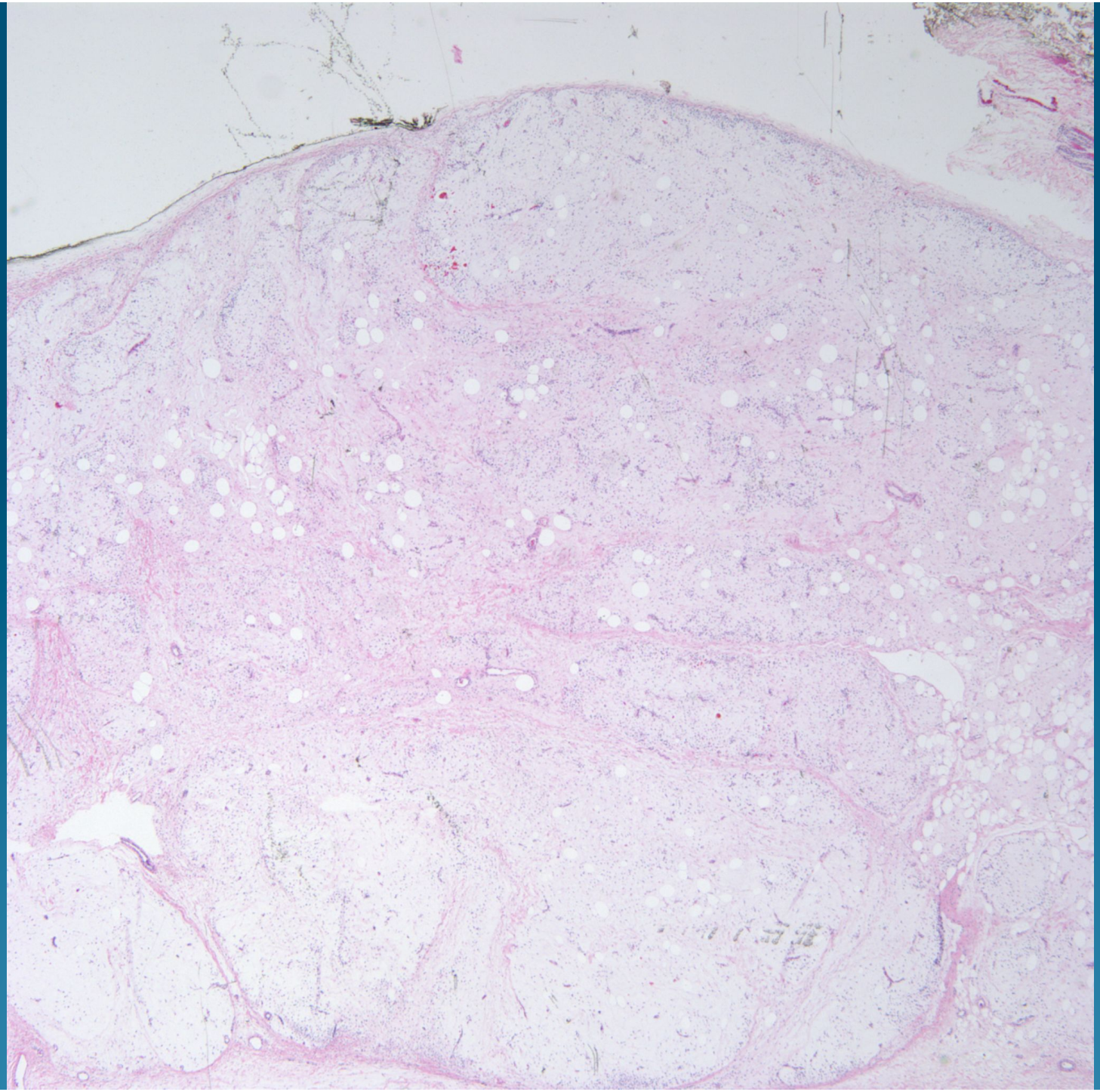

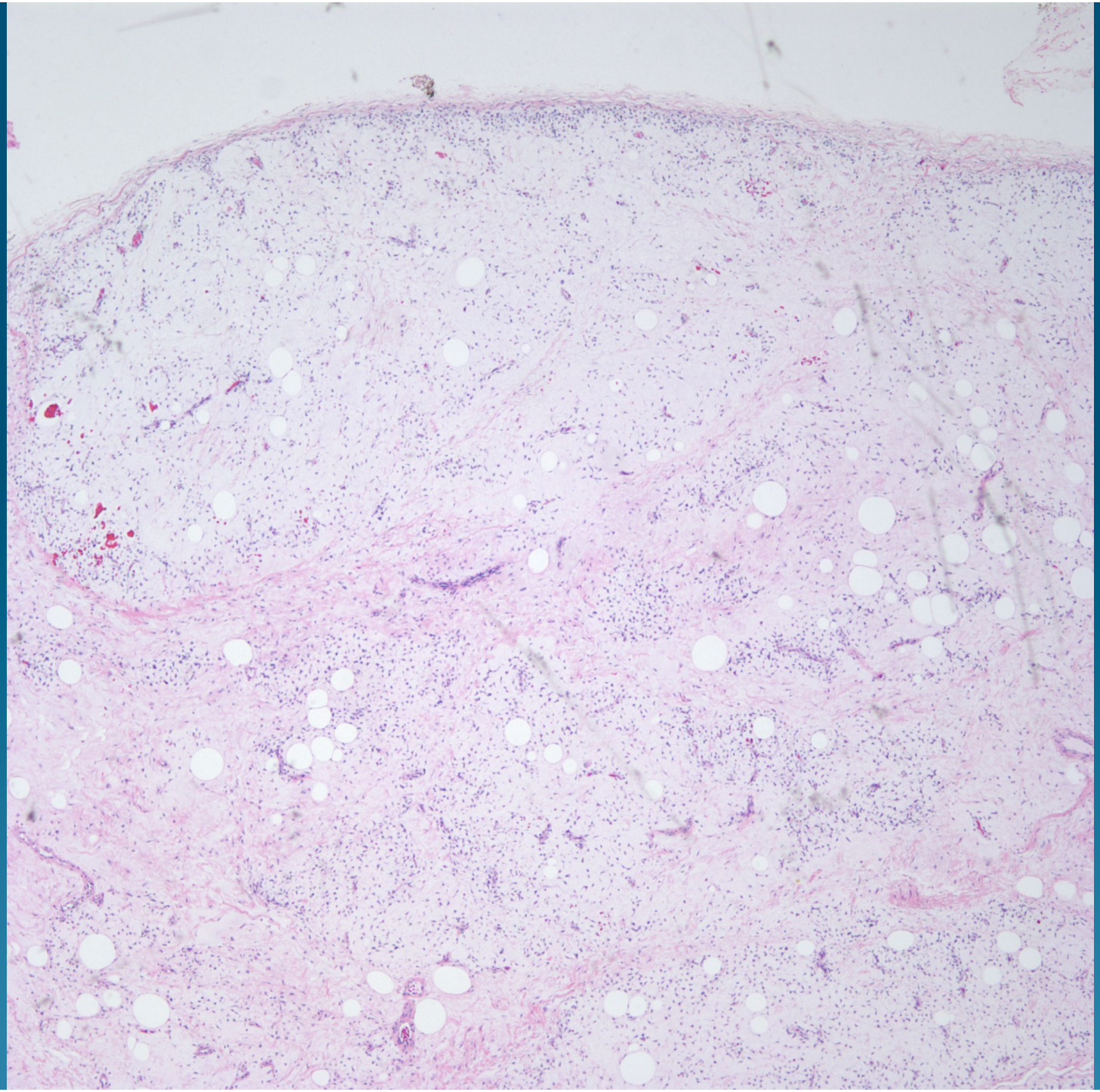

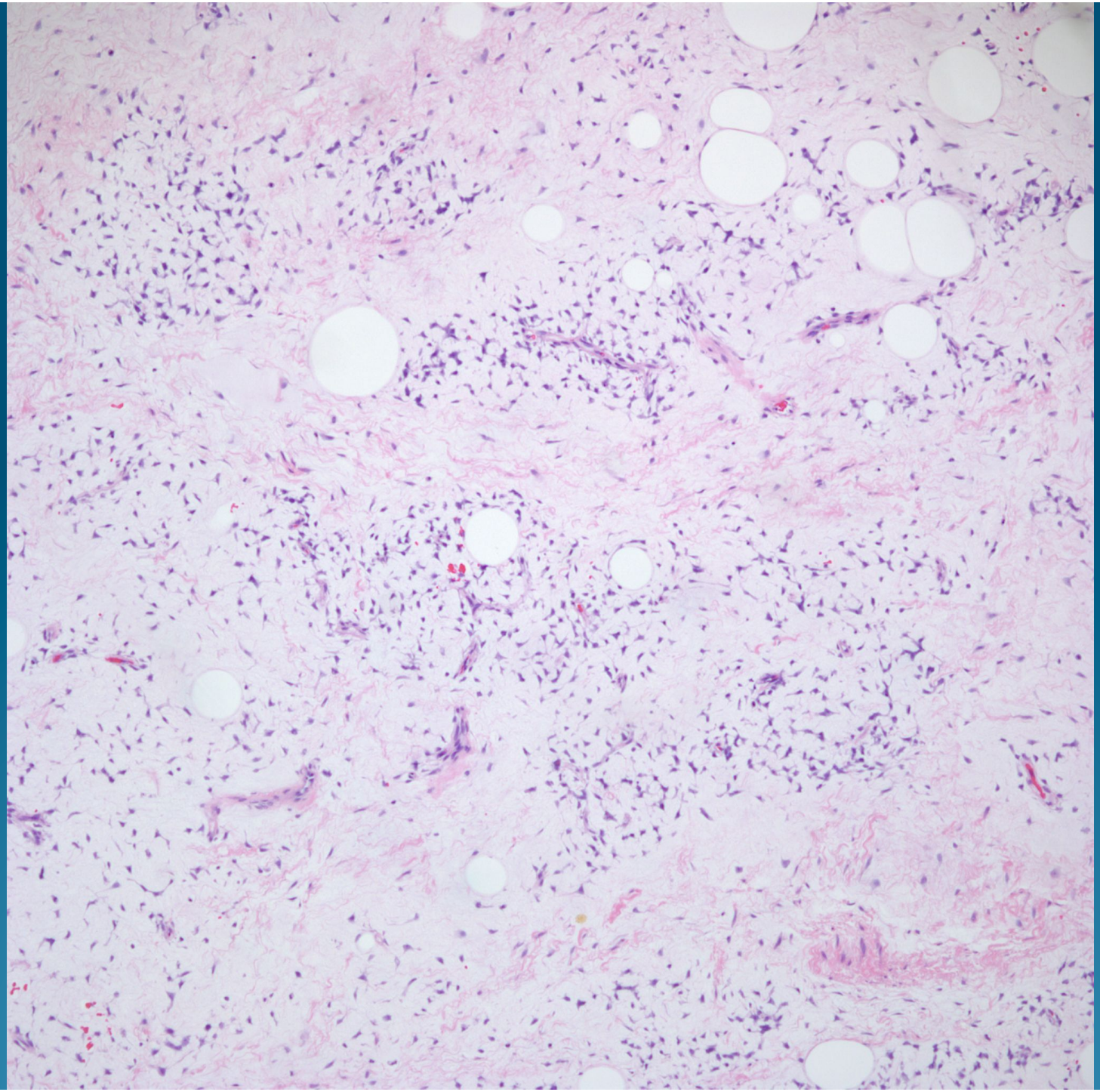

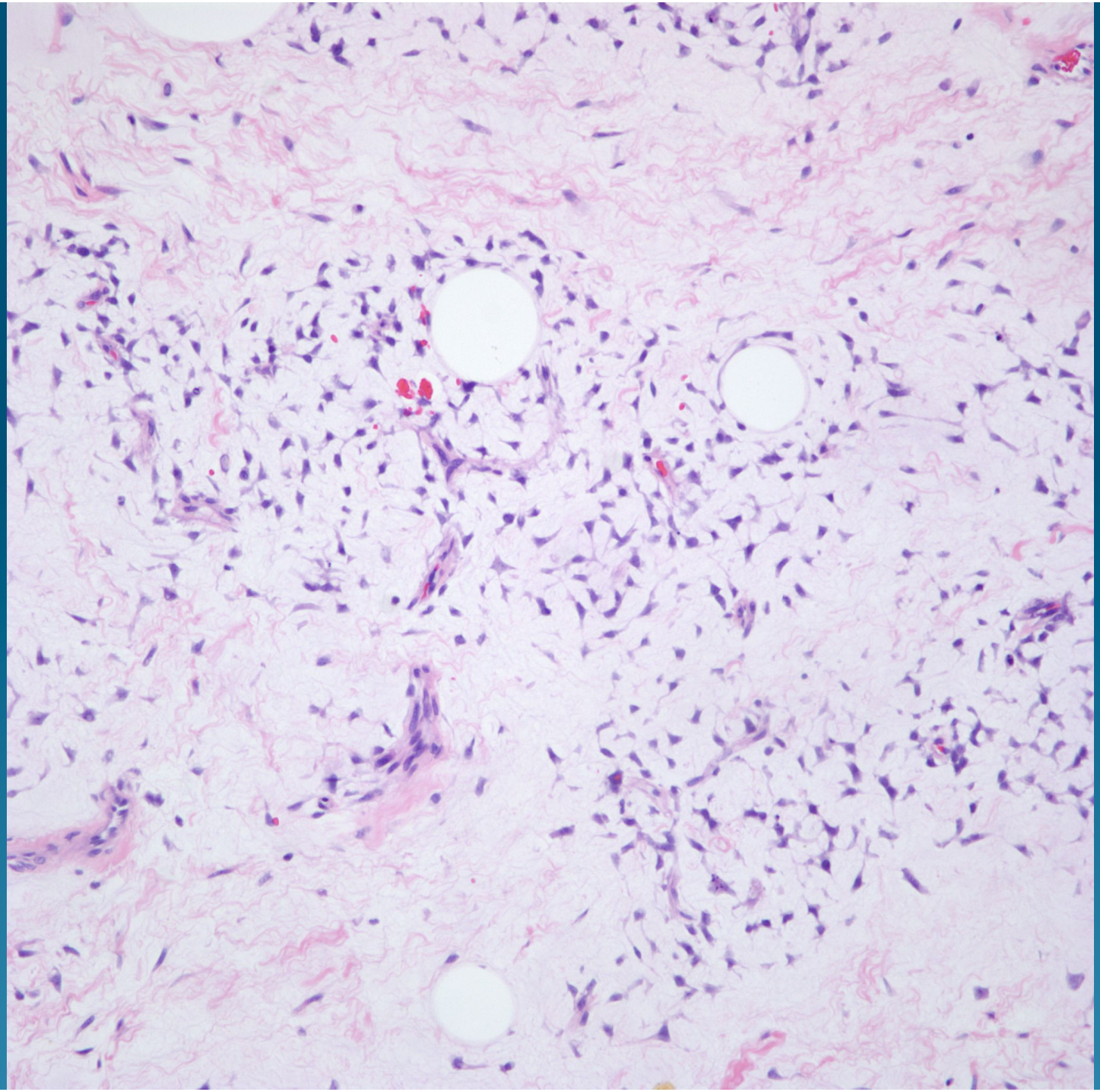

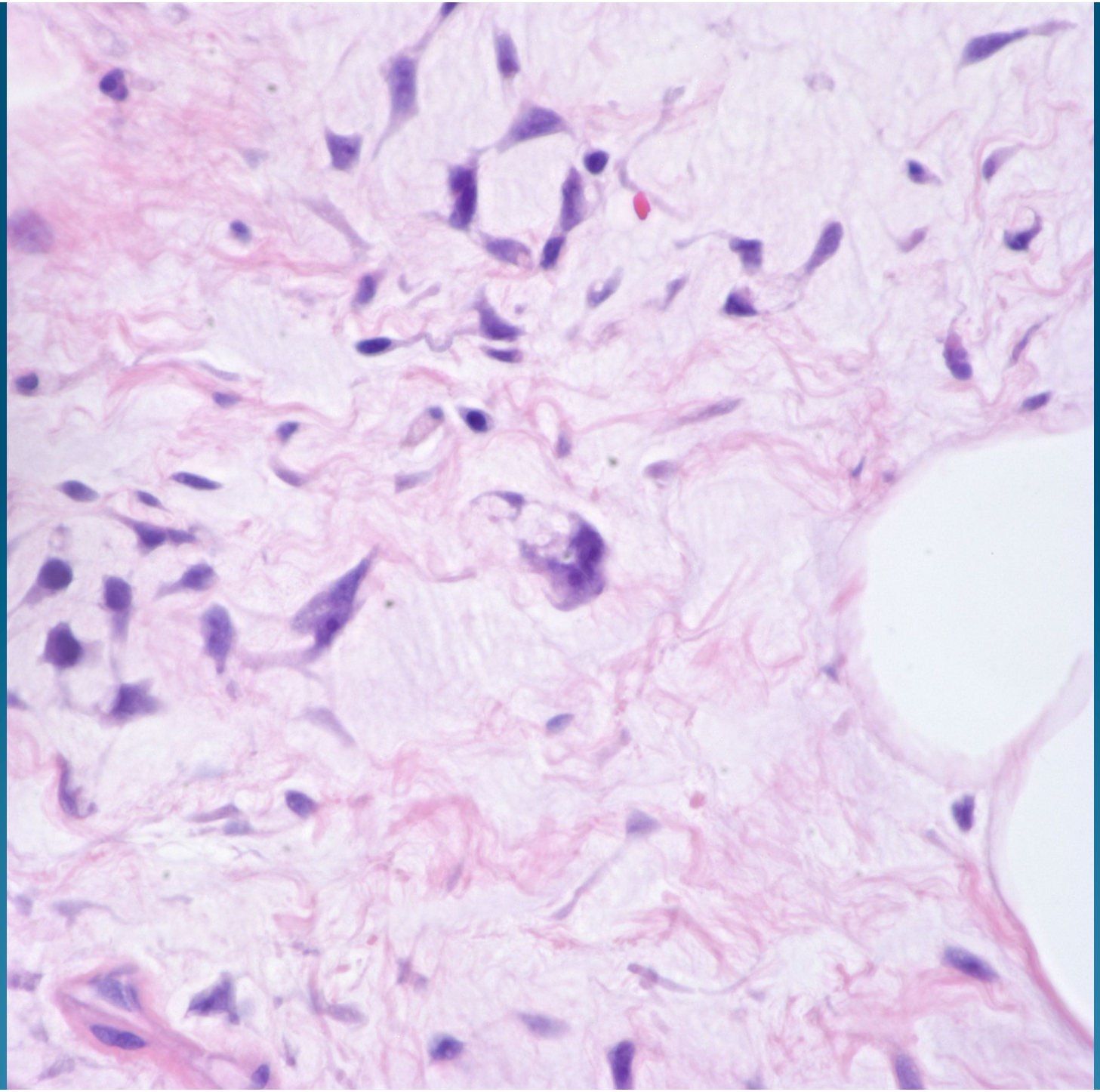

What is the best diagnosis?

A. Myxoid liposarcoma
B. Myxoid malignant fibrous histiocytoma
C. Schwannoma
D. Myxoma
E. Lipoblastoma

Lipoblastoma

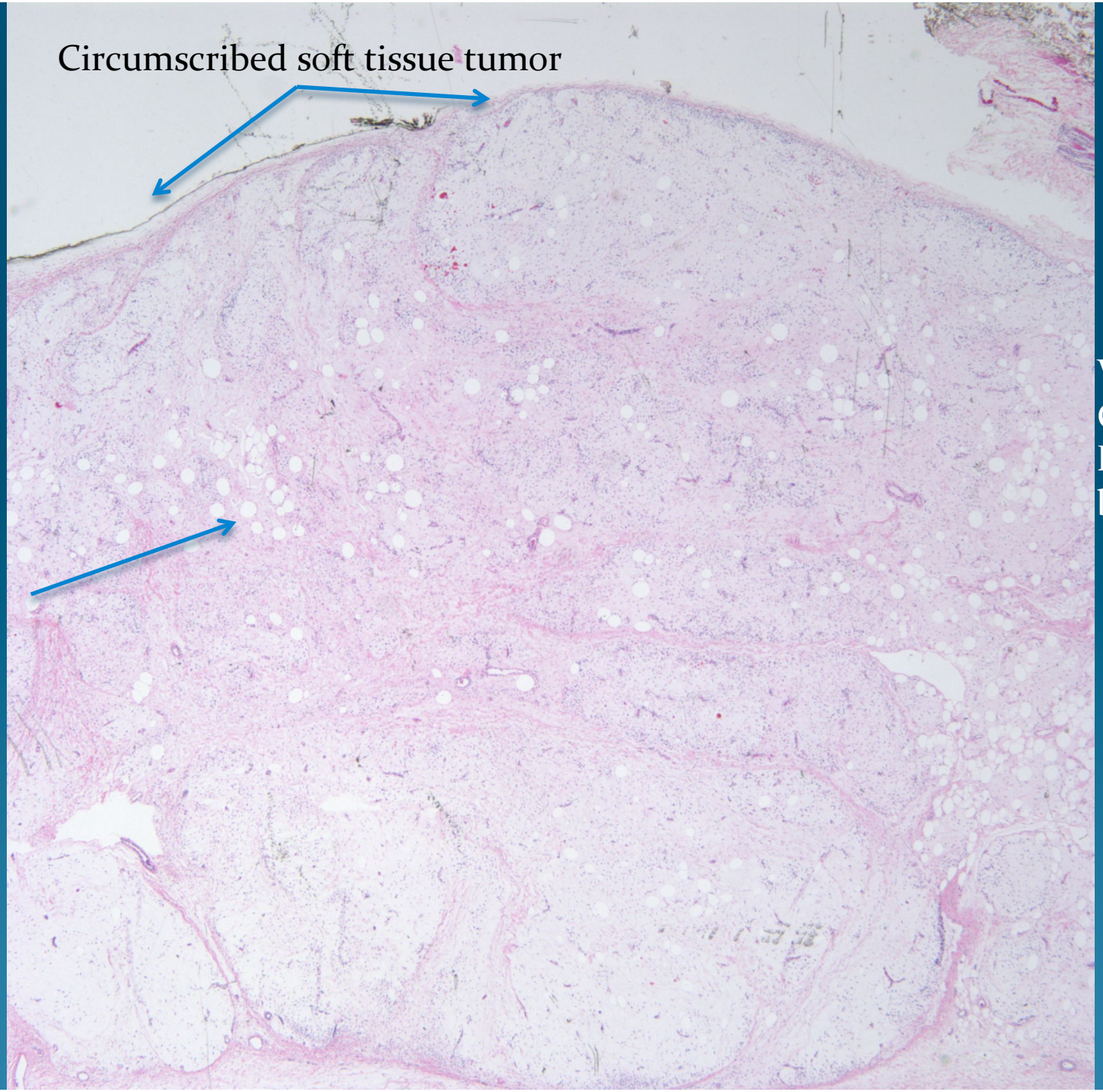
Circumscribed soft tissue tumor
Lipoblasts
Variable Cellularity
Myxoid background