Dermatopathology Slide Review Part 106

Paul K. Shitabata, M.D.
Dermatopathology Institute
Torrance, CA

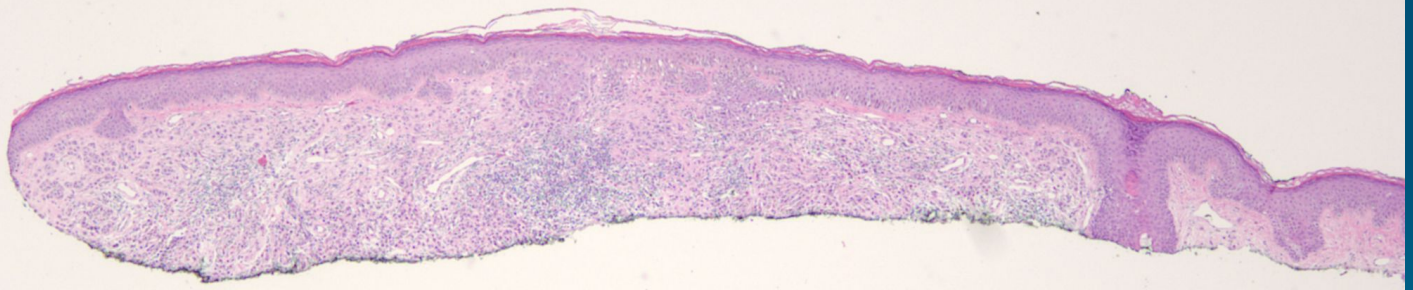

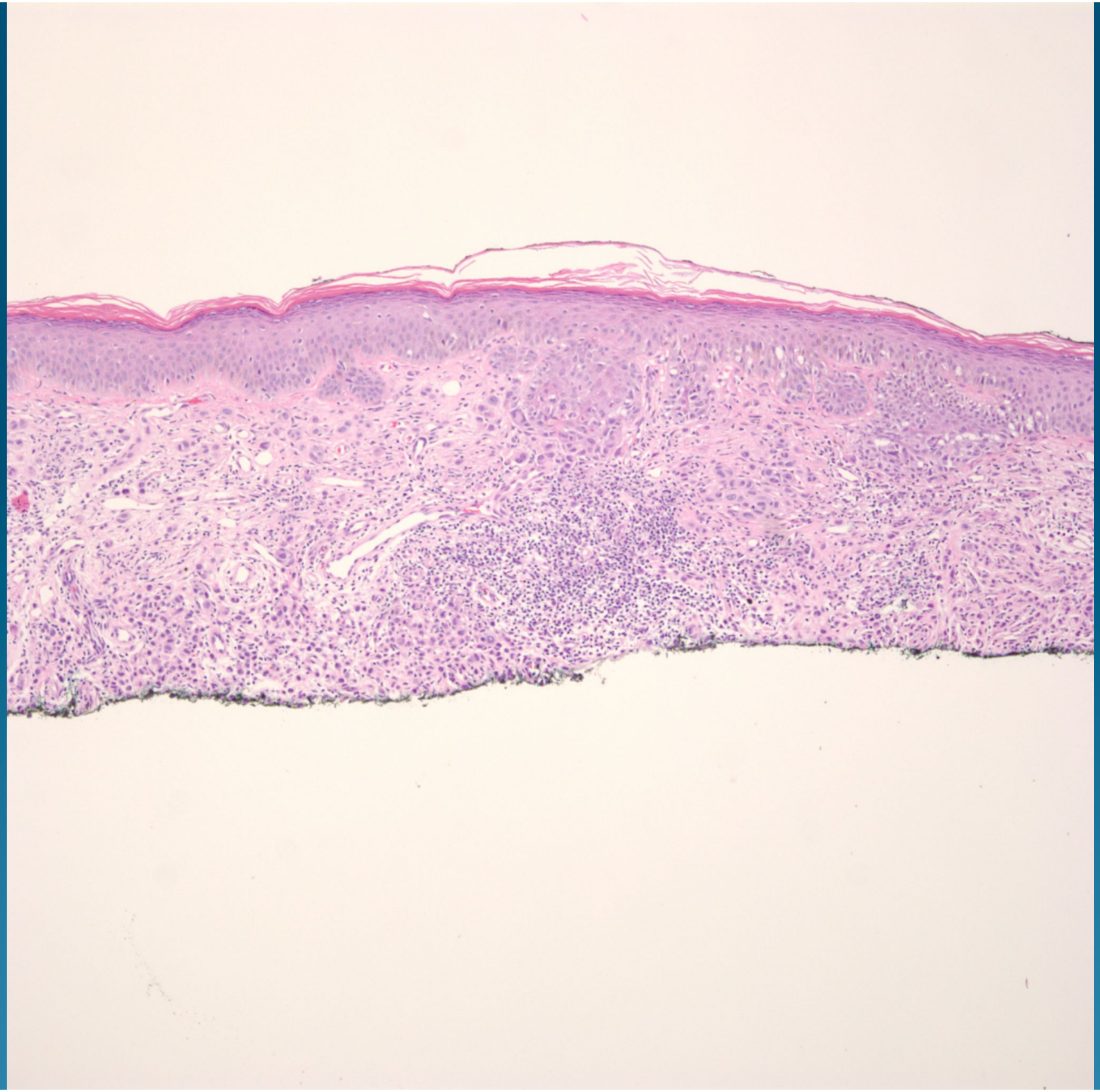

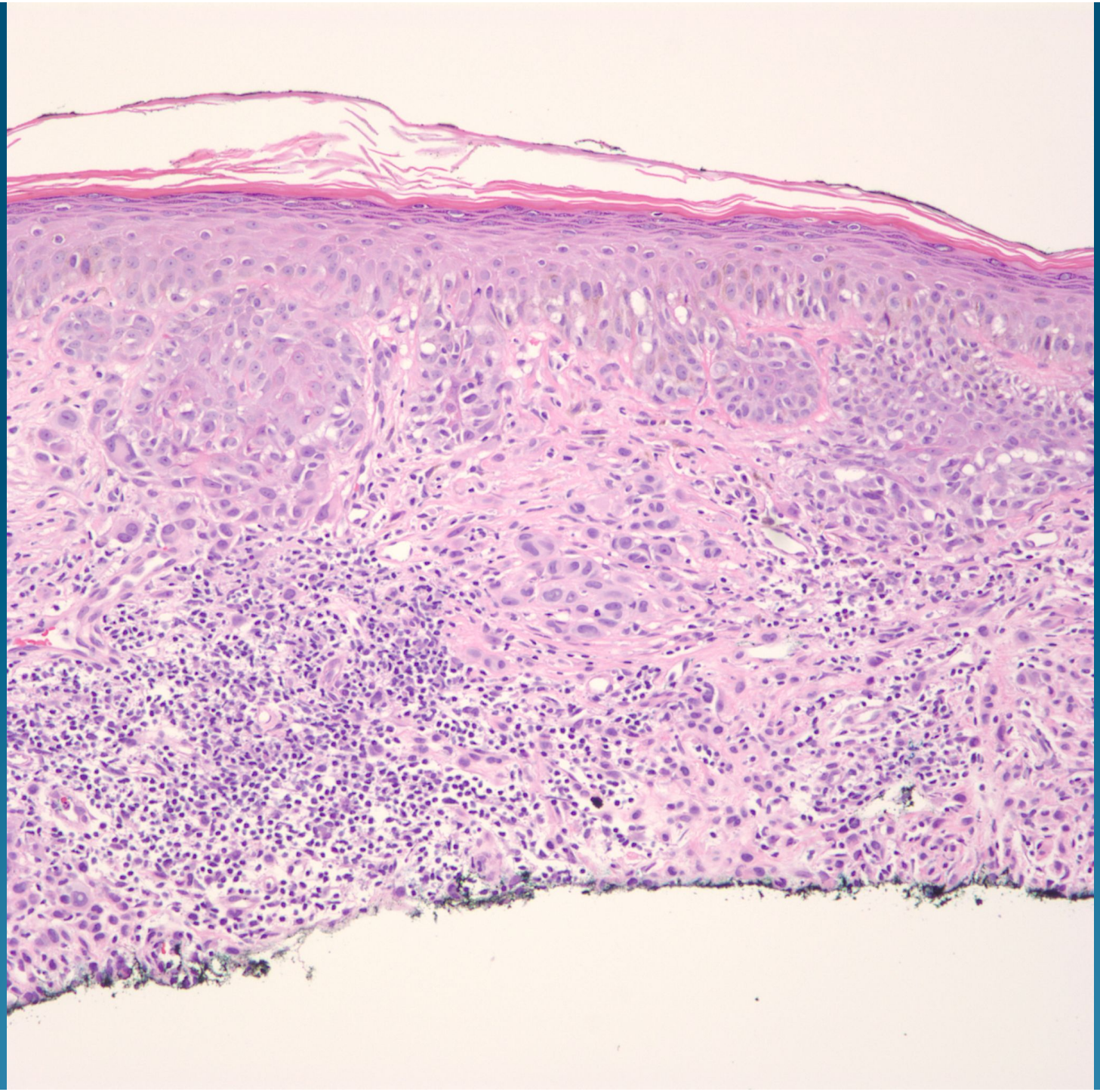

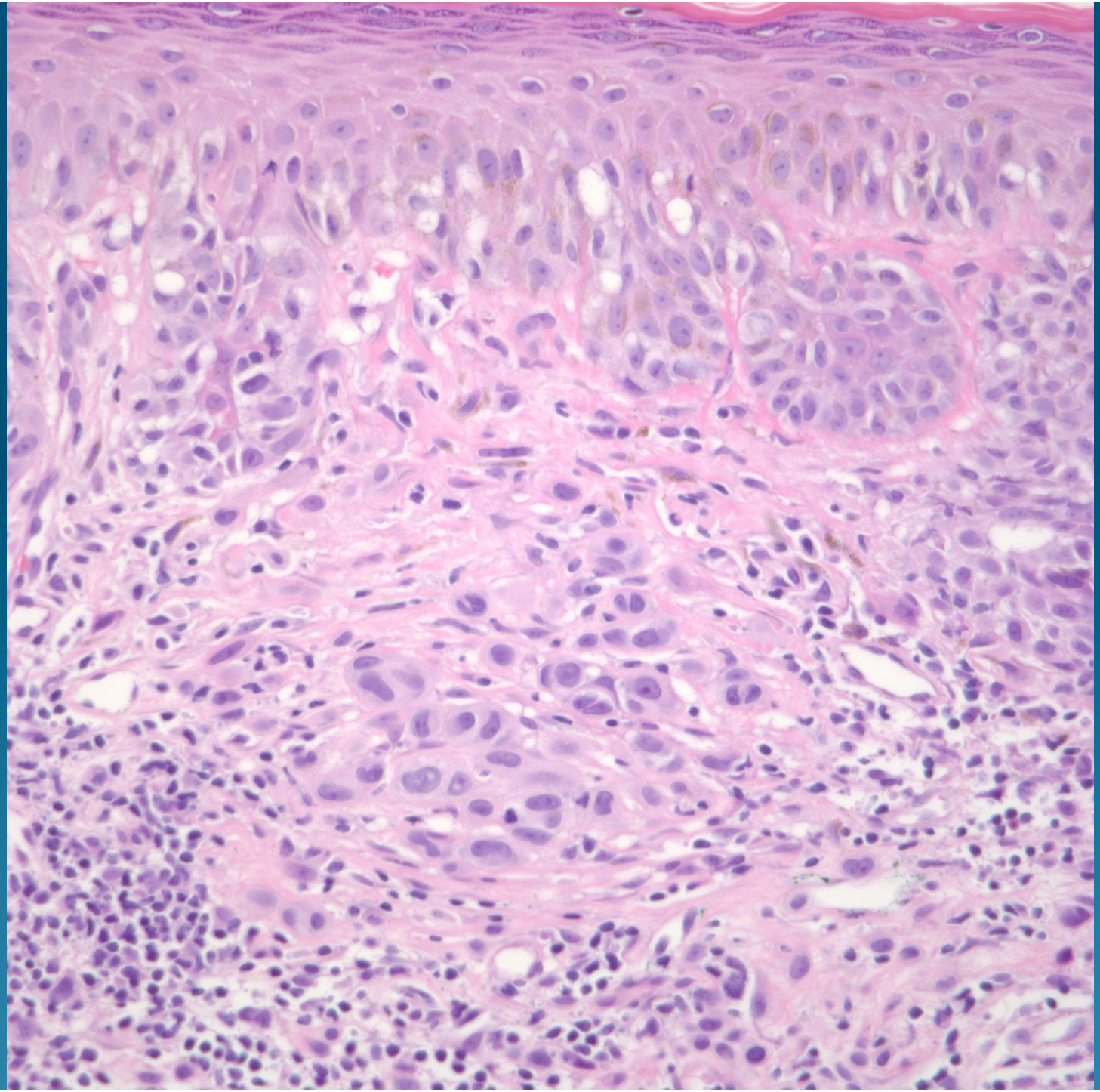

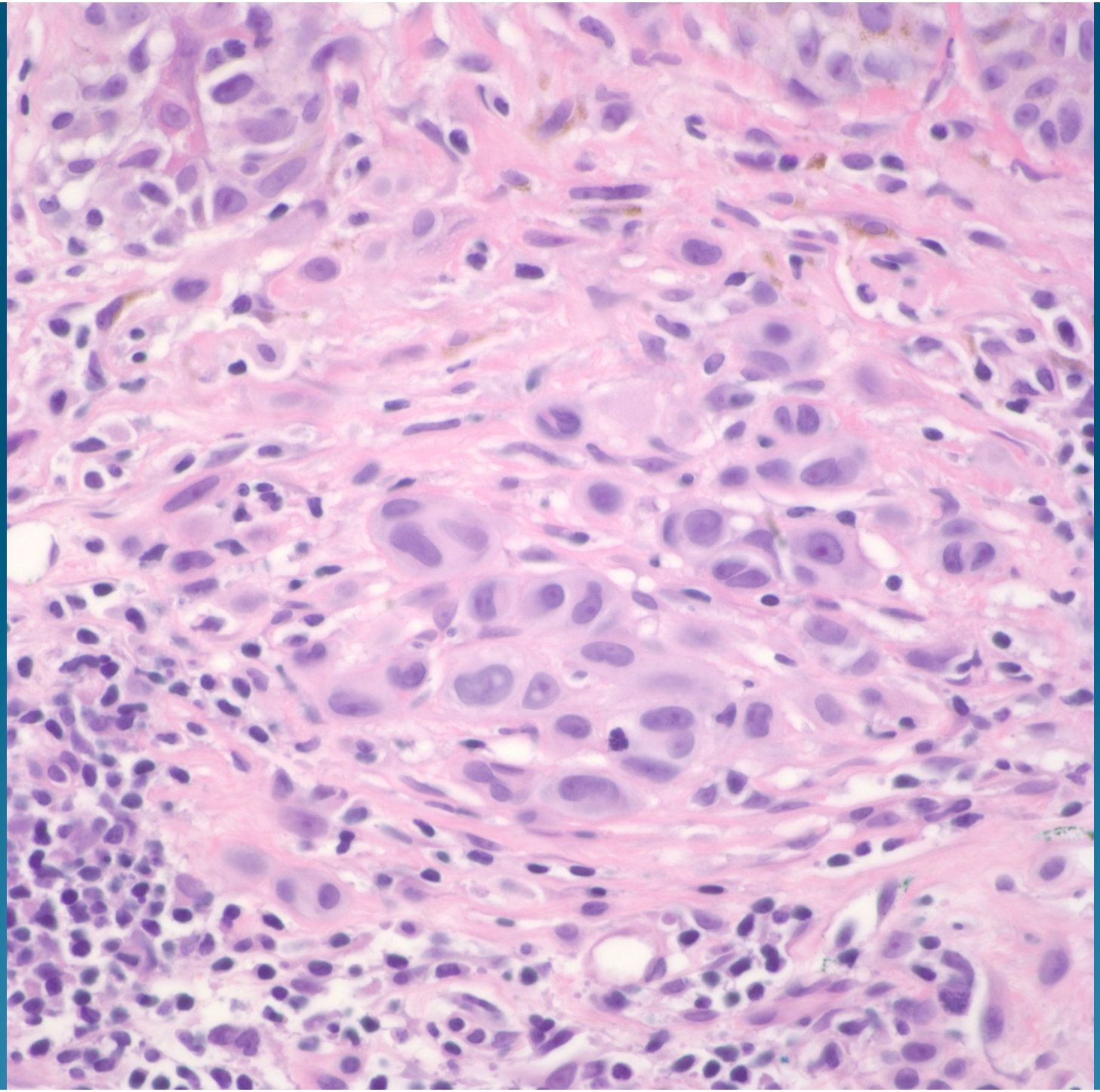

Malignant Melanoma, Nevoid Type

Pearls

- Silhouette of benign melanocytic nevus
- Cytologic atypia pronounced, especially within deeper dermal melanocytes with prominent nucleoli
- Atypical mitotic figures
- Varied chronic inflammatory cell host response
- Ki-67 or FISH studies may assist in confirming the diagnosis

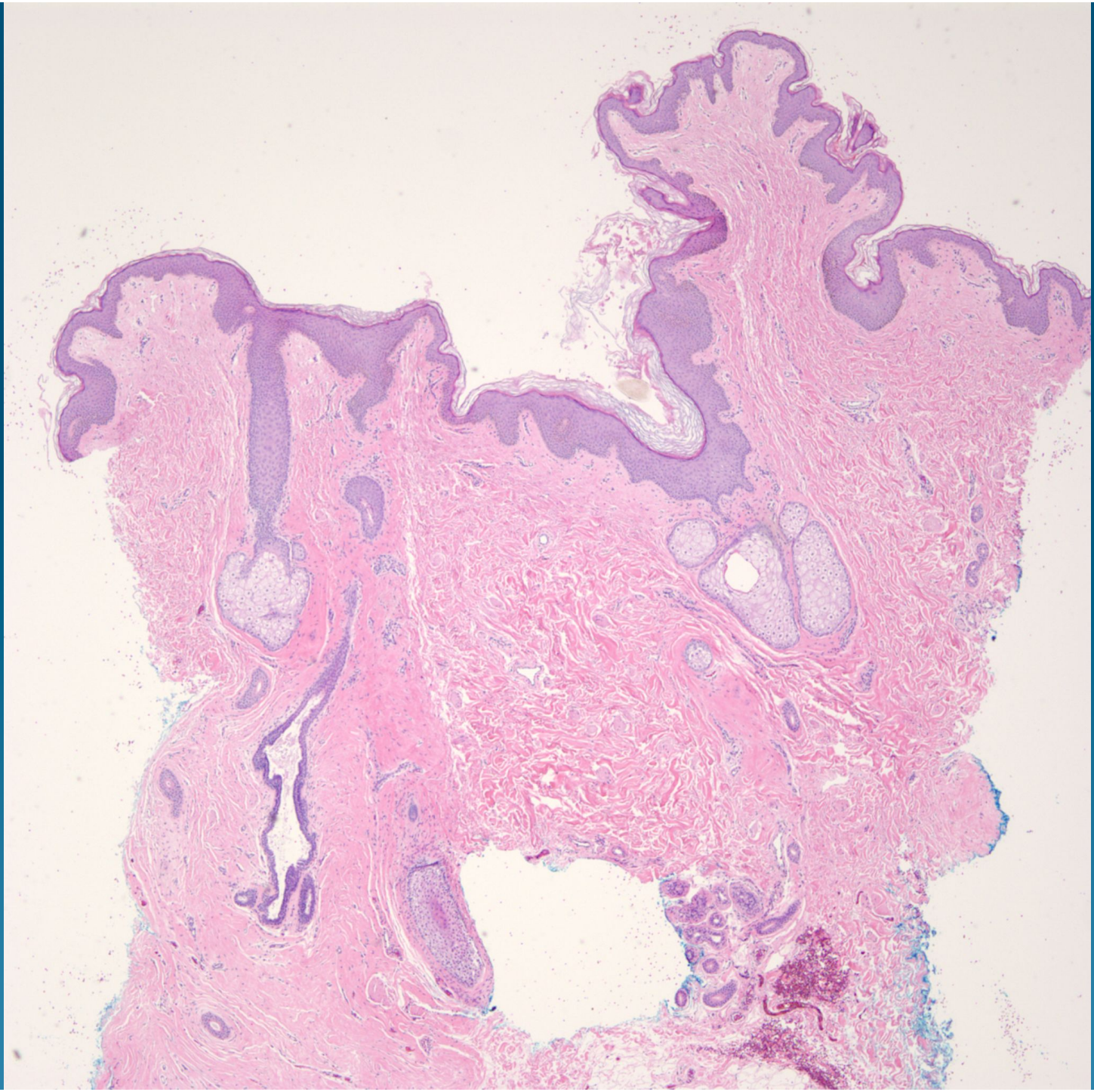

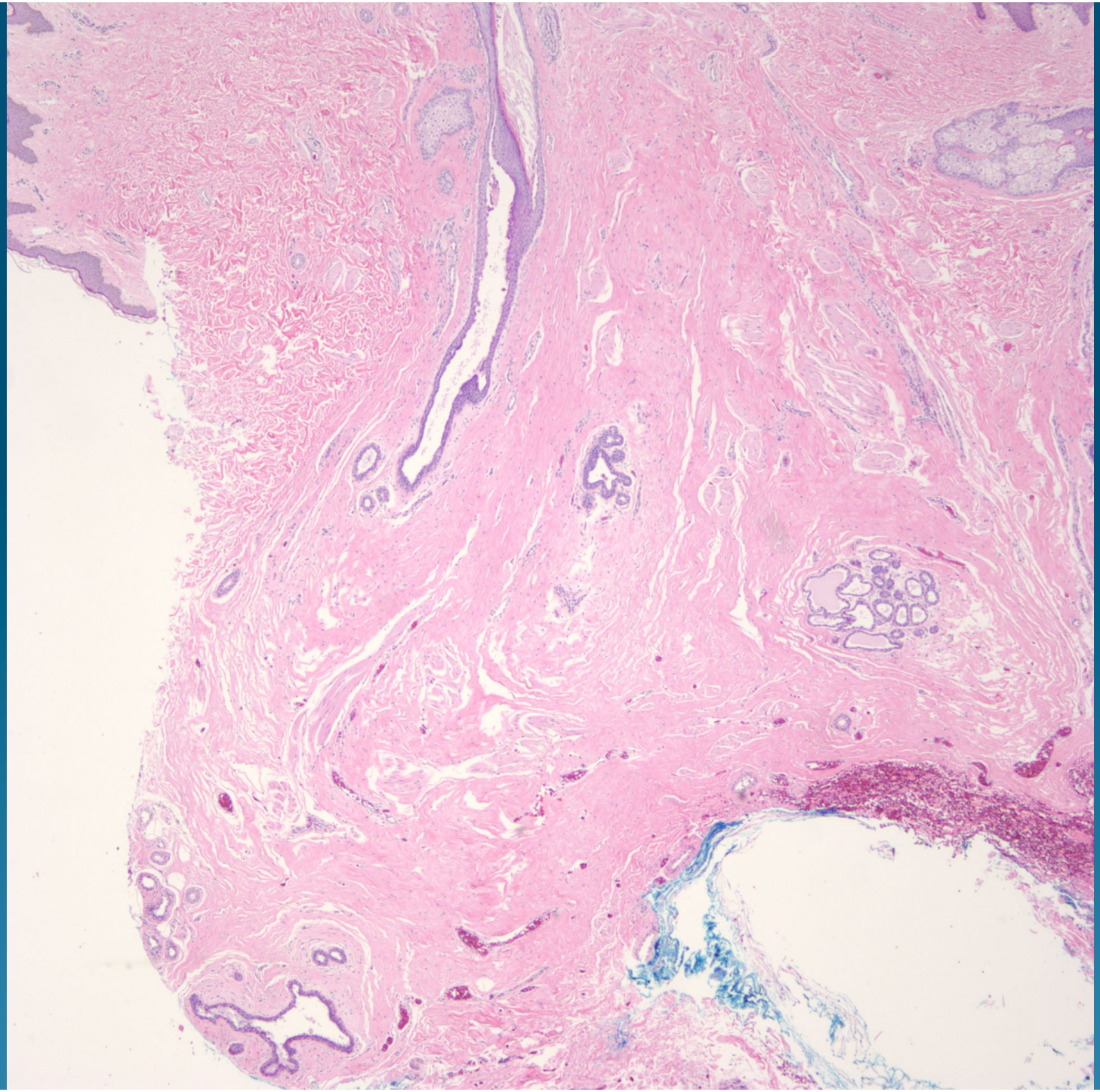

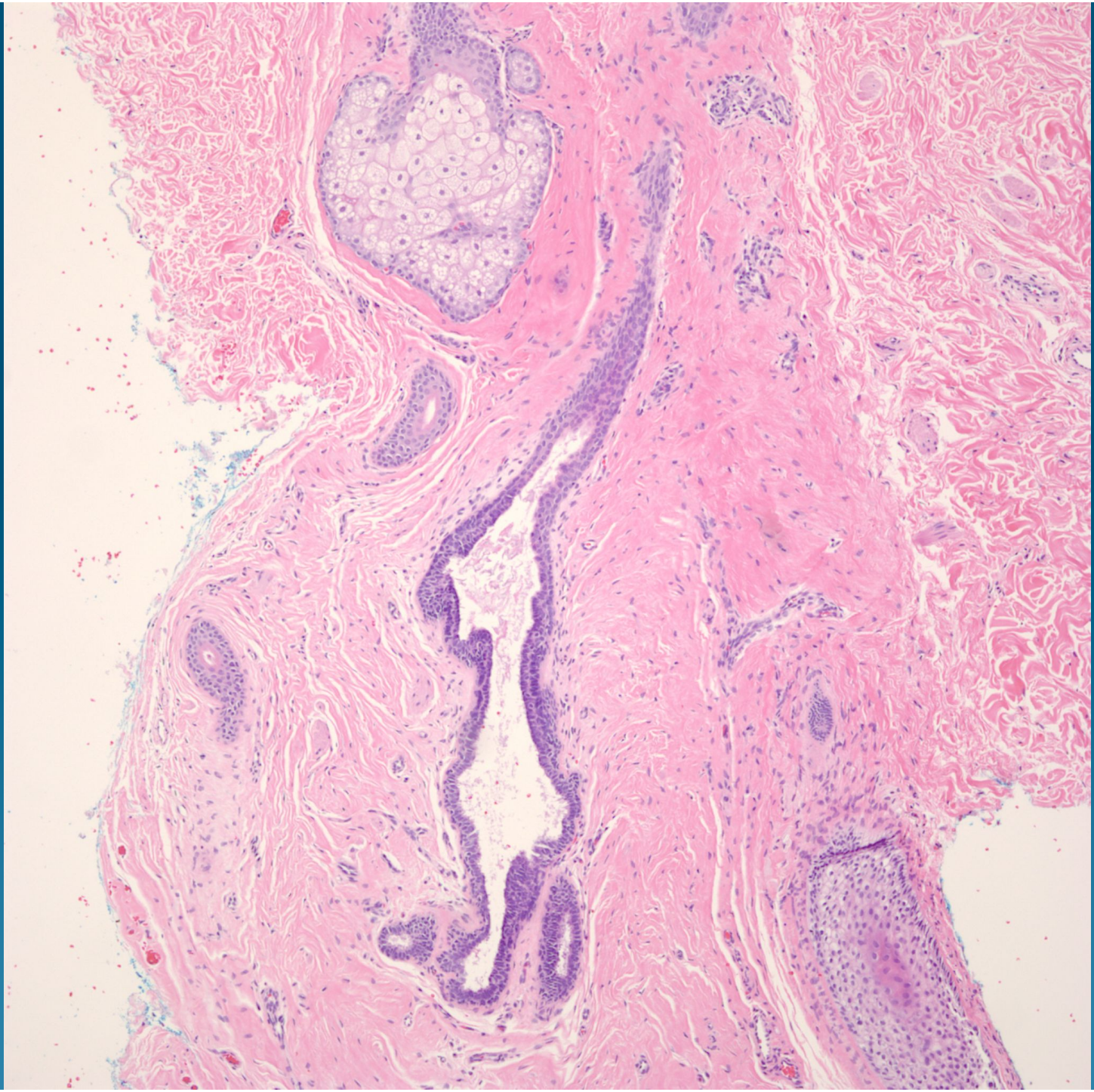

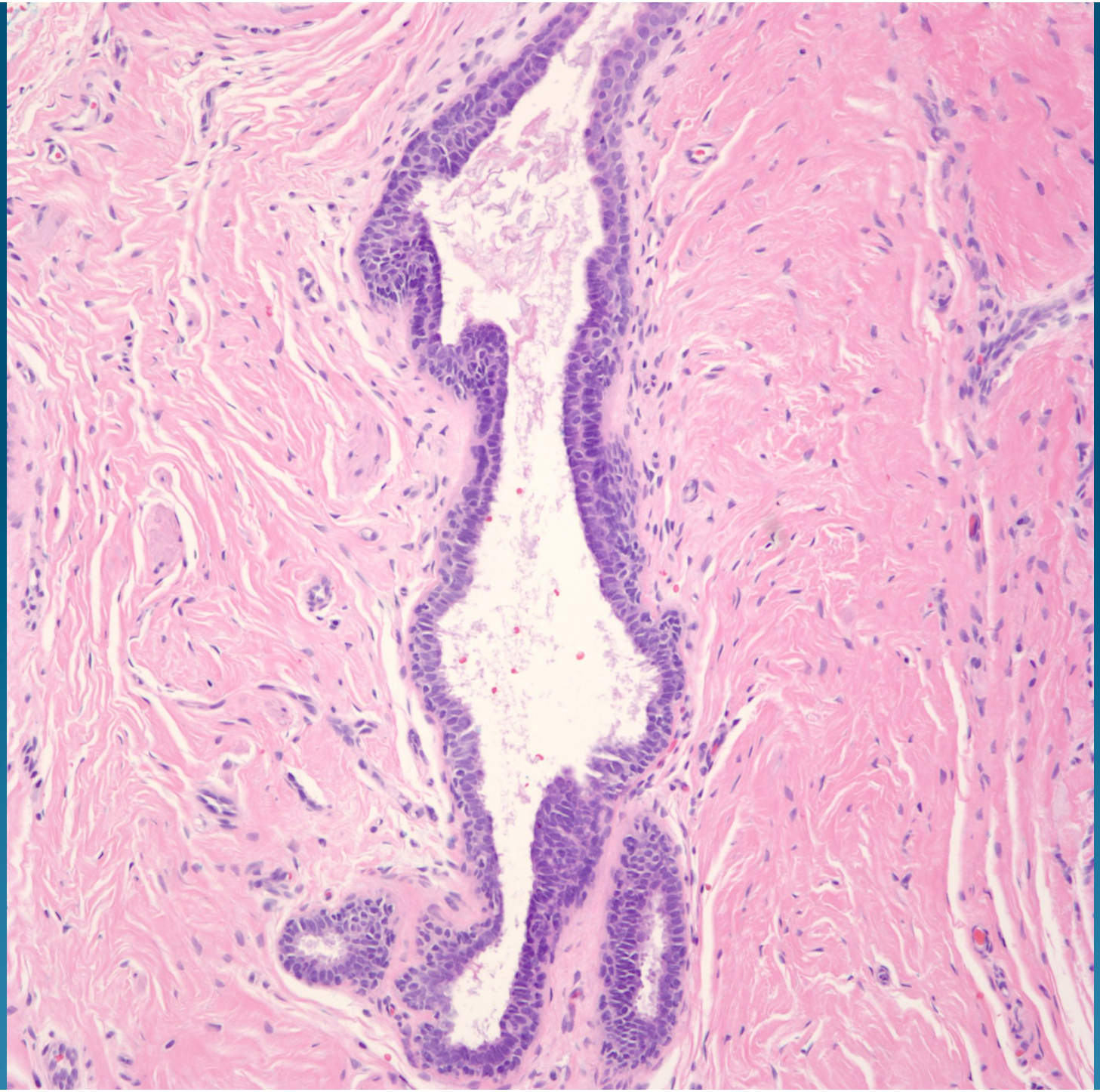

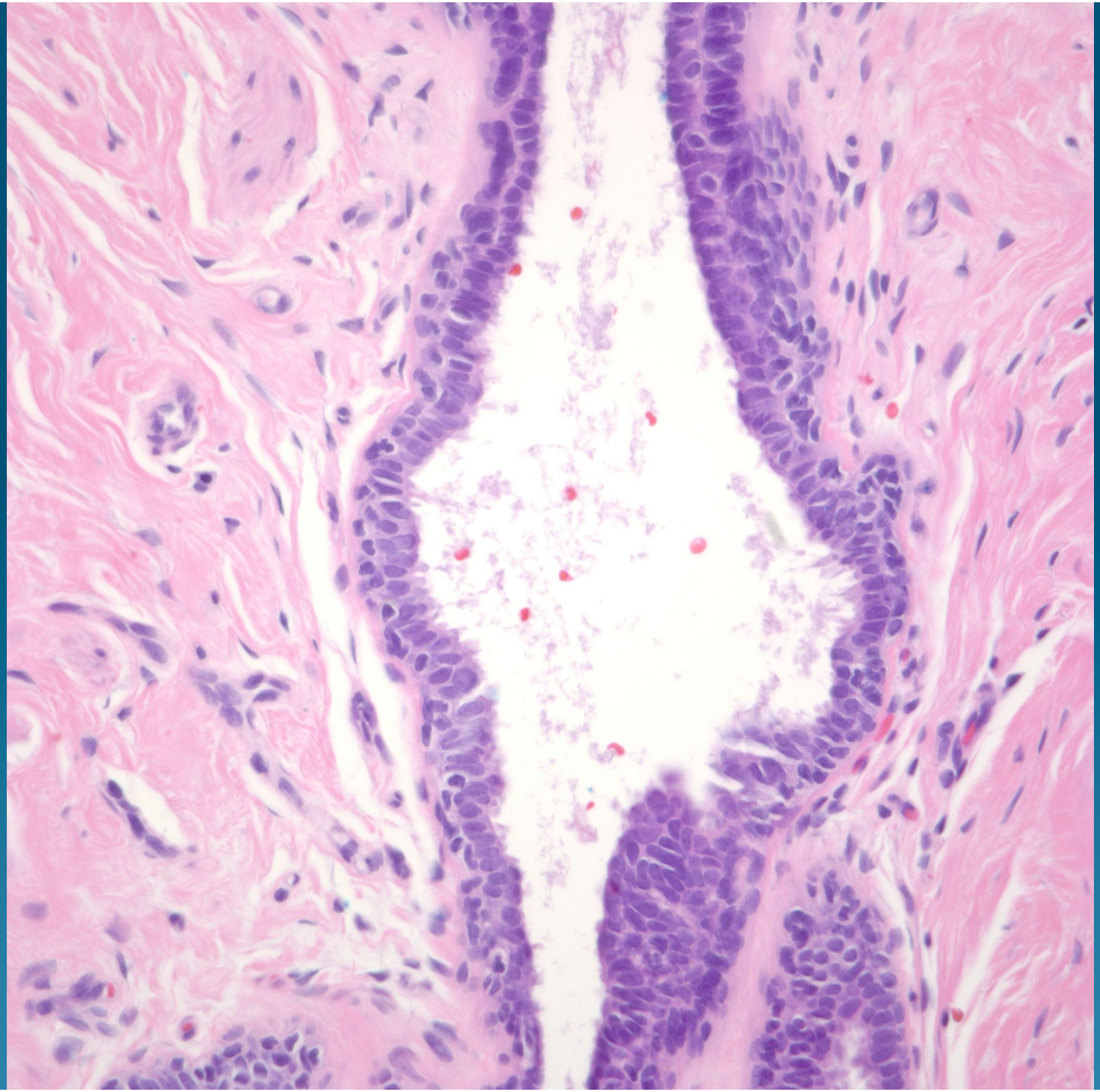

Accessory Nipple

Pearls

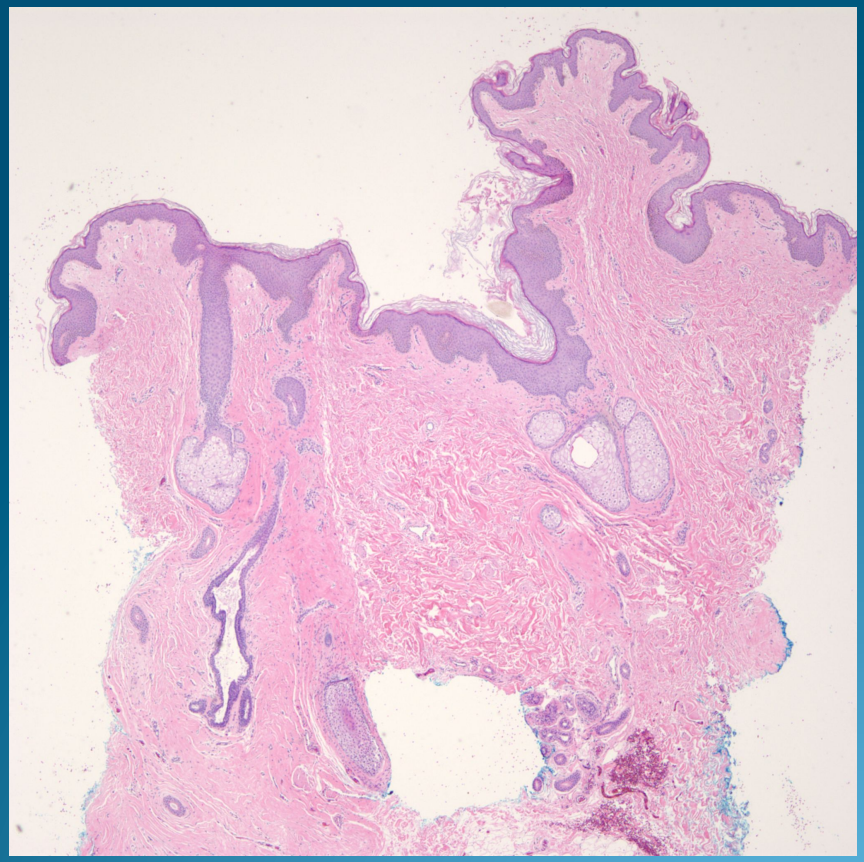

- Epidermal papillomatosis
- Dermis show scattered breast ducts lined by cytologically bland epithelium, may show apocrine changes
- Ducts may be in continuity with epidermis
- No cytologic atypia

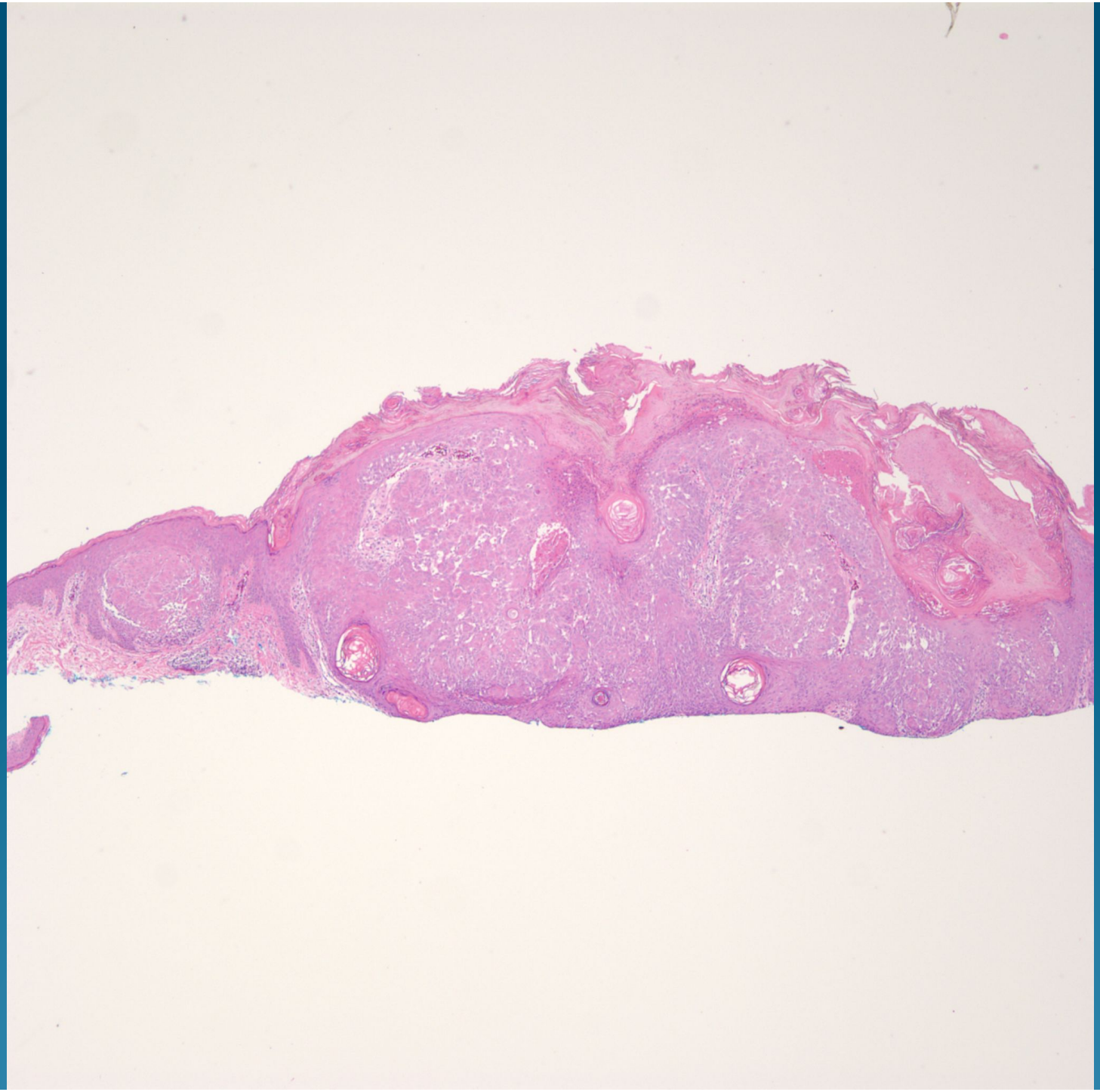

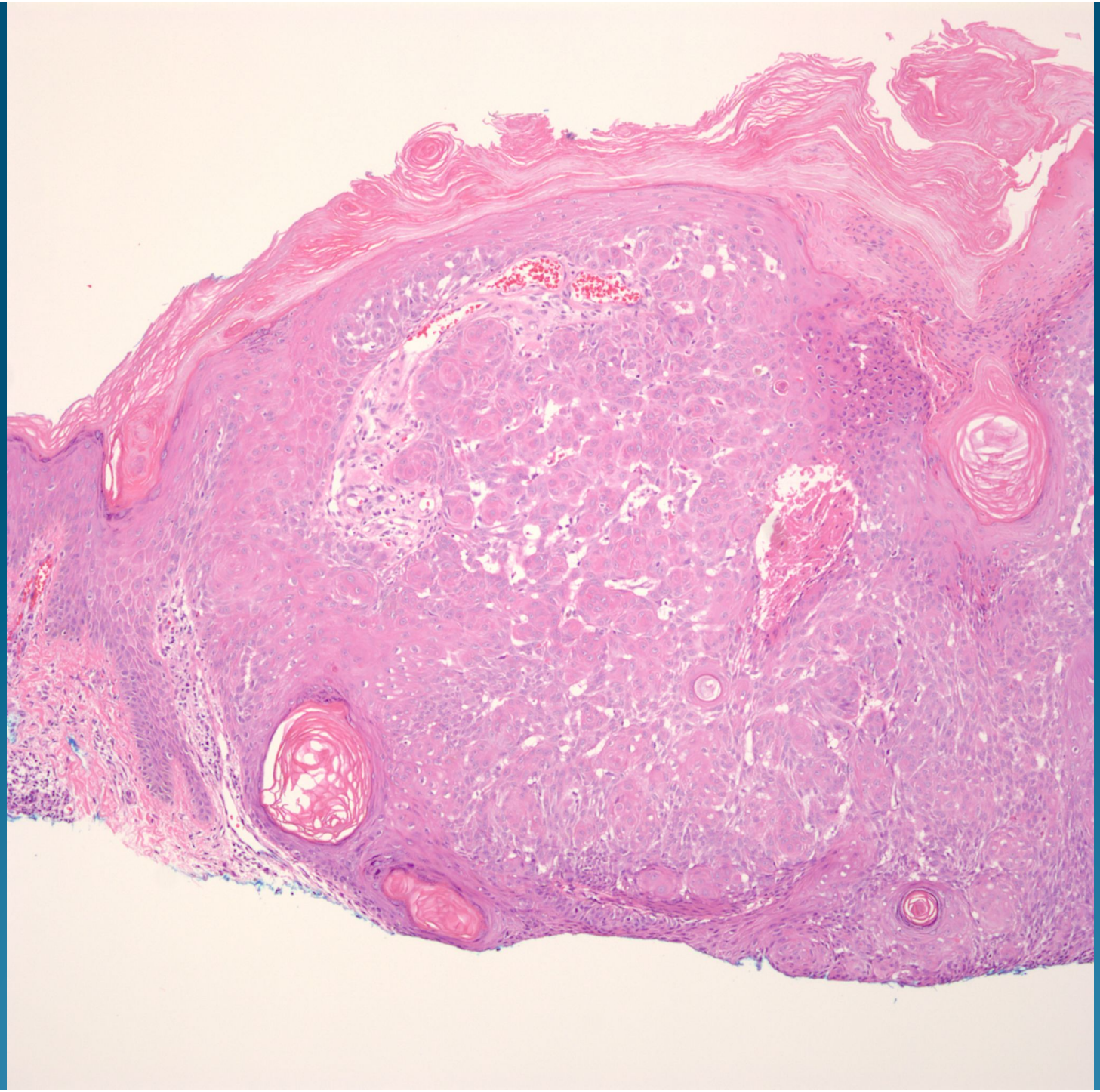

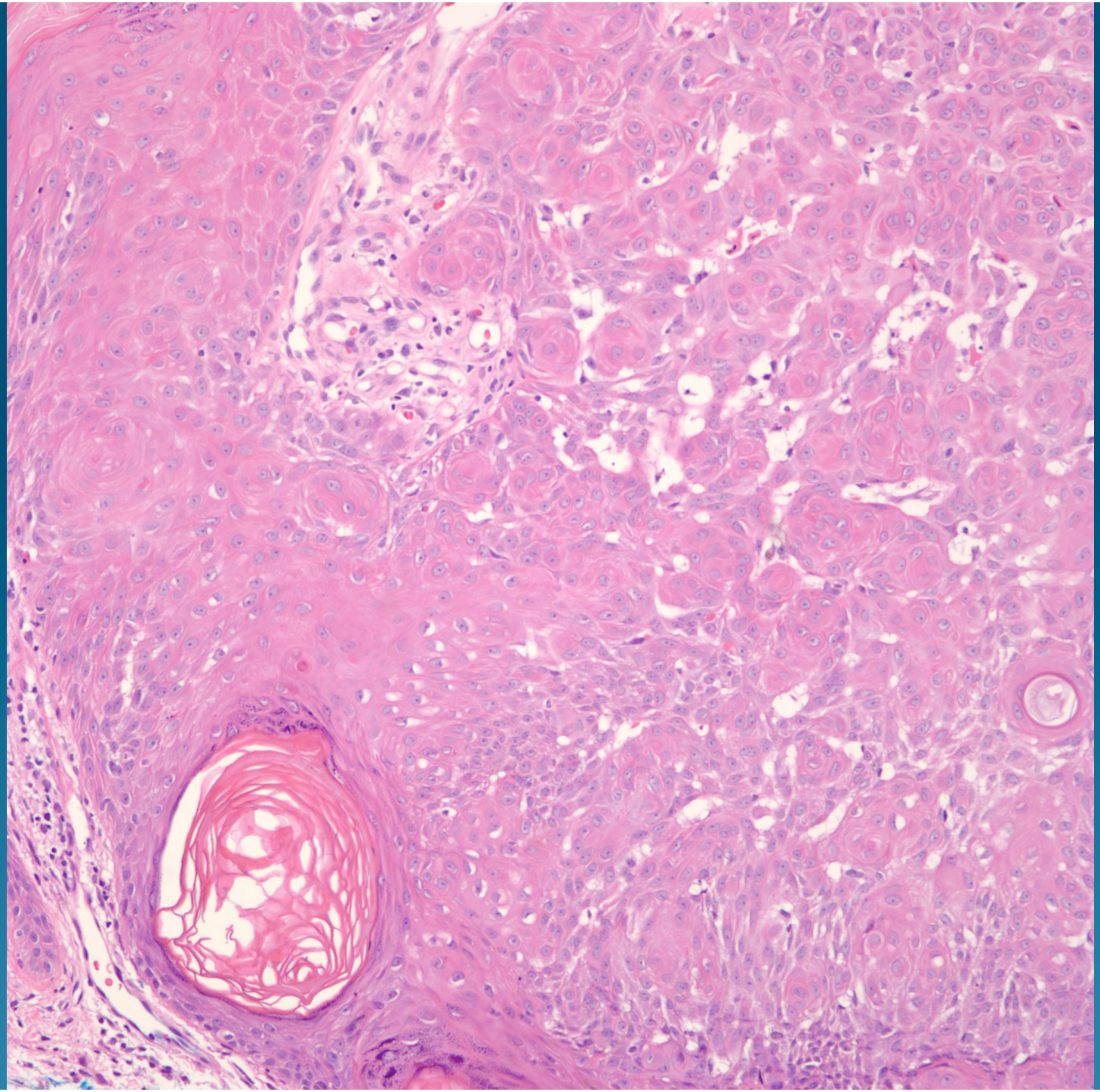

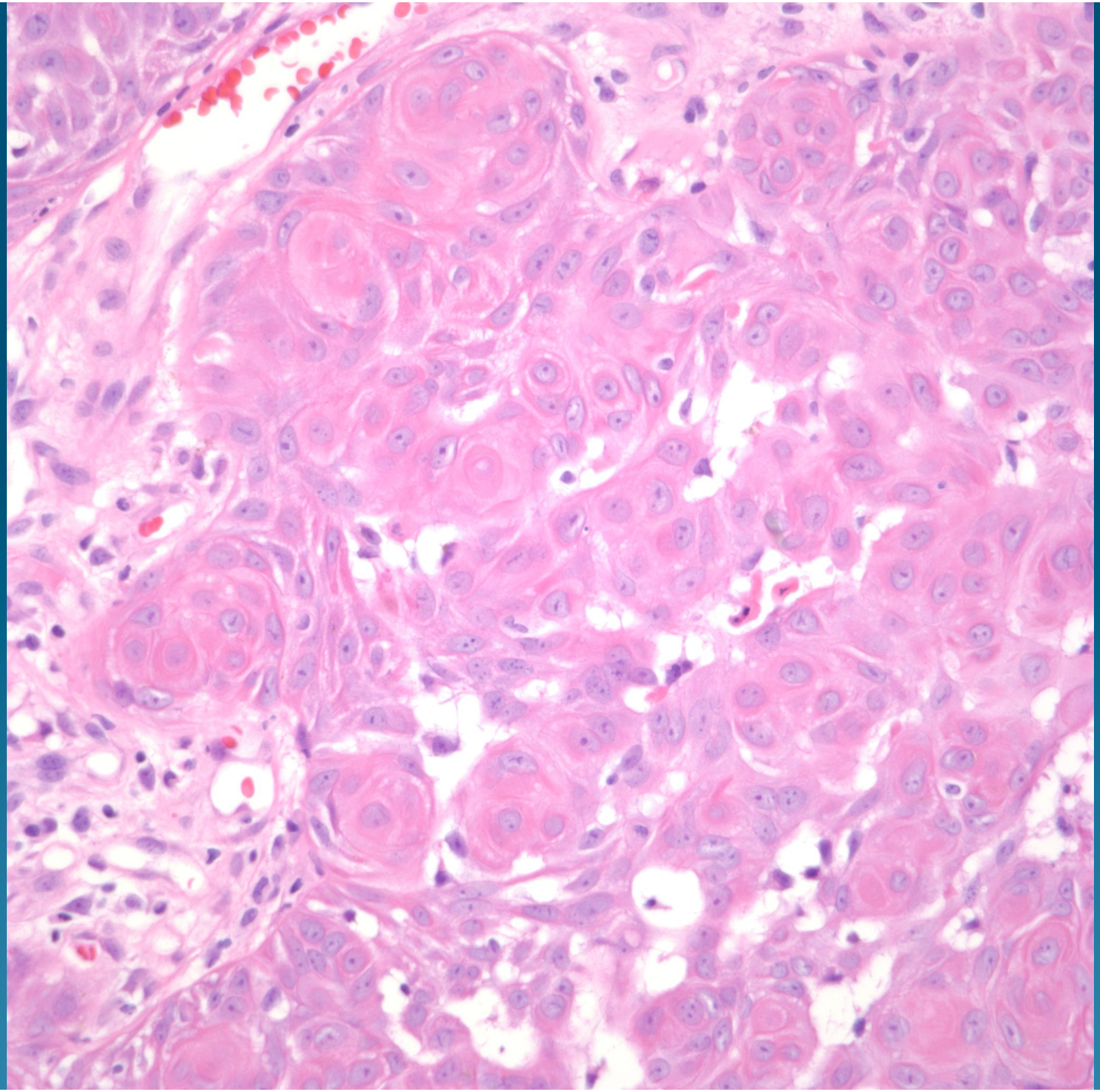

What is the best diagnosis?

A. Bowen's disease
B. Hidroacanthoma simplex
C. Irritated Seborrheic Keratosis
D. Eccrine Poroma
E. Trichilemmoma

Irritated Seborrheic Keratosis

Pearls

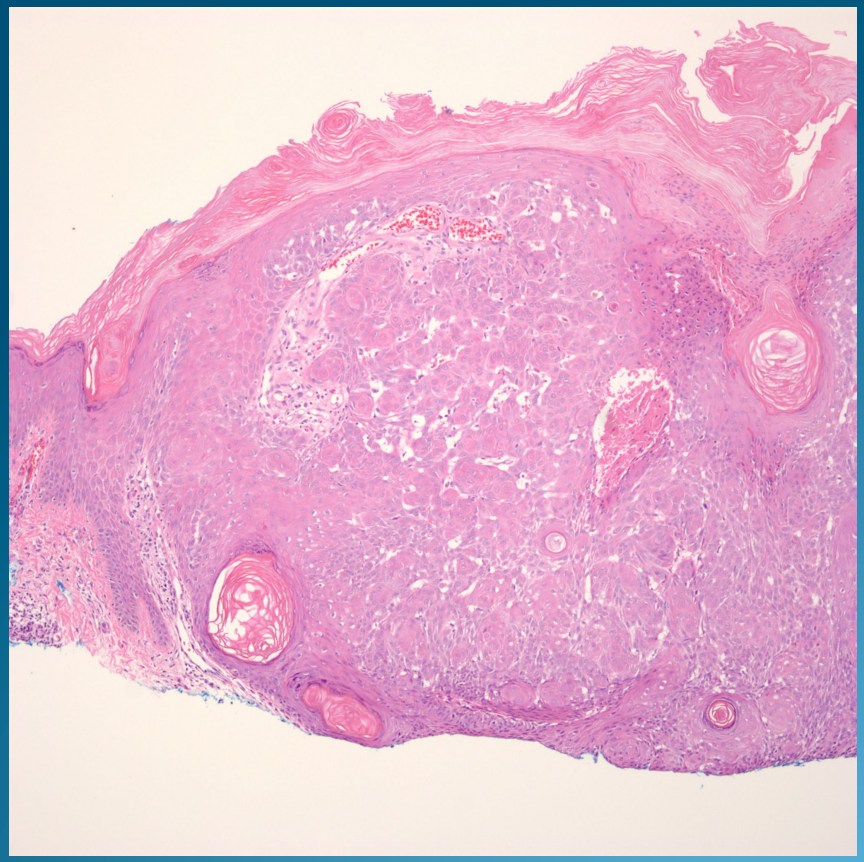

- Silhouette of typical seborrheic keratosis
- Numerous squamous eddies with bland cytologic features
- May have focal acantholytic features

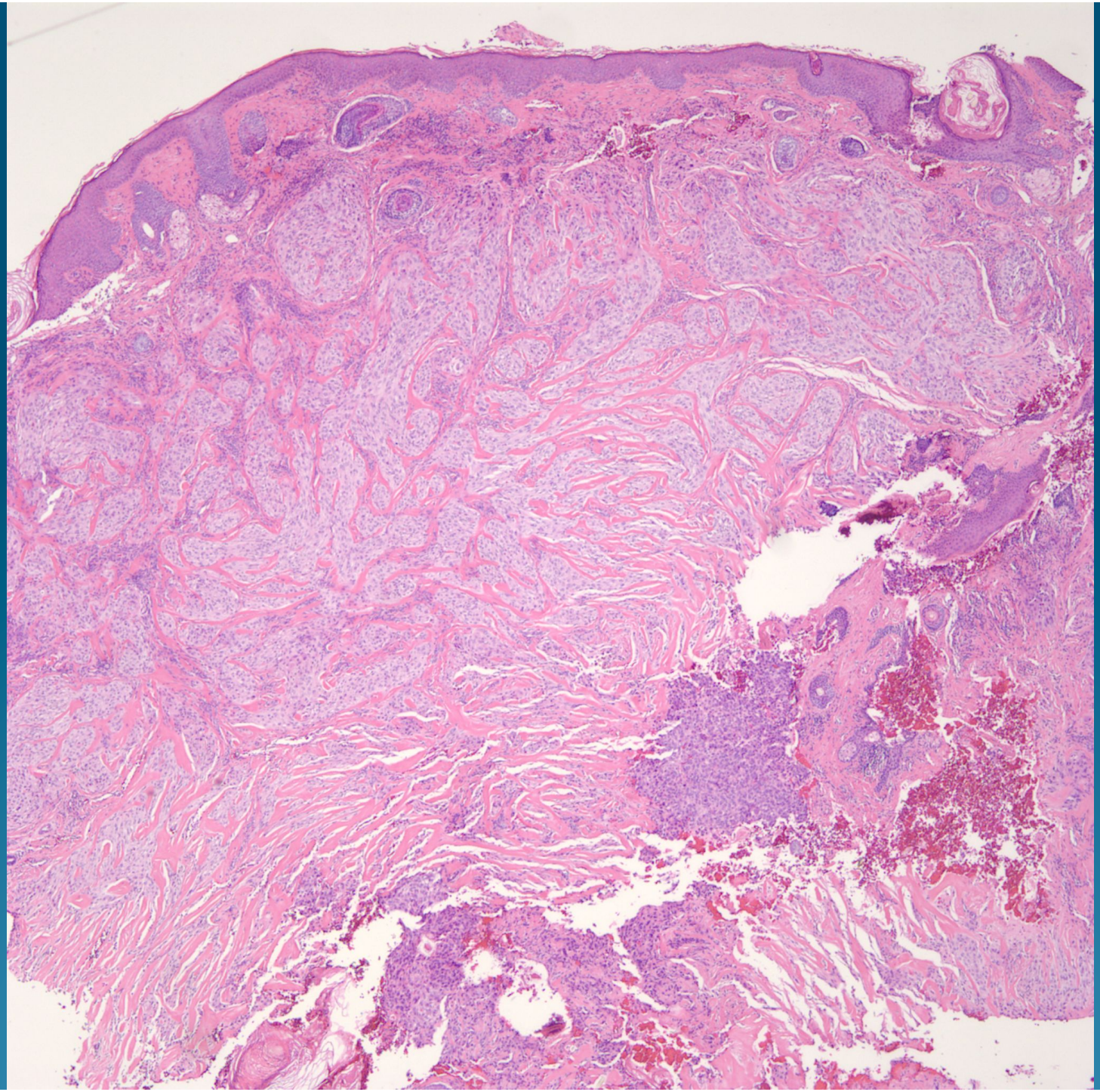

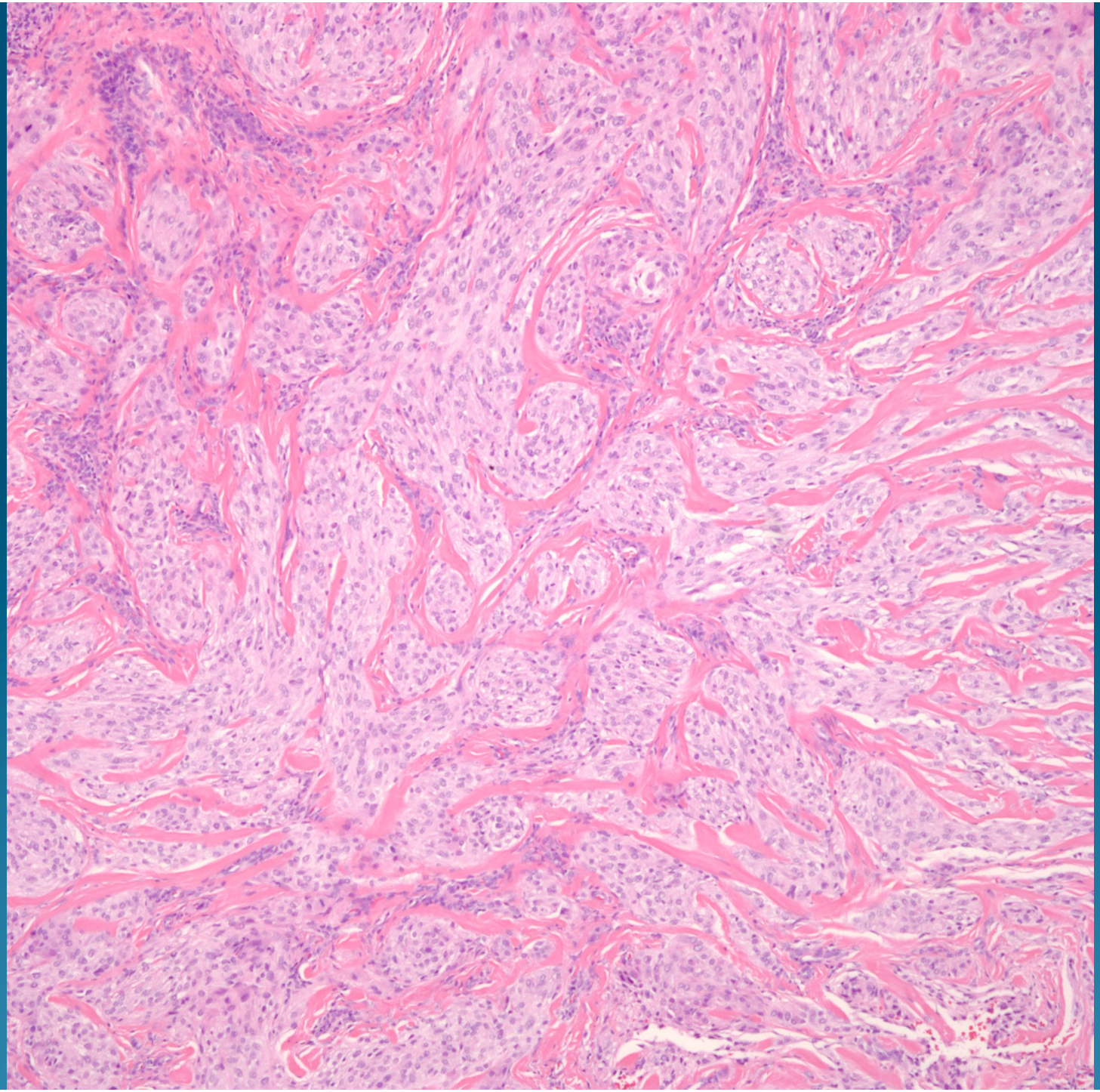

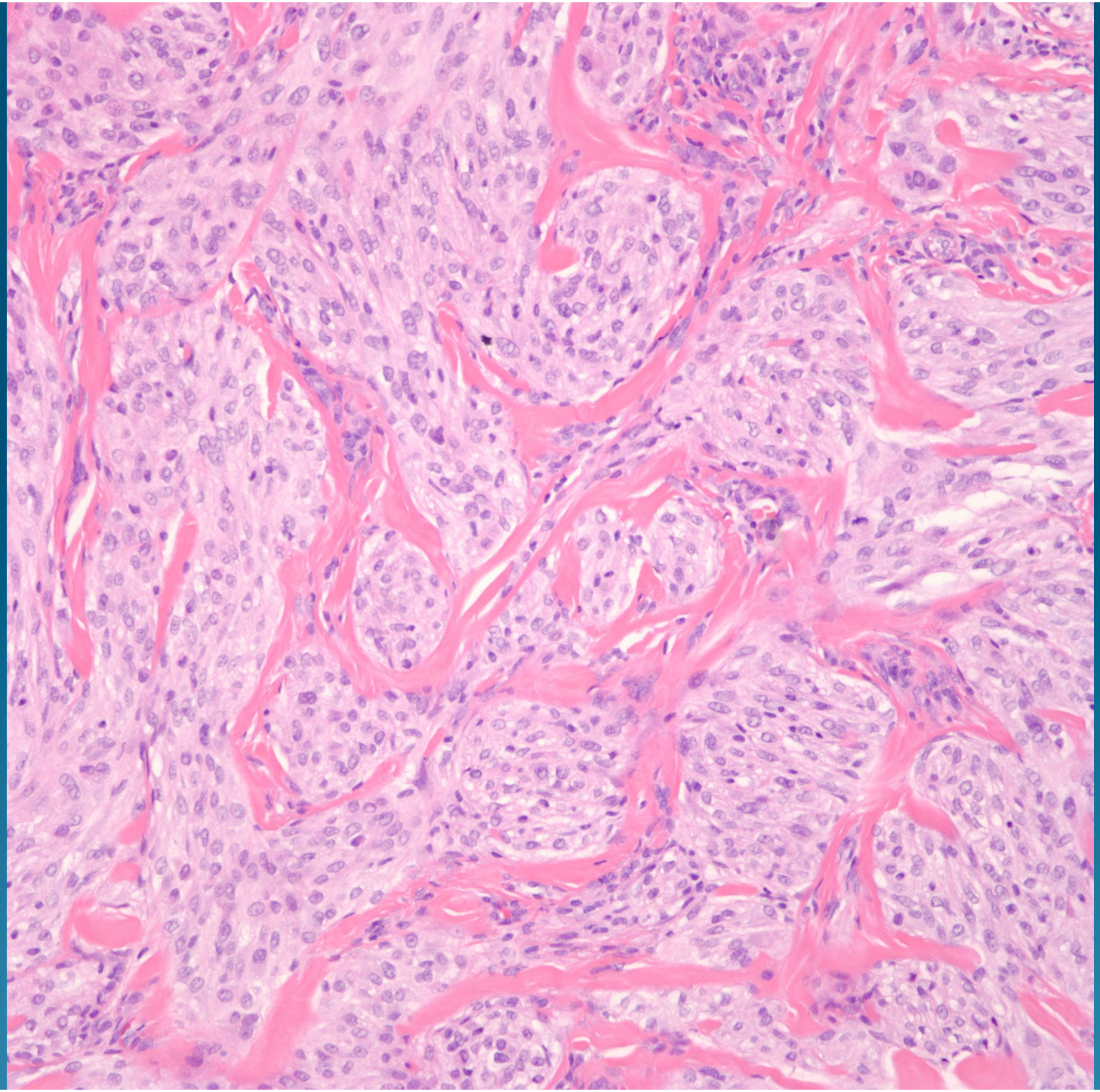

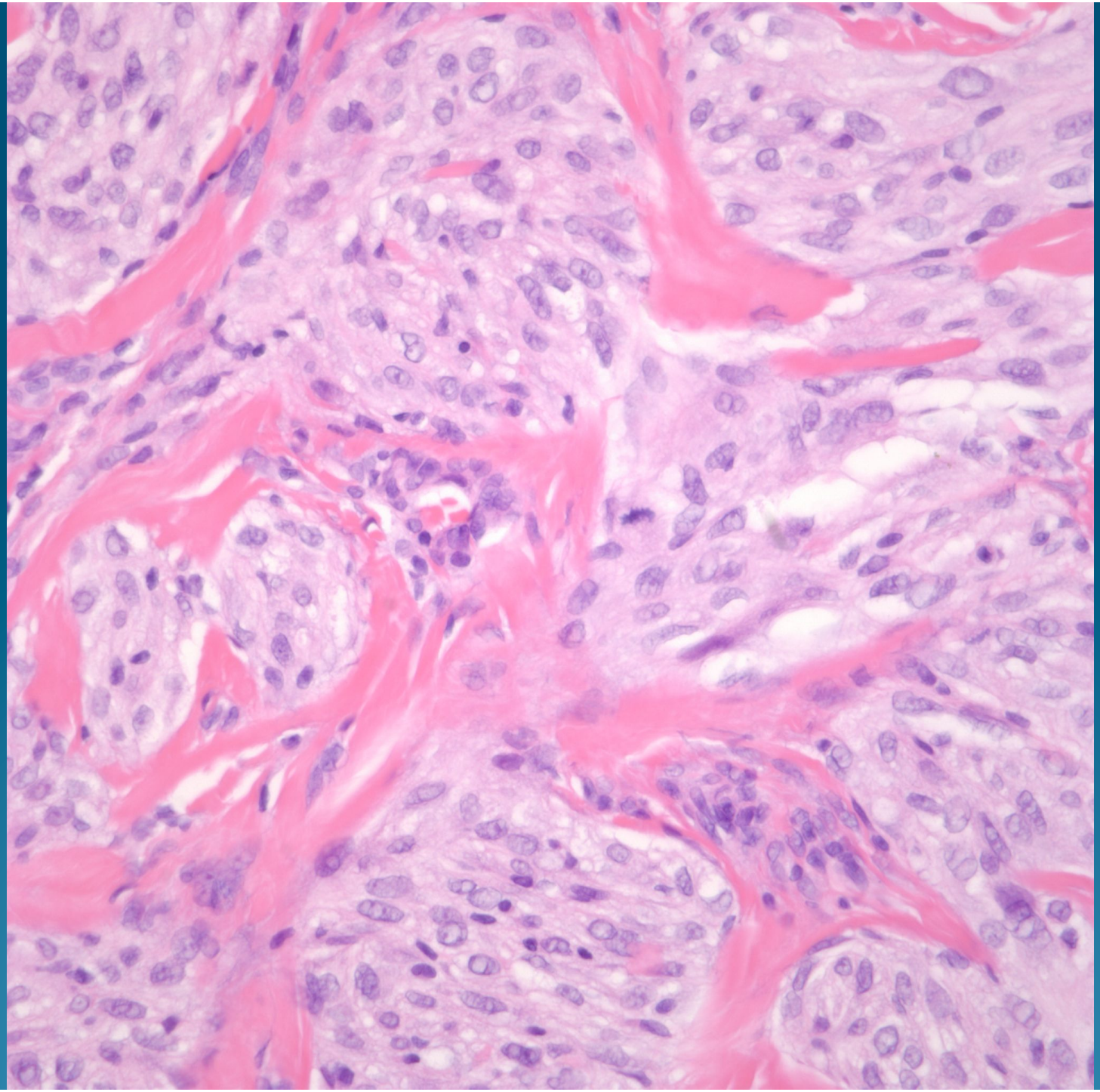

What is the best diagnosis?

A. Dermal Spitz Nevus
B. Palisaded and Encapsulated Neuroma
C. Desmoplastic Melanoma
D. Neurothekeoma
E. Neurilemmoma

Cellular Neurothekeoma

Immunohistochemistry:

Negative for S100, Smooth muscle actin, HMB-45, MART-1, CD34, Factor Xiiia, Cytokeratin, EMA

Pearls

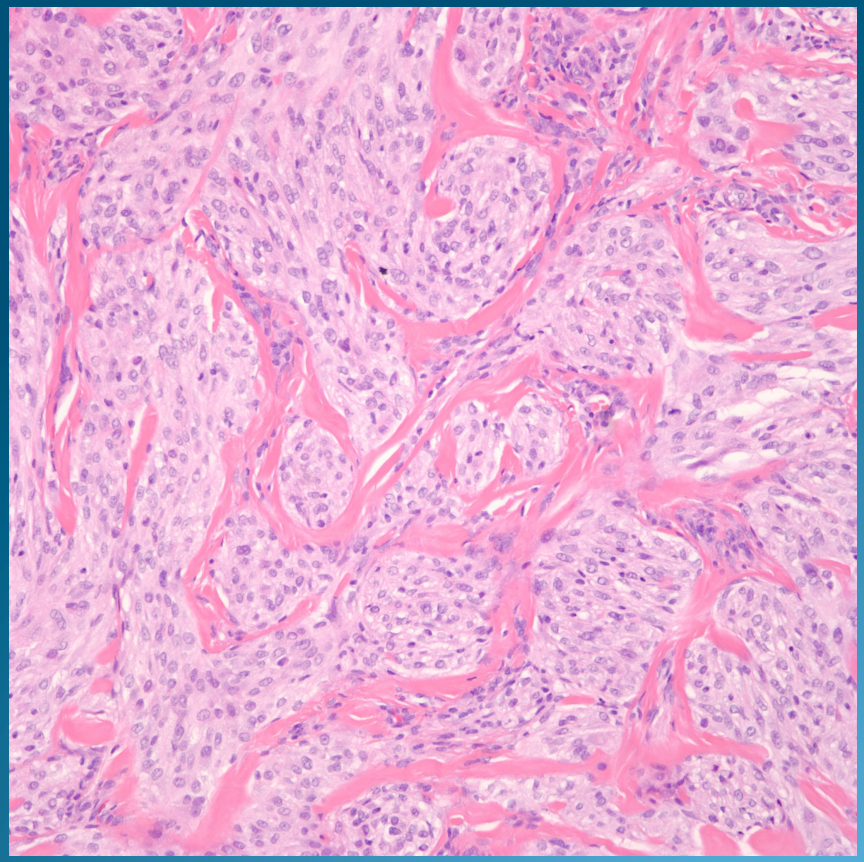

- Dermal theques of spindled and epithelioid cells
- Dermal fibroplasia with minimal mucin
- May show focal cytologic atypia and increased mitotic figures
- Immunohistochemistry to rule out melanocytic proliferation, PEComa, and neural tumor

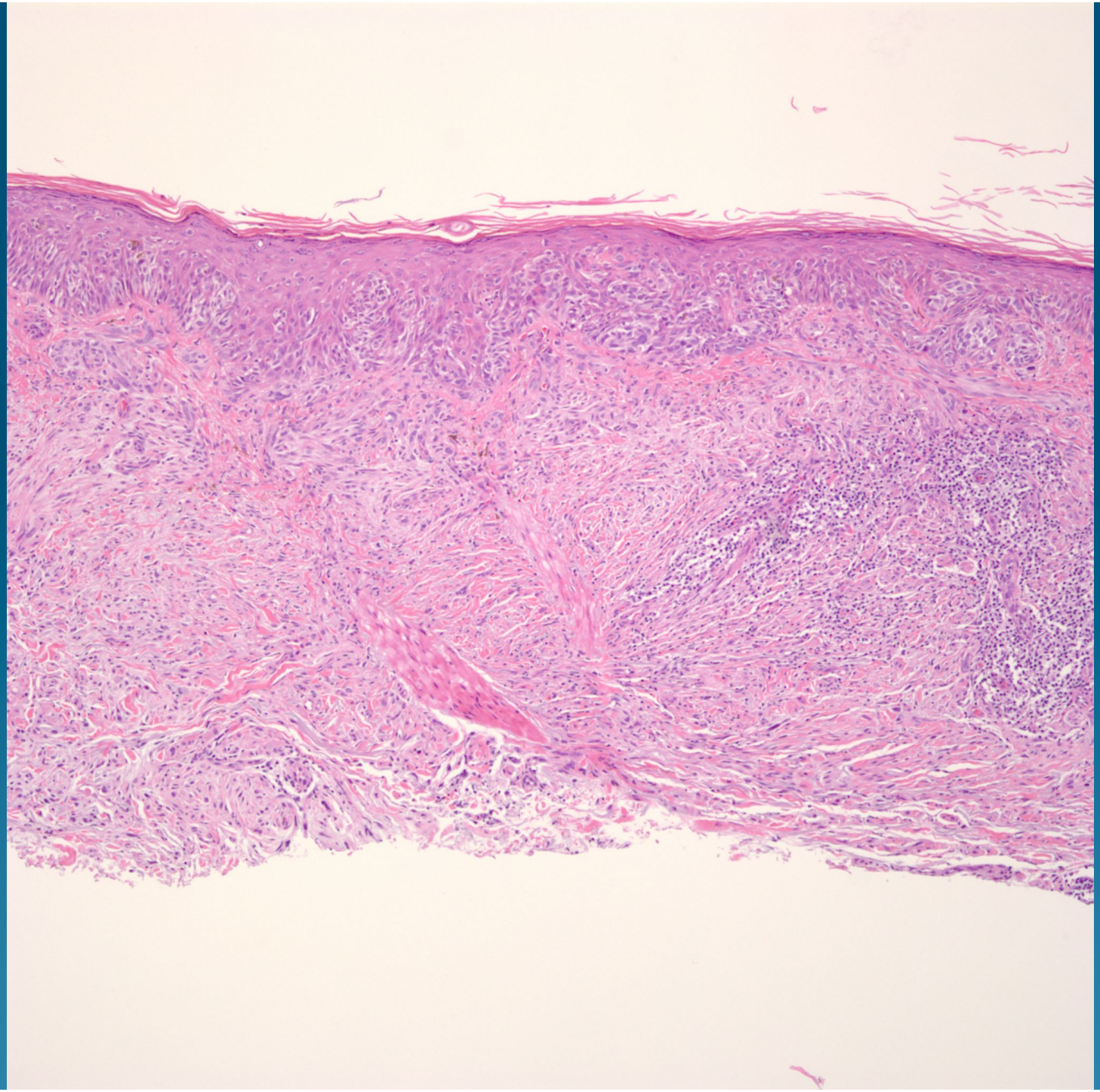

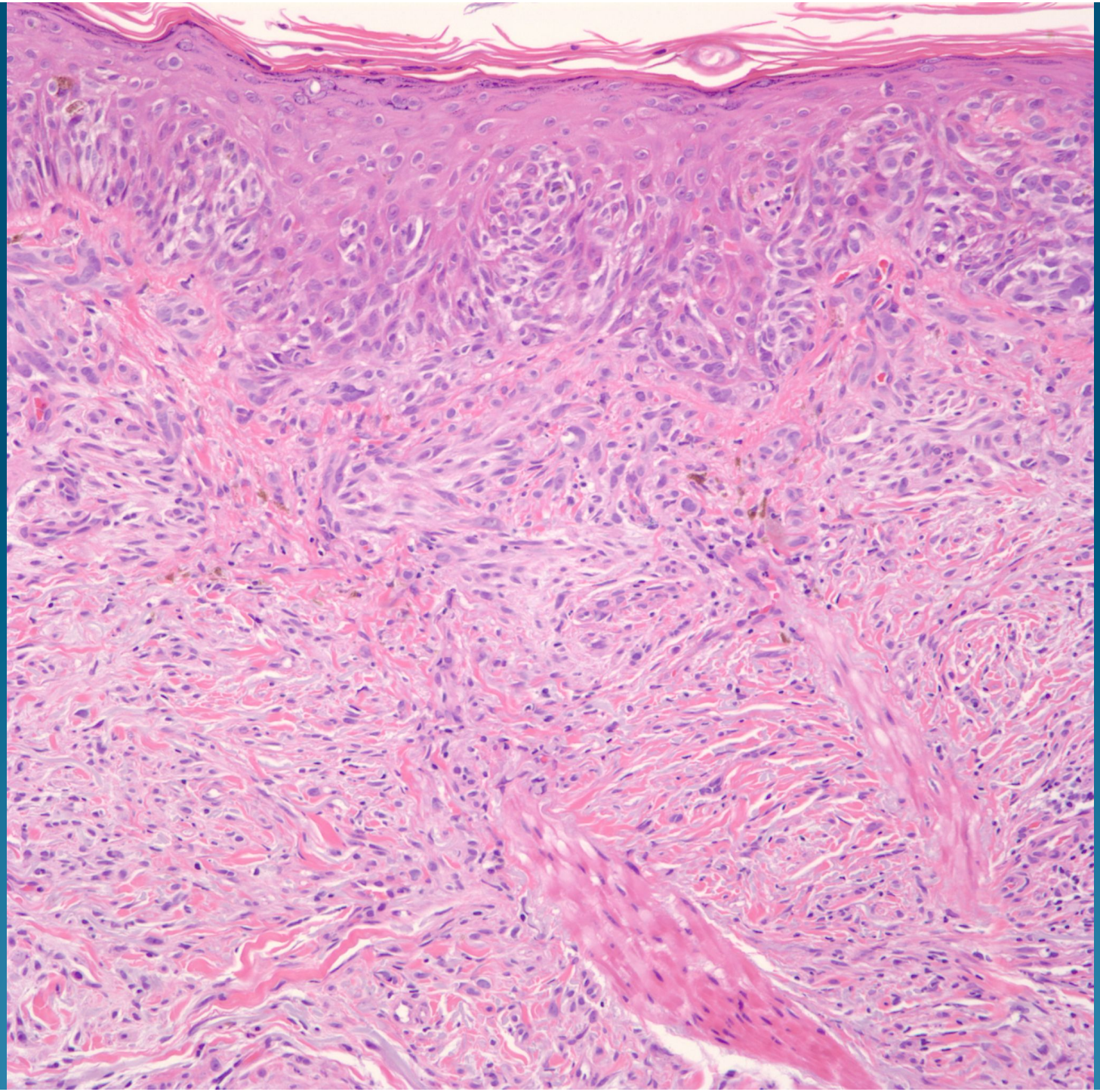

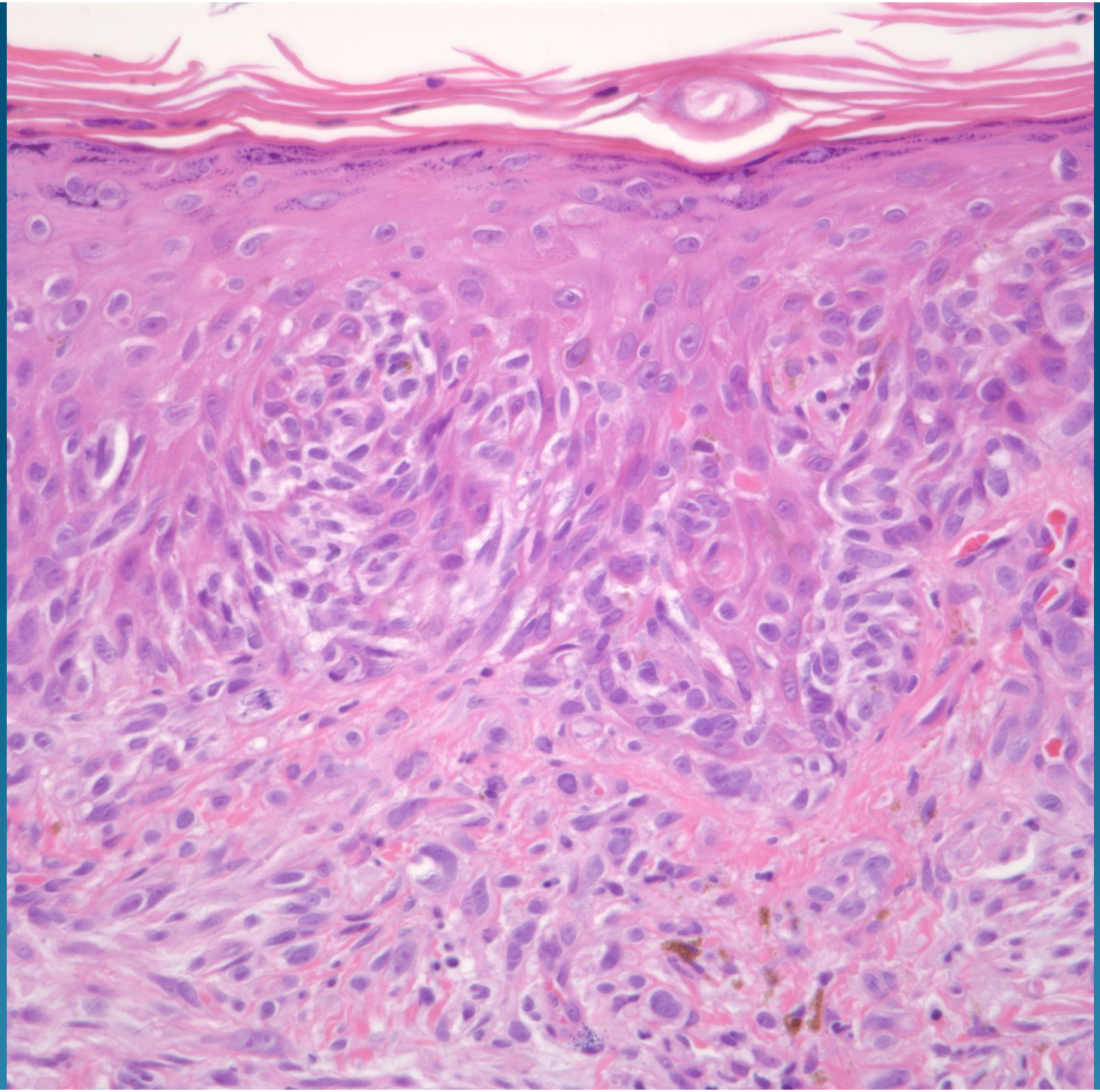

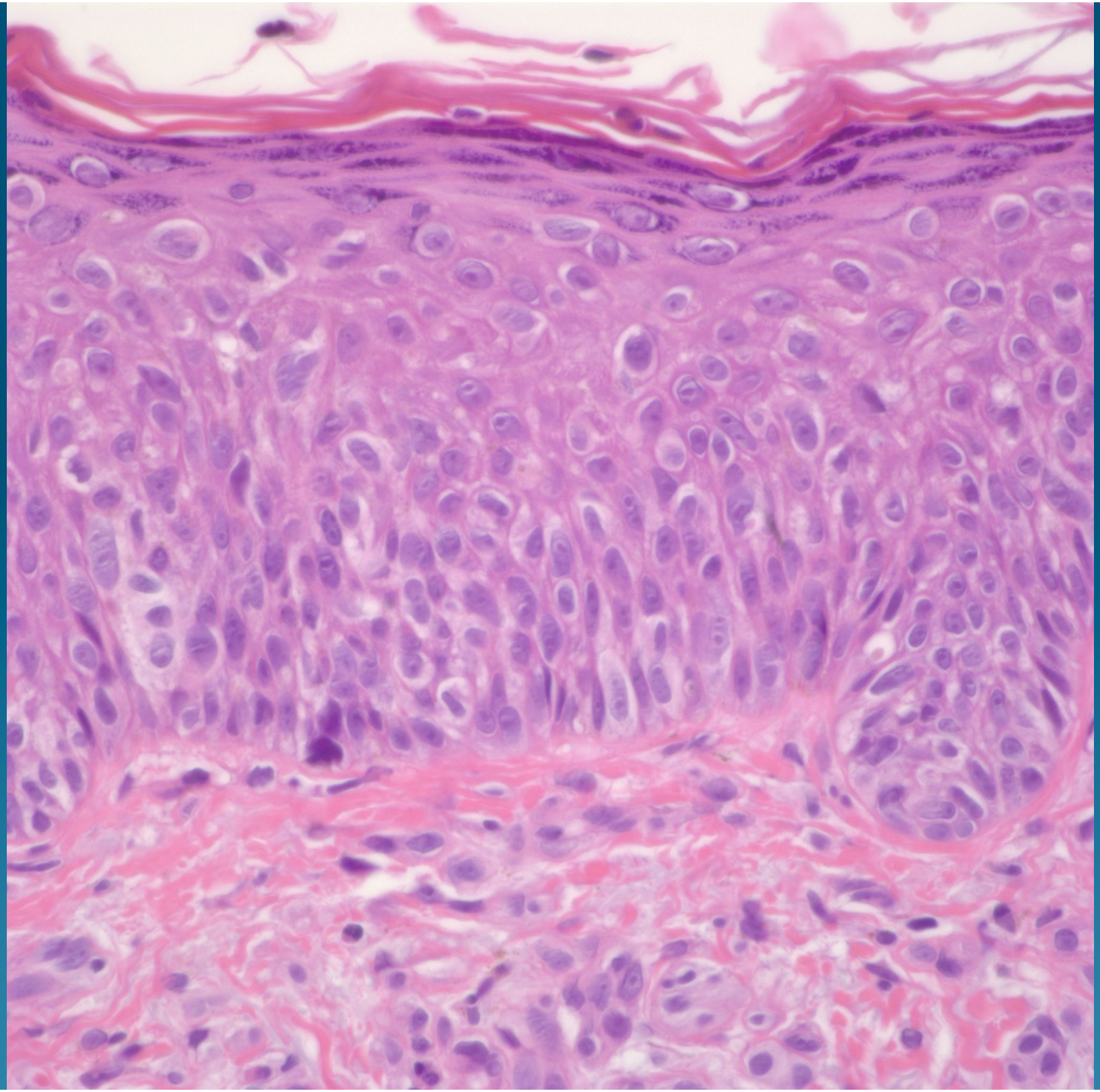

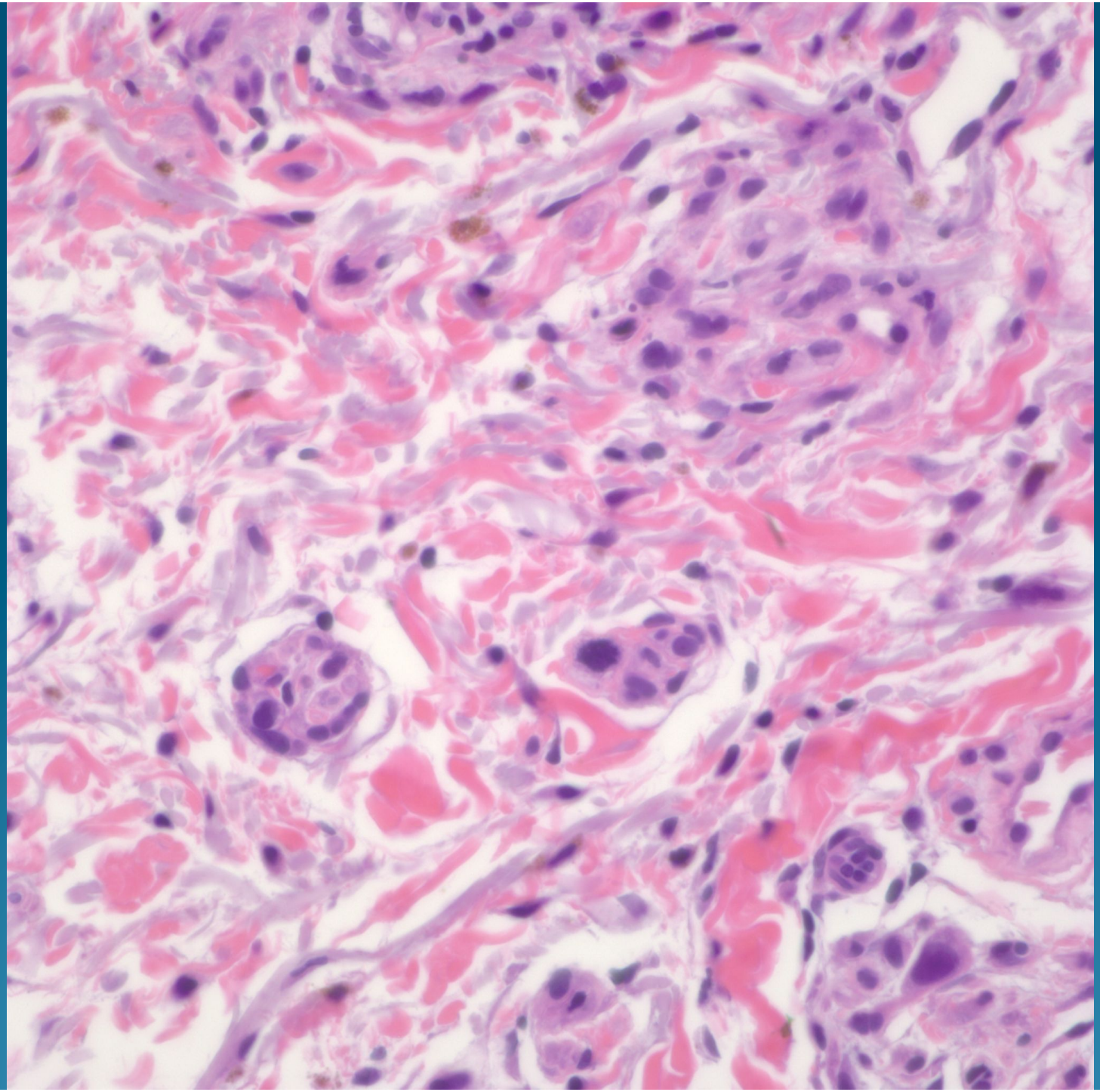

What is the best diagnosis?

A. Cellular Neurothekeoma
B. Desmoplastic Spitz Nevus
C. Desmoplastic Melanoma
D. Morpheaform Basal Cell Carcinoma
E. Atypical Fibroxanthoma

Desmoplastic Malignant Melanoma

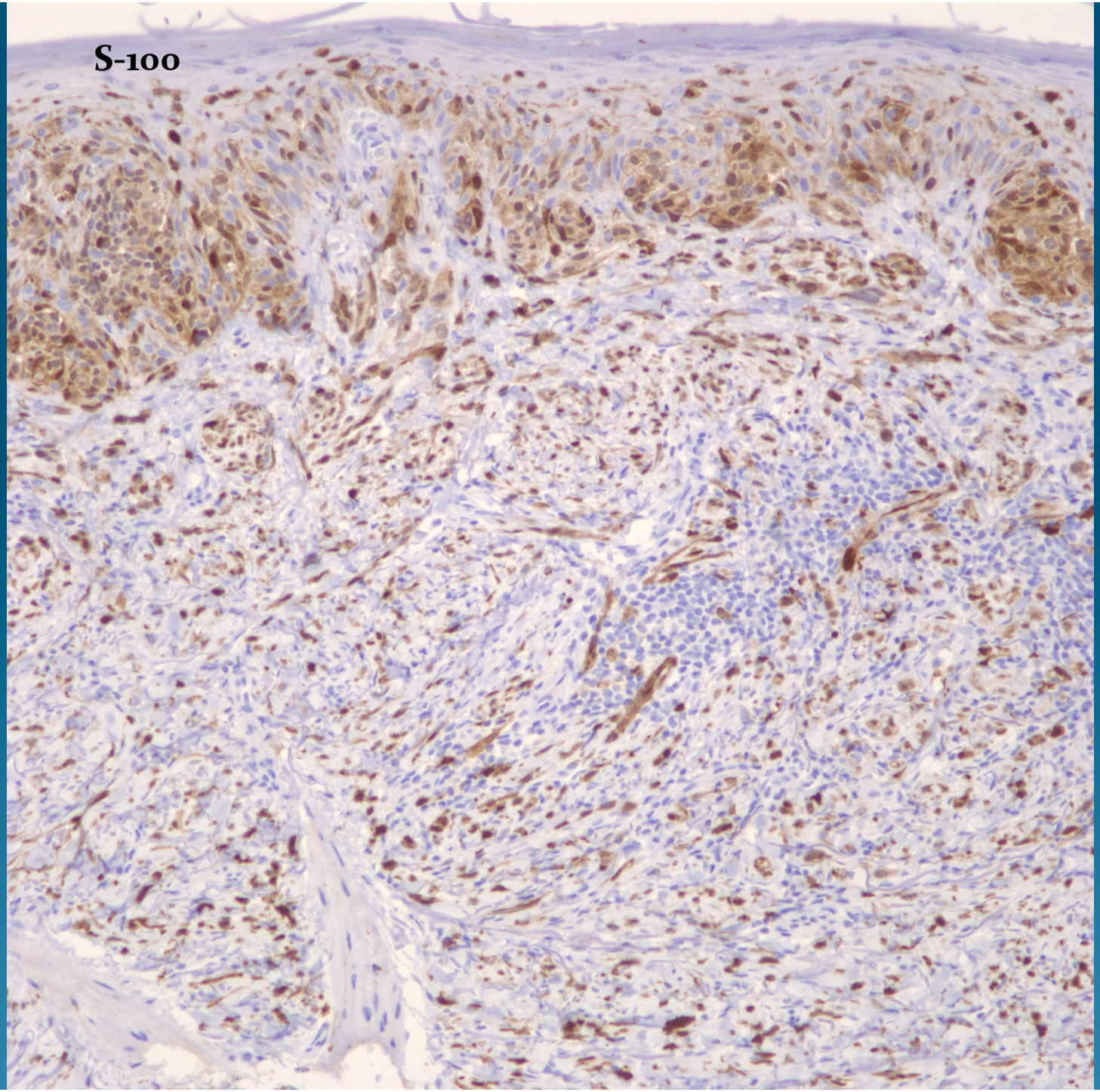
S-100

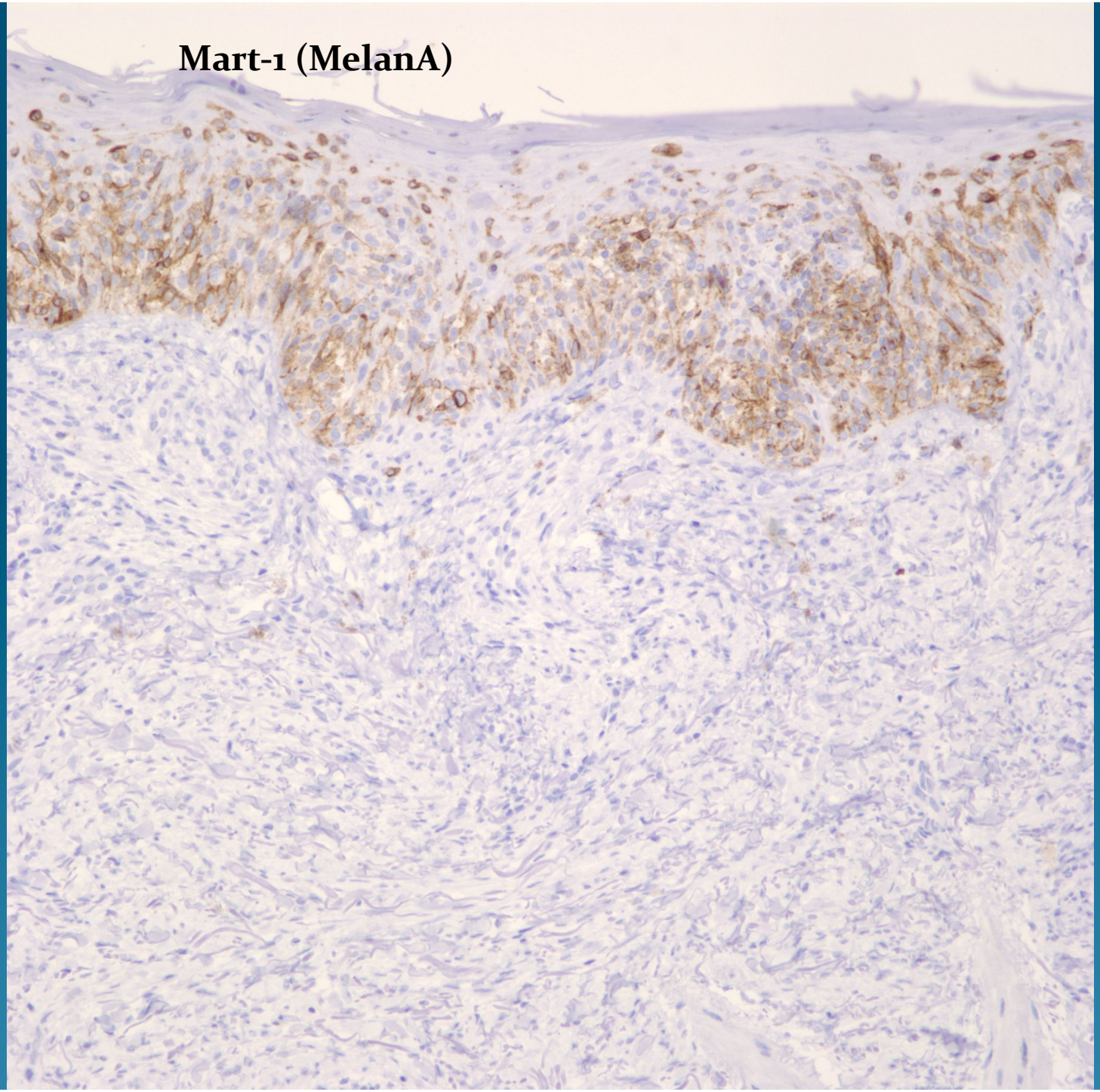
Mart-1 (MelanA)

Pearls

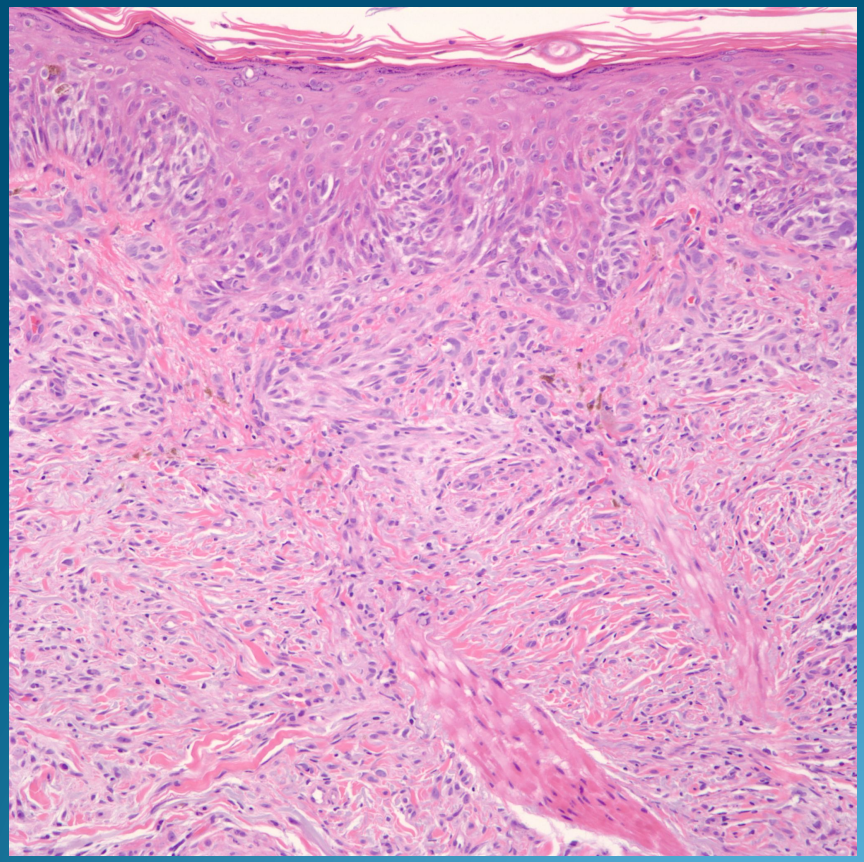

- Cytologically atypical spindle cells in dermis with solar elastosis
- Usually amelanotic
- Patchy chronic inflammatory cell infiltrate
- DE junction may contain proliferation of atypical melanocytes
- S100 + but typically negative for melanoma specific markers (HMB-45 and Mart-1)